Electrocardiography

Saeed Oraii MD, Cardiologist

Interventional Electrophysiologist

Tehran Arrhythmia Clinic

ECG

A graphic recording of electrical potentials generated by the heart

A noninvasive, inexpensive and highly versatile test

Normal Pathway of Electrical Conduction

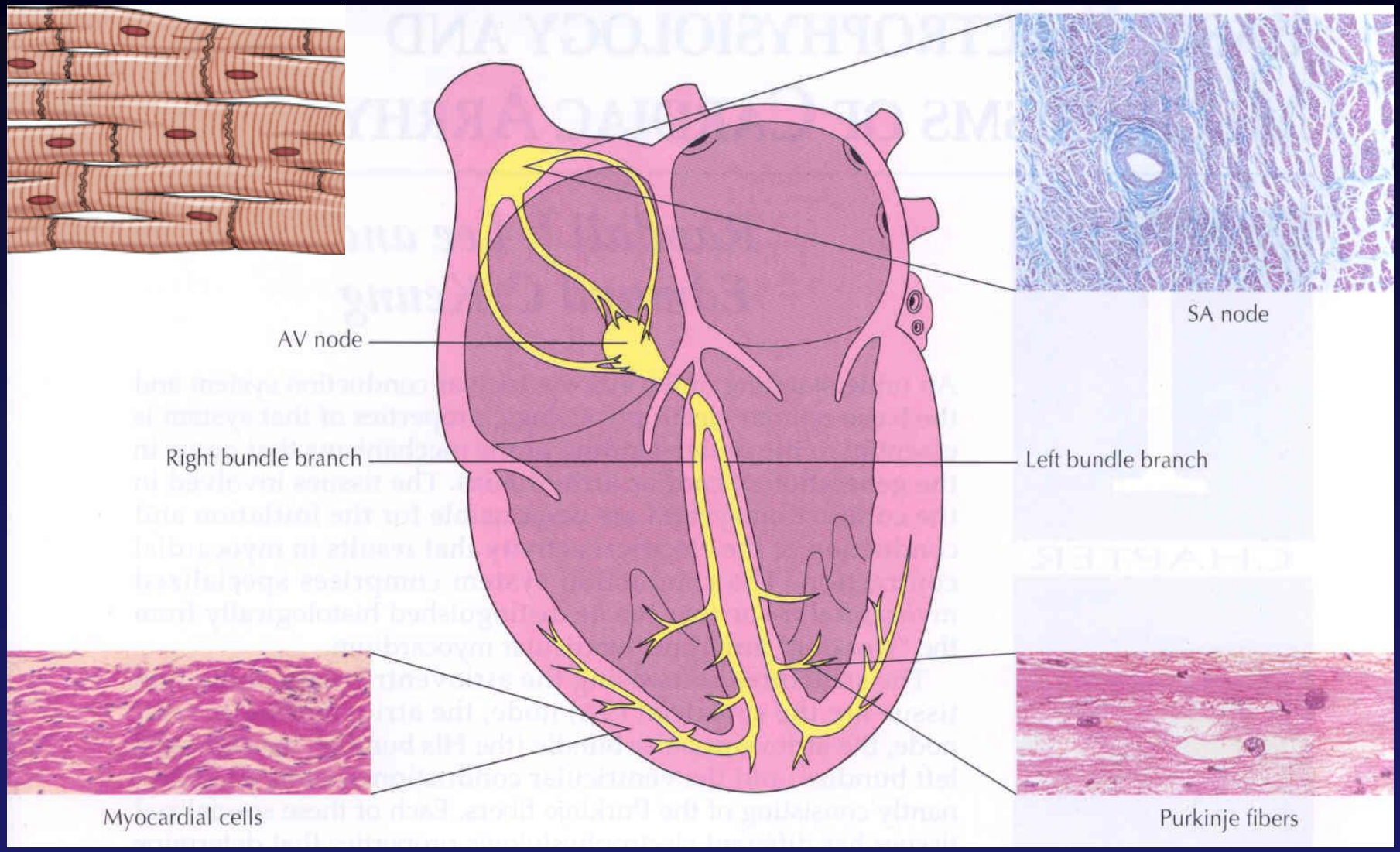

Tehran Arrhythmia Center

Normal Impulse Conduction

Sinoatrial node

↓

AV node

↓

Bundle of His

↓

Bundle Branches

↓

Purkinje fibers

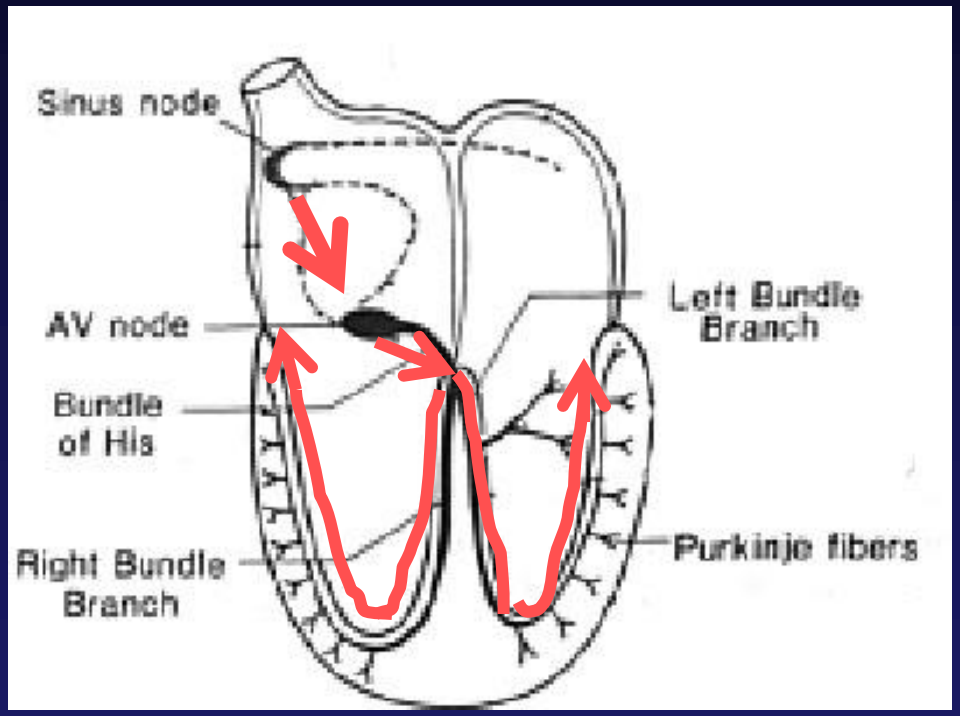

Cardiac Action Potential

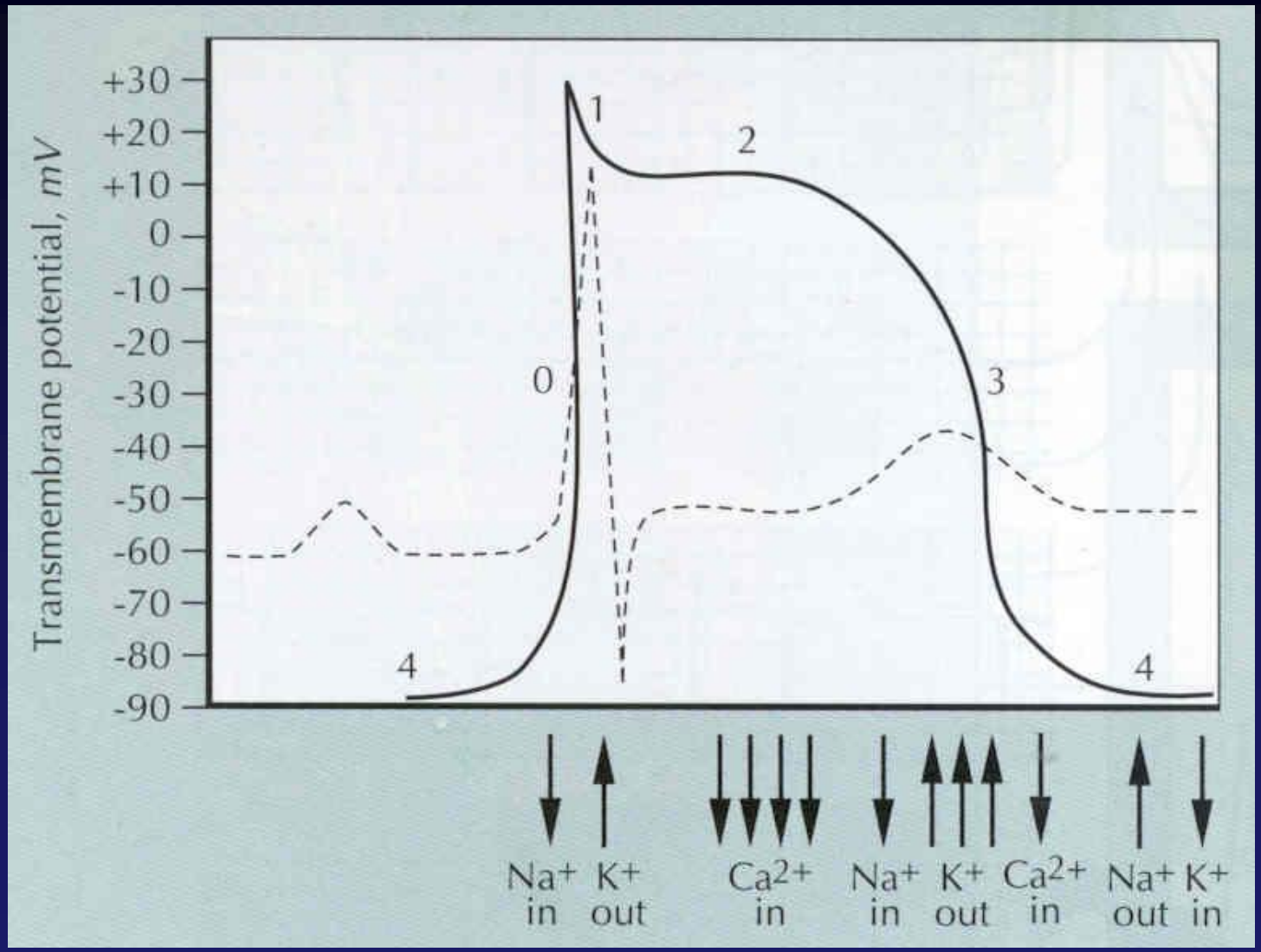

Tehran Arrhythmia Center

Cardiac Action Potential

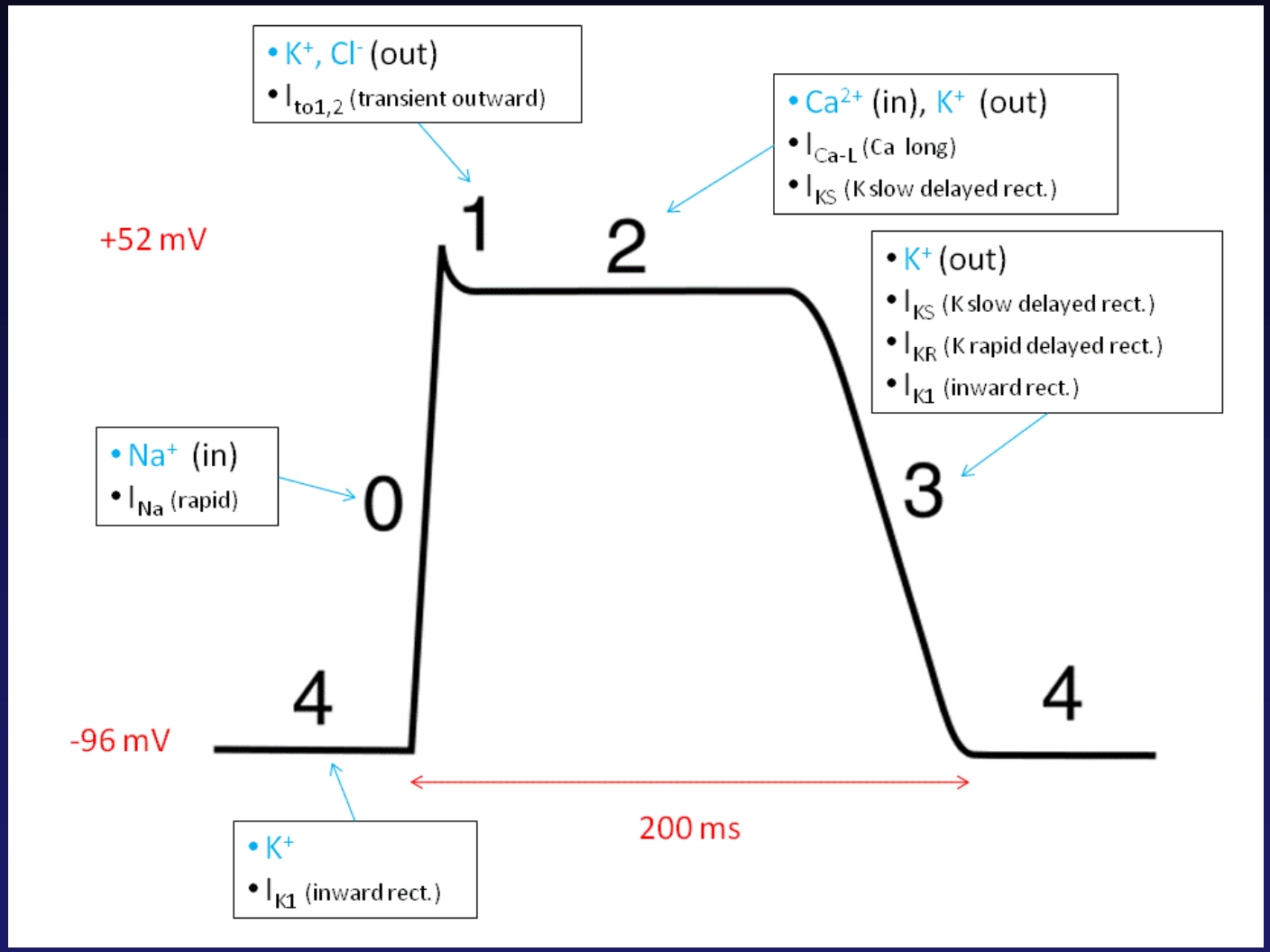

Tehran Arrhythmia Center

Cardiac action potentials from different locations have different shapes

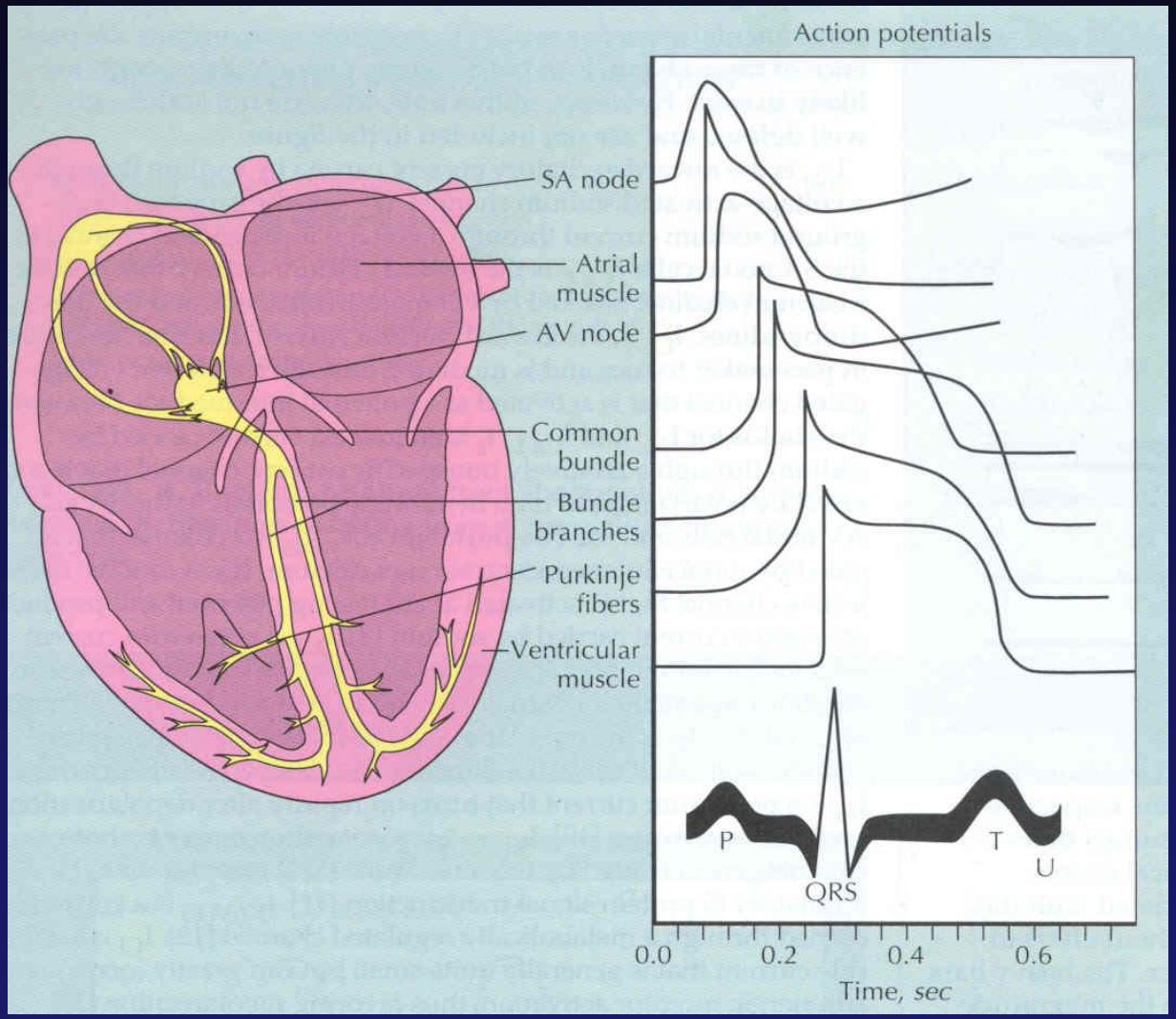

Tehran Arrhythmia Center

Electrophysiology

- Electric currents that spread through the heart are produced by three components
  - Cardiac pacemaker cells
  - Specialized conduction tissue
  - The heart muscle
- ECG only records the depolarization and repolarization potentials generated by atrial and ventricular myocardium.

Electrocardiograph 1903

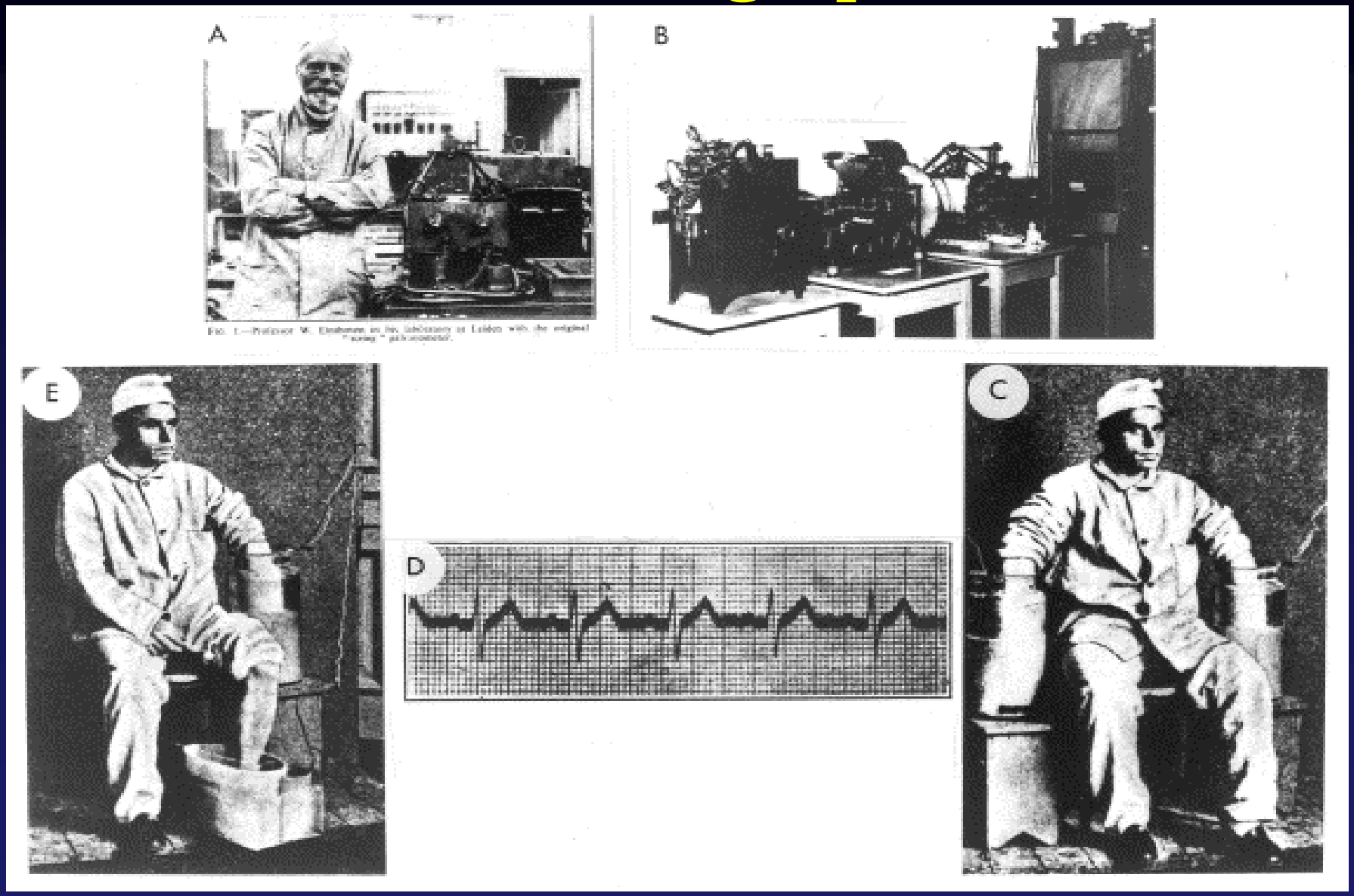

Tehran Arrhythmia Center

Normal Electrocardiogram

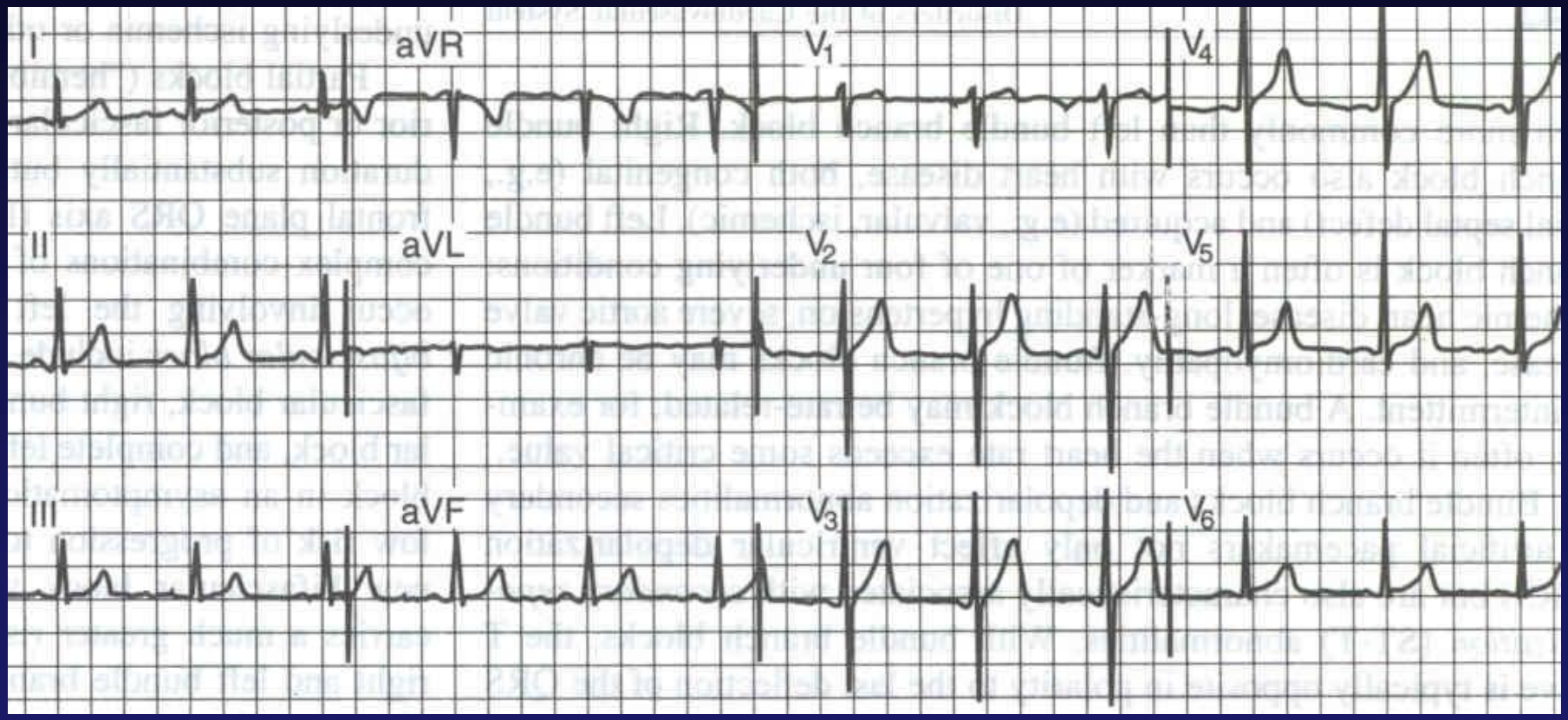

Tehran Arrhythmia Center

ECG Waveforms

Labeled alphabetically beginning with the P wave

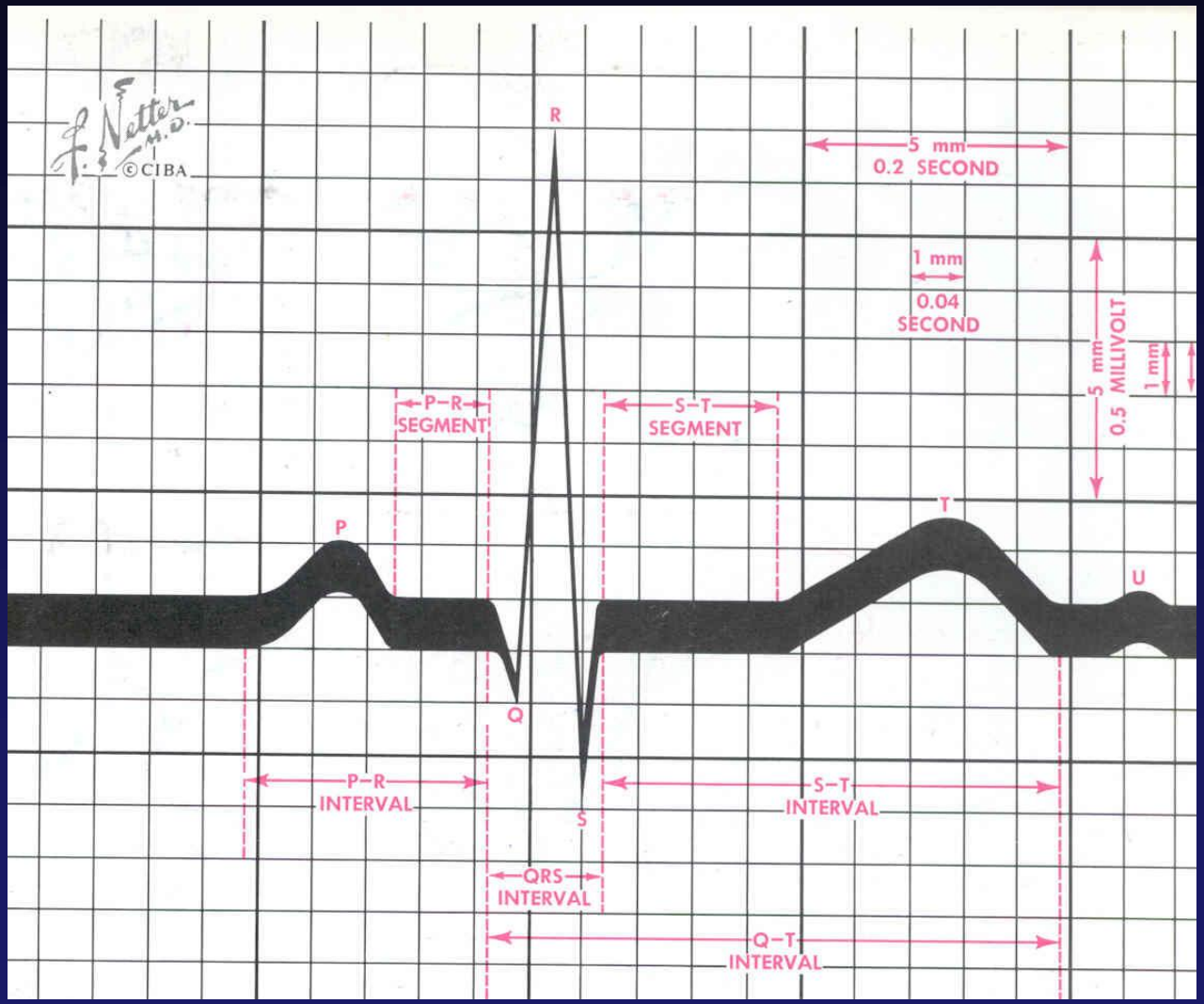

The “PQRST”

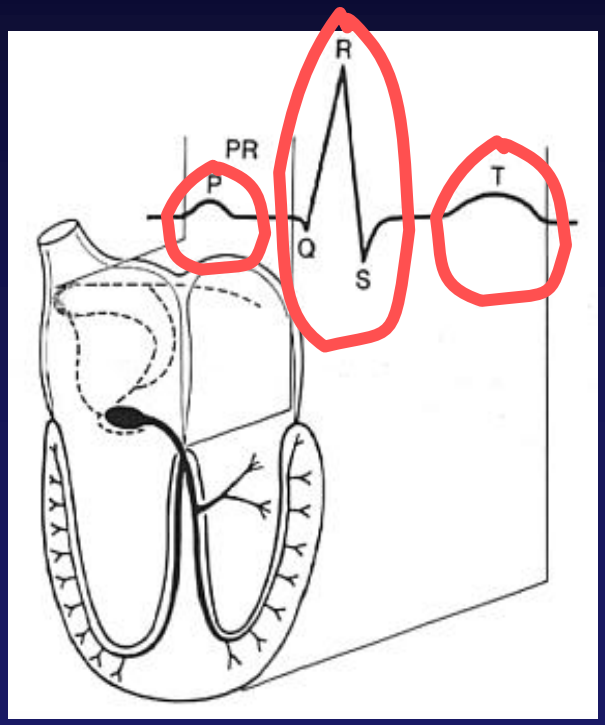

- P wave - Atrial depolarization
- QRS - Ventricular depolarization
- T wave - Ventricular repolarization

QRS-T Cycle Corresponds to Different Phases of Ventricular Action Potential

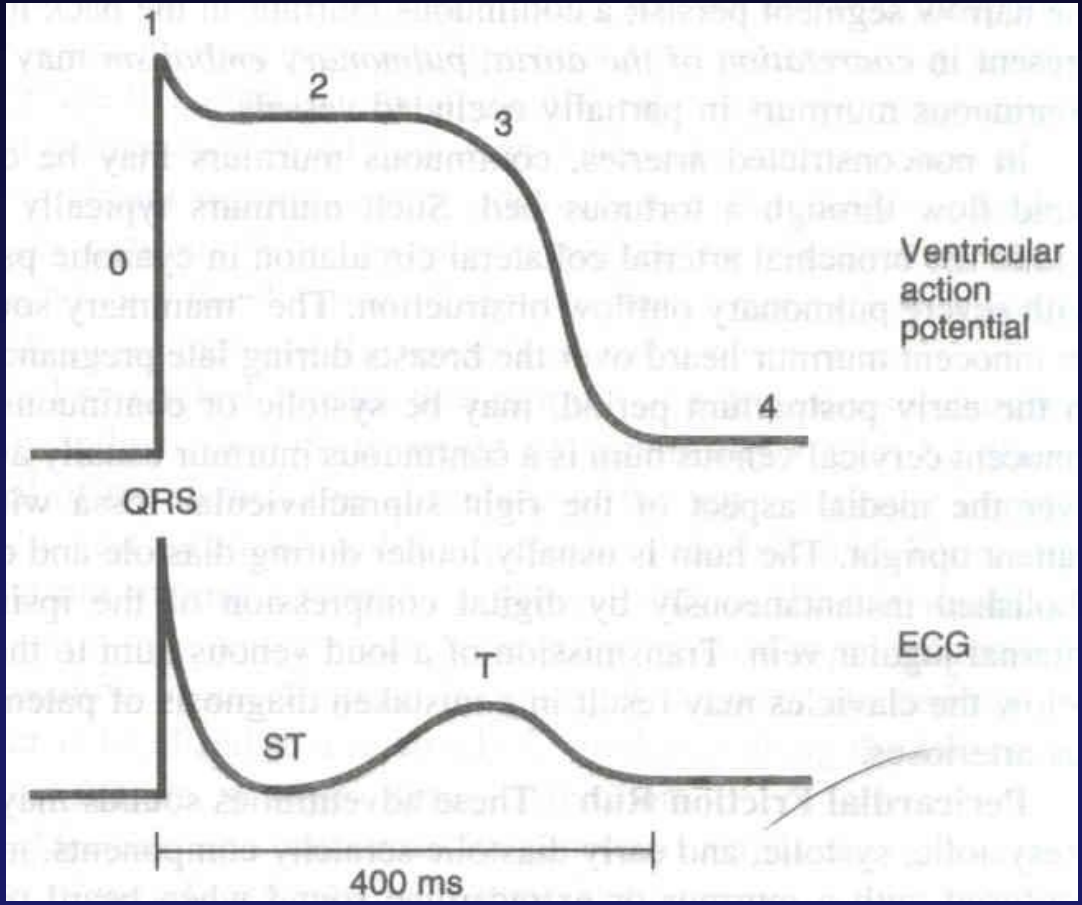

Tehran Arrhythmia Center

The PR Interval

Atrial depolarization

+

delay in AV junction

(AV node/Bundle of His)

(delay allows time for the atria to contract before the ventricles contract)

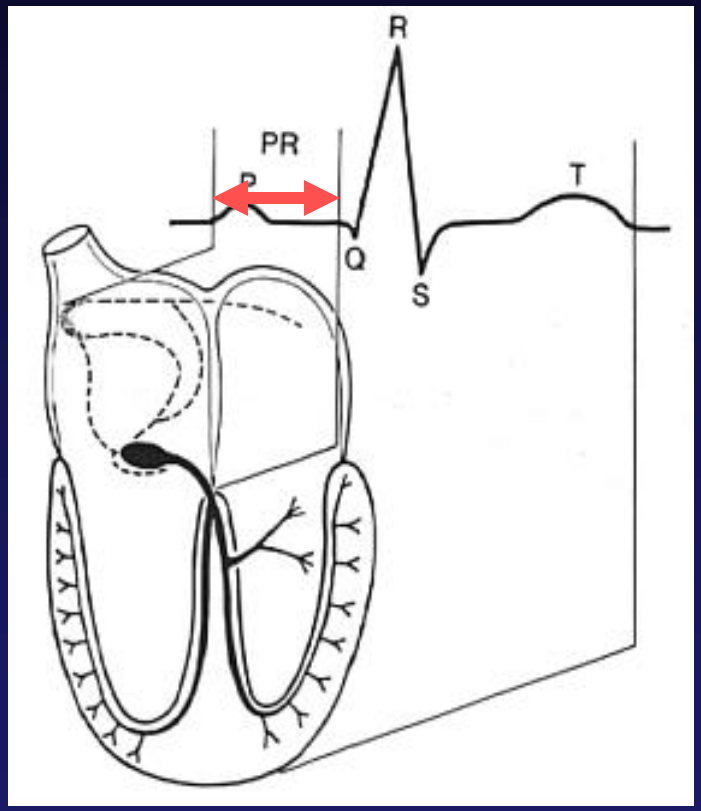

Contribution to PR Interval

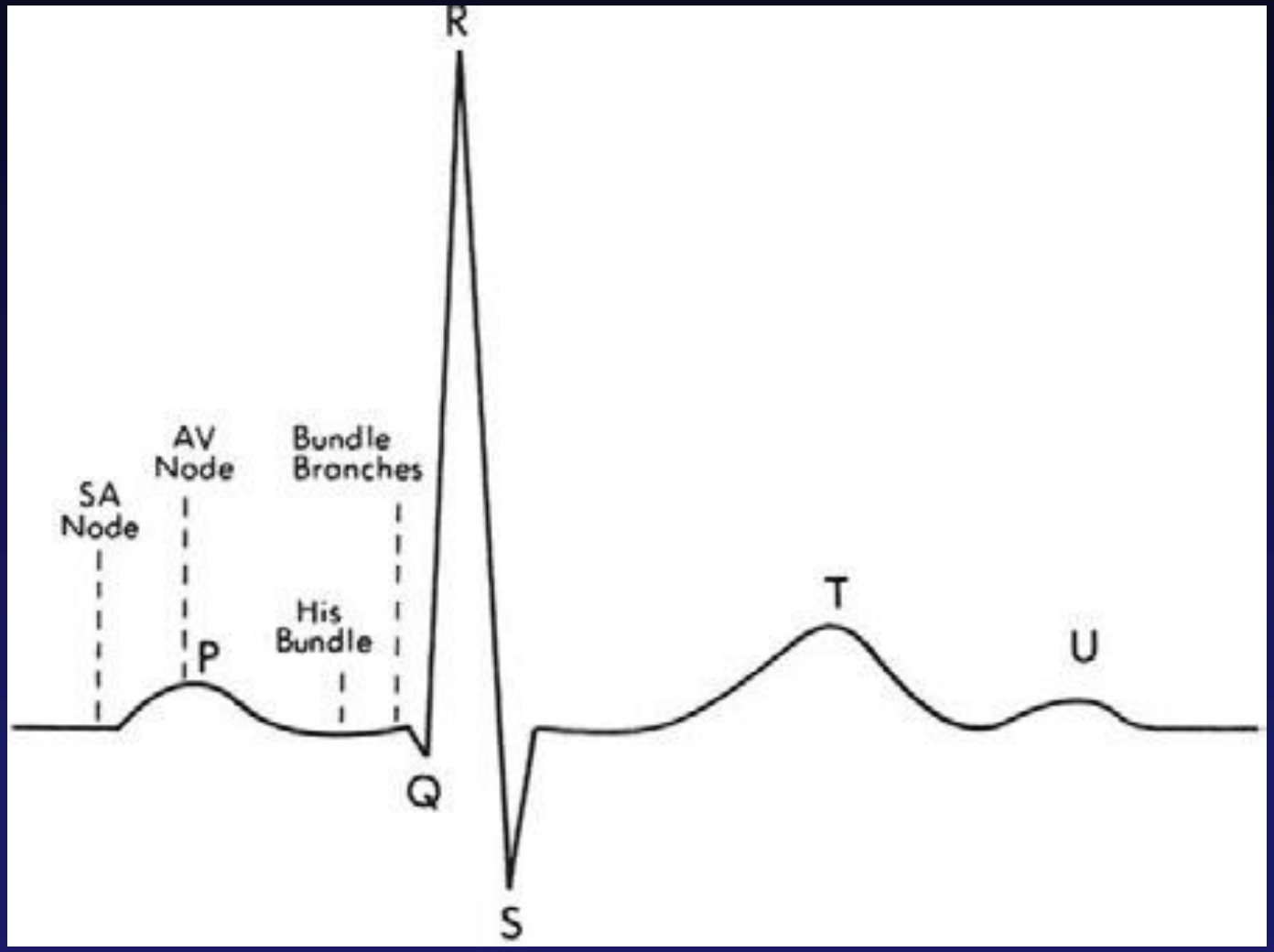

Impulse Conduction & the ECG

Sinoatrial node

↓

AV node

↓

Bundle of His

↓

Bundle Branches

↓

Purkinje fibers

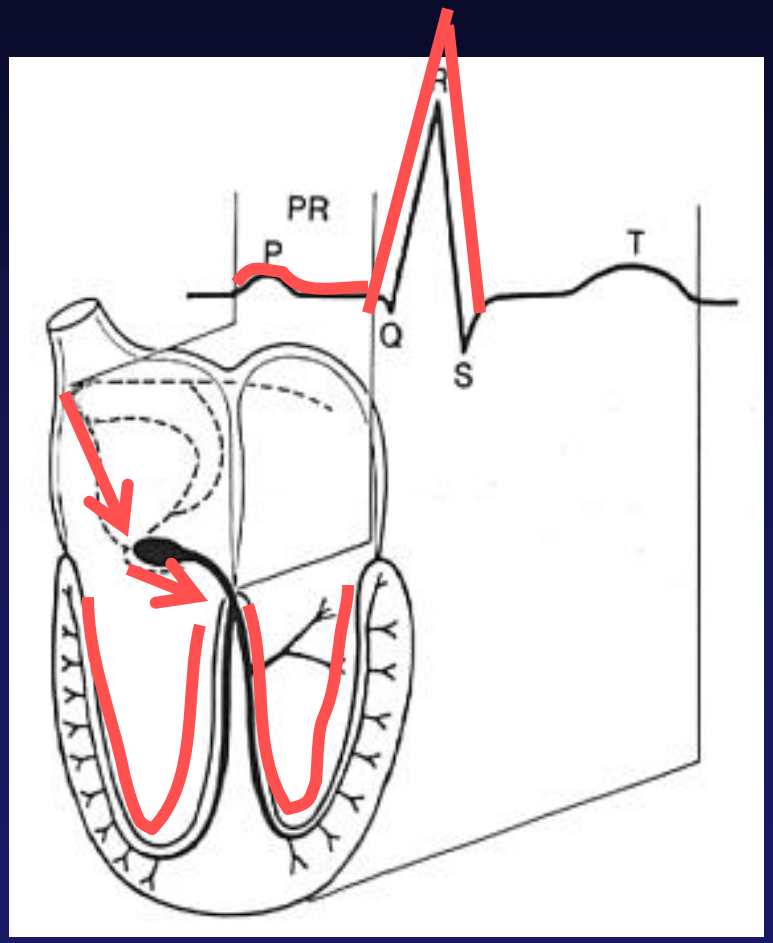

ECG Concept
Galvanometer

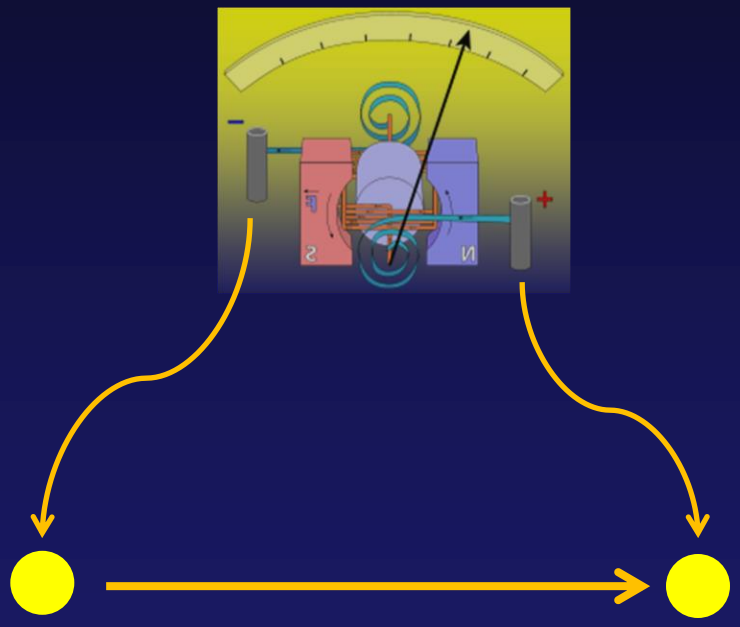

Vector Concept

- Cardiac depolarization and repolarization waves have direction and magnitude.
- They can, therefore, be represented by vectors.
- ECG records the complex spatial and temporal summation of electrical potentials from multiple myocardial fibers conducted to the surface of the body.

Galvanometer

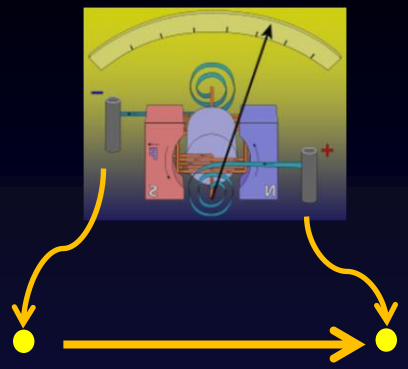

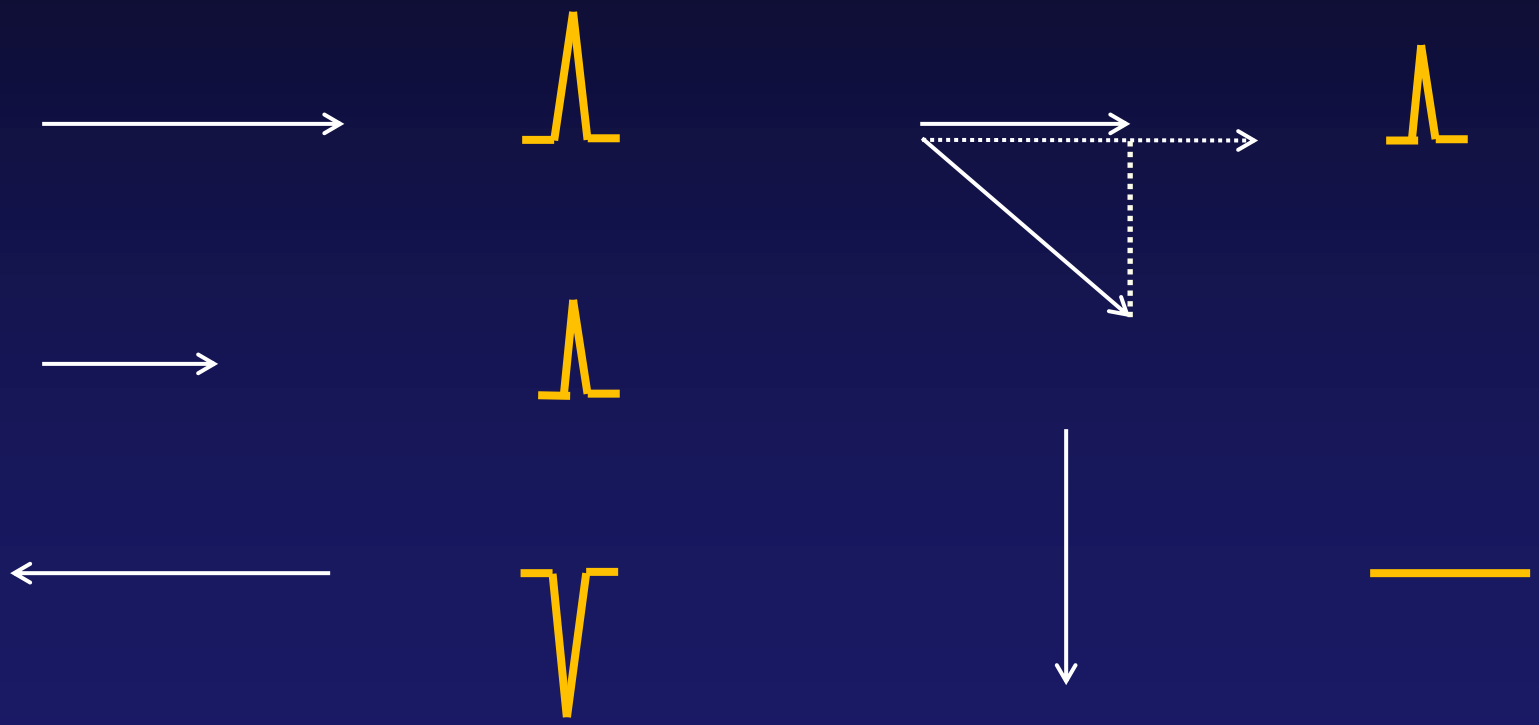

Bipolar Limb Leads

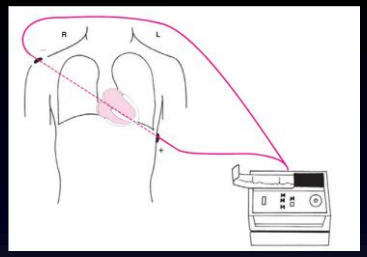

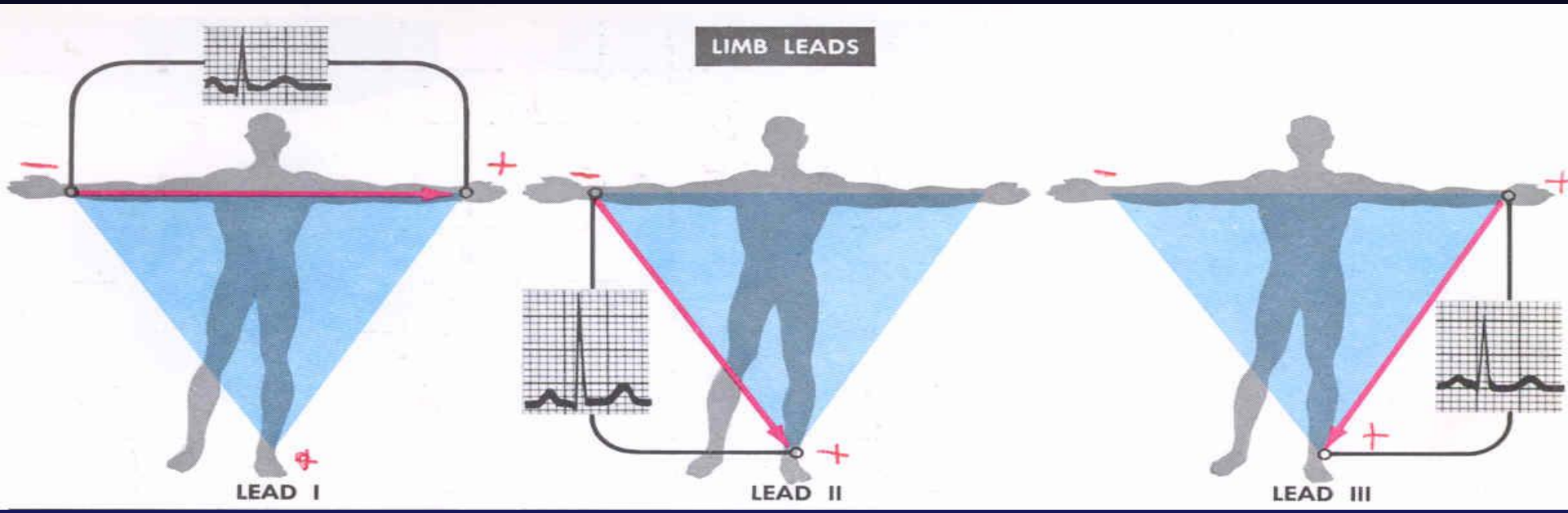

Lead I

Lead II

Lead III

Tehran Arrhythmia Center

Einthoven Triangle

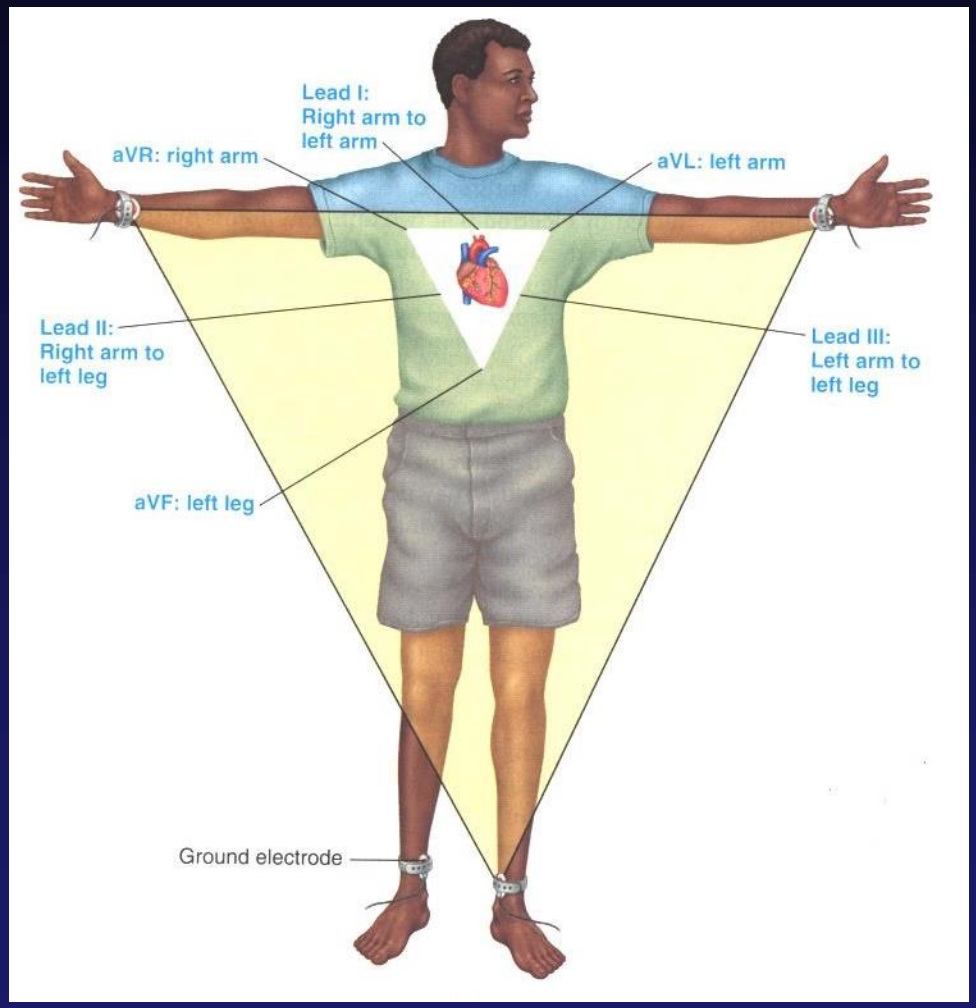

Central Terminal of Wilson

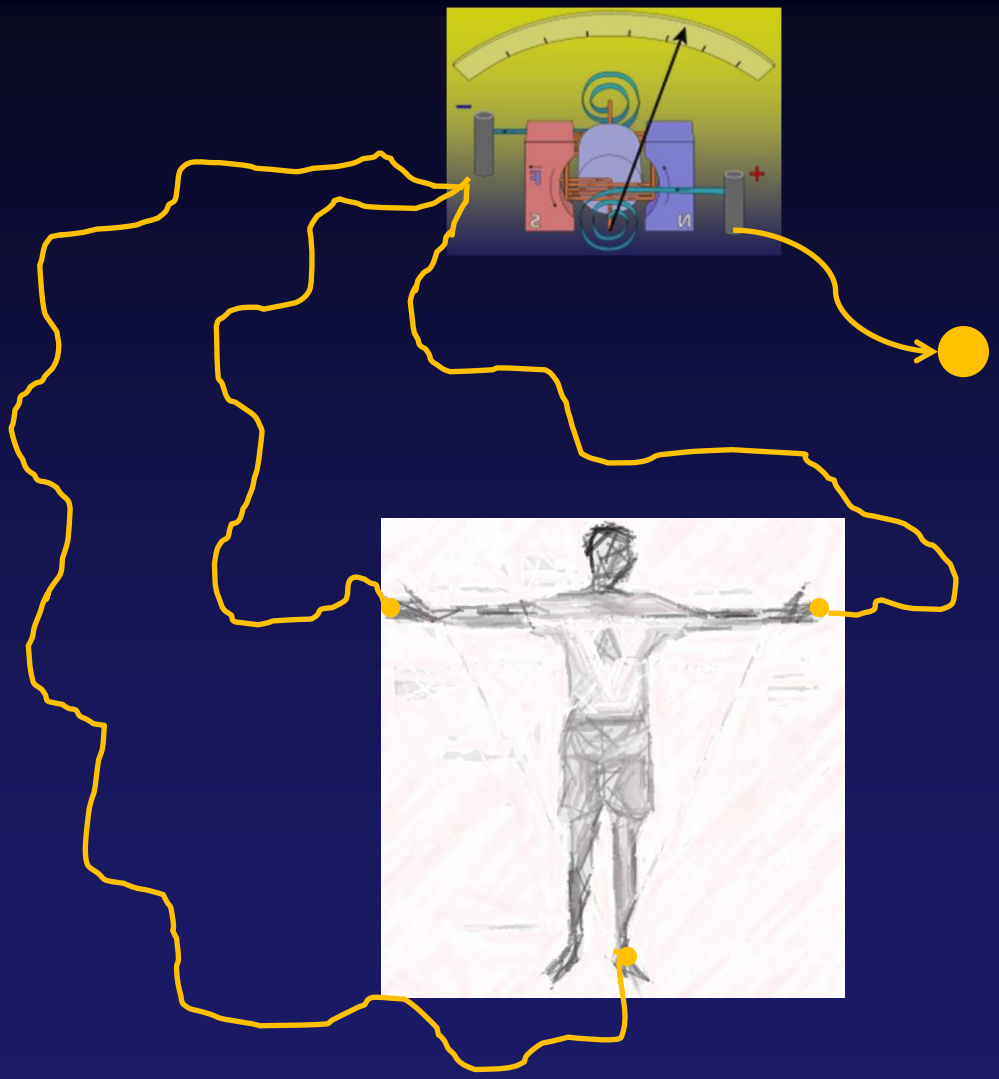

Unipolar Lead

Unipolar Limb Leads

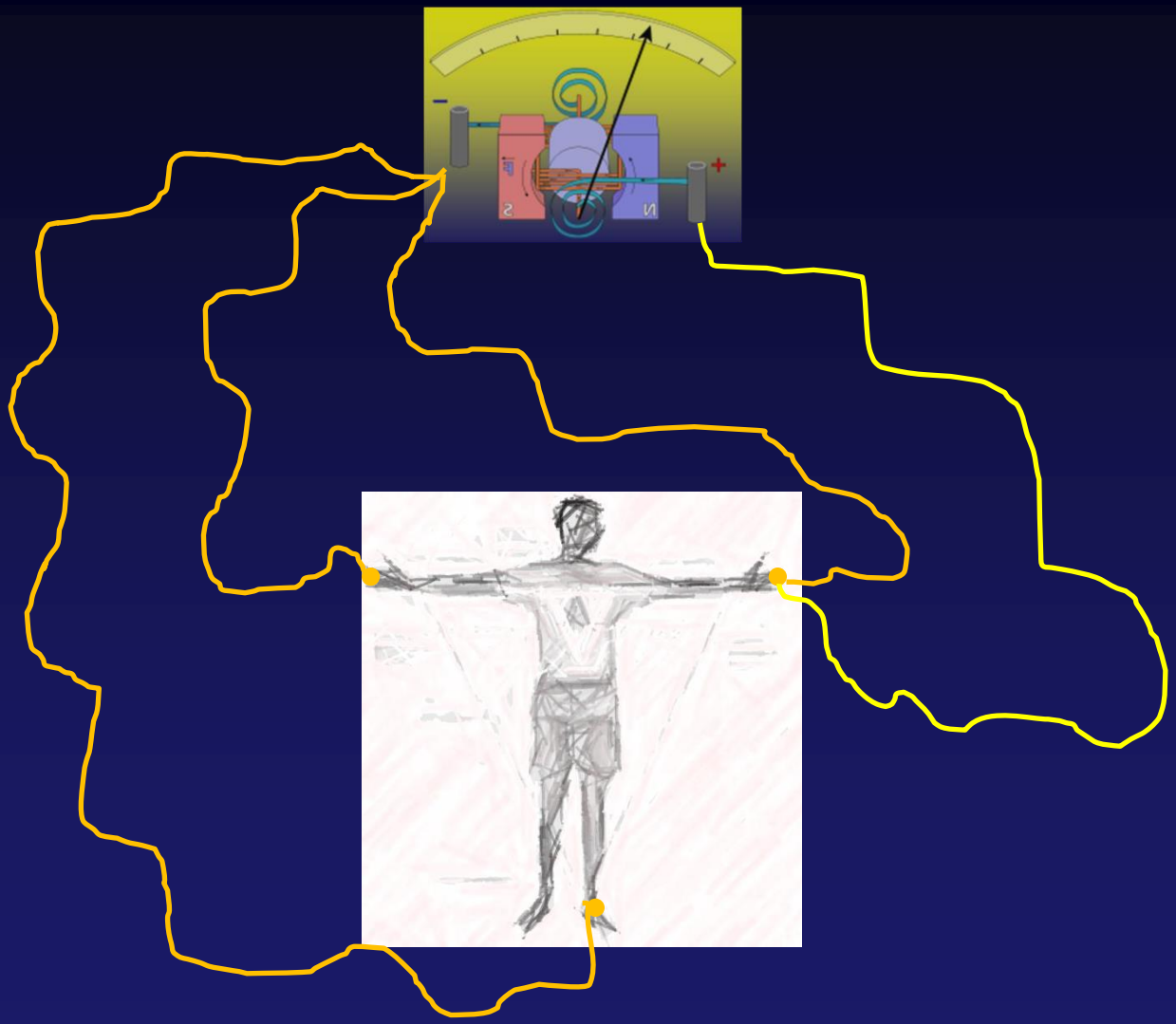

Lead
VL

Unipolar Limb Leads

Lead
VR

Unipolar Limb Lead

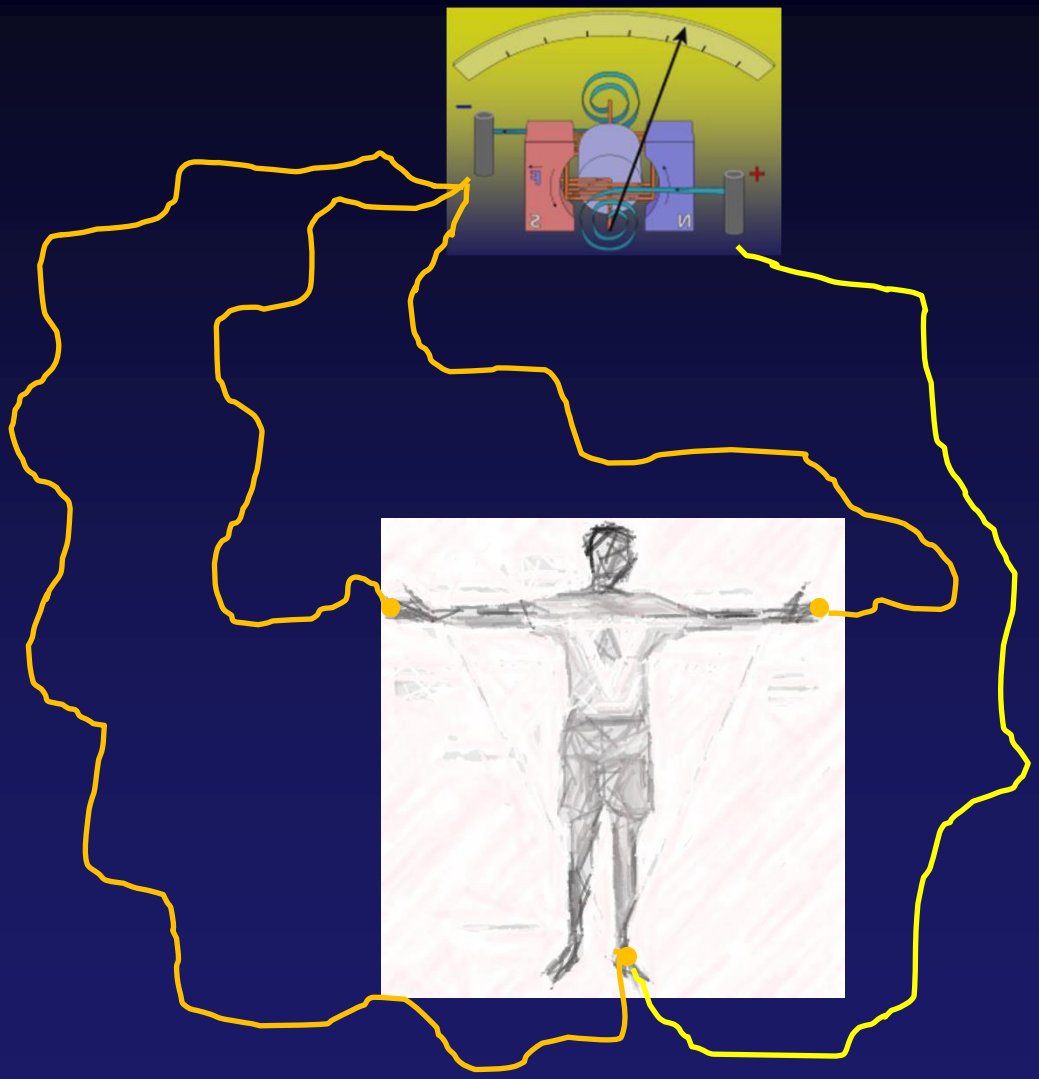

Lead
VF

Unipolar Limb Lead

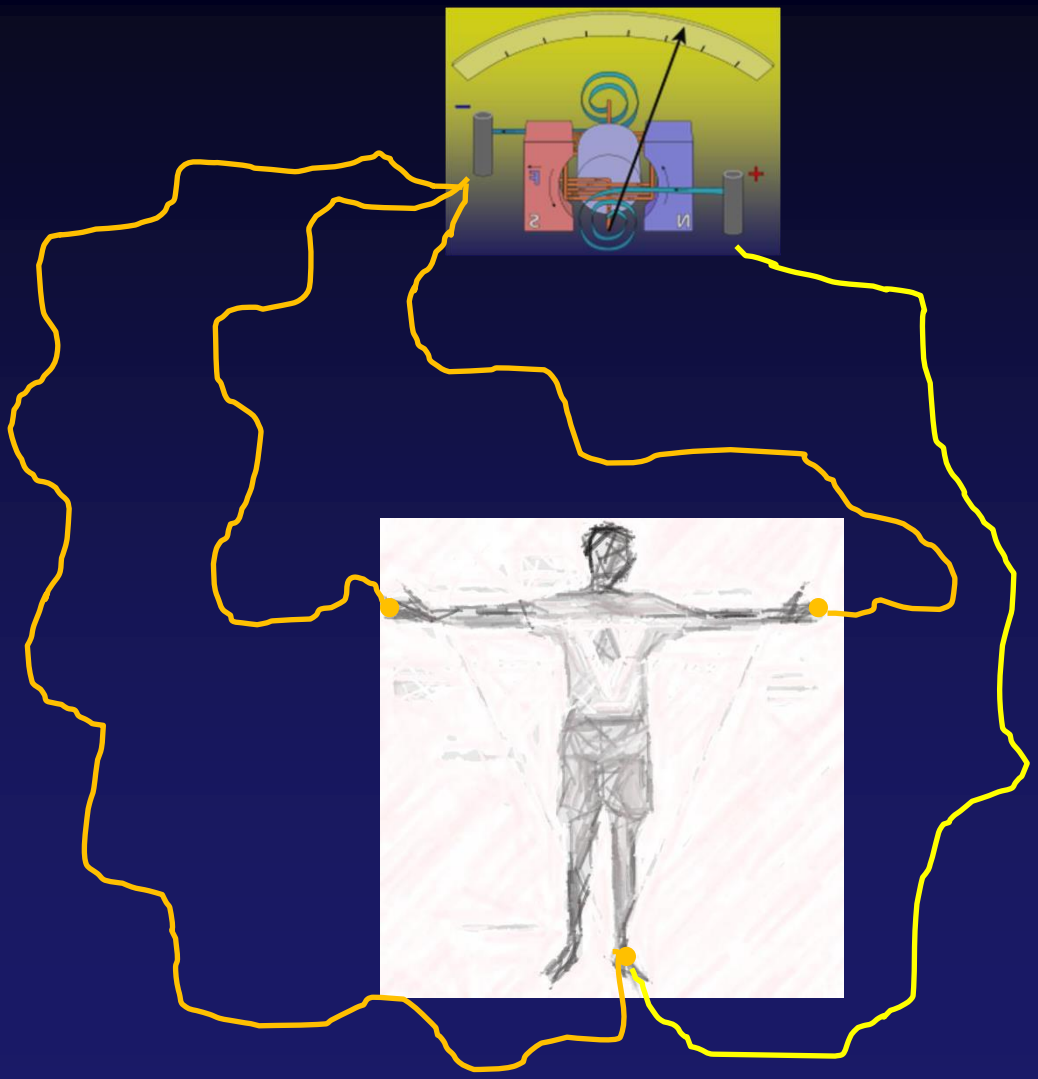

Lead
VF

augmented
VF or
aVF

Unipolar Limb Leads

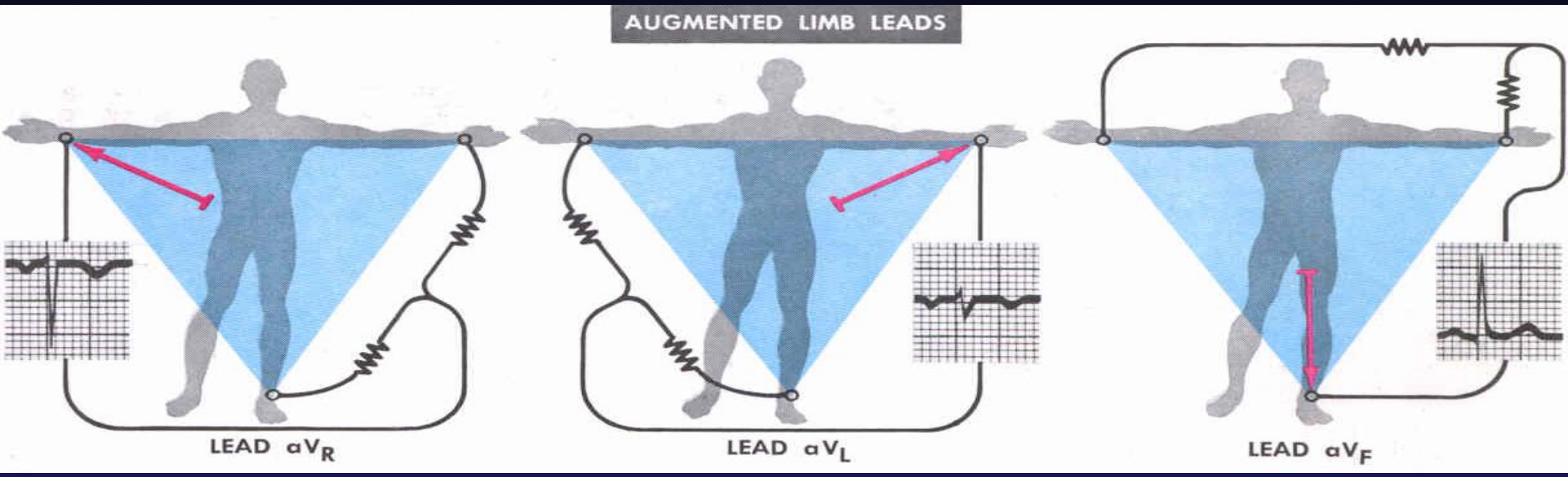

Lead aVR

Lead aVL

Lead aVF

Tehran Arrhythmia Center

Limb Leads Directions

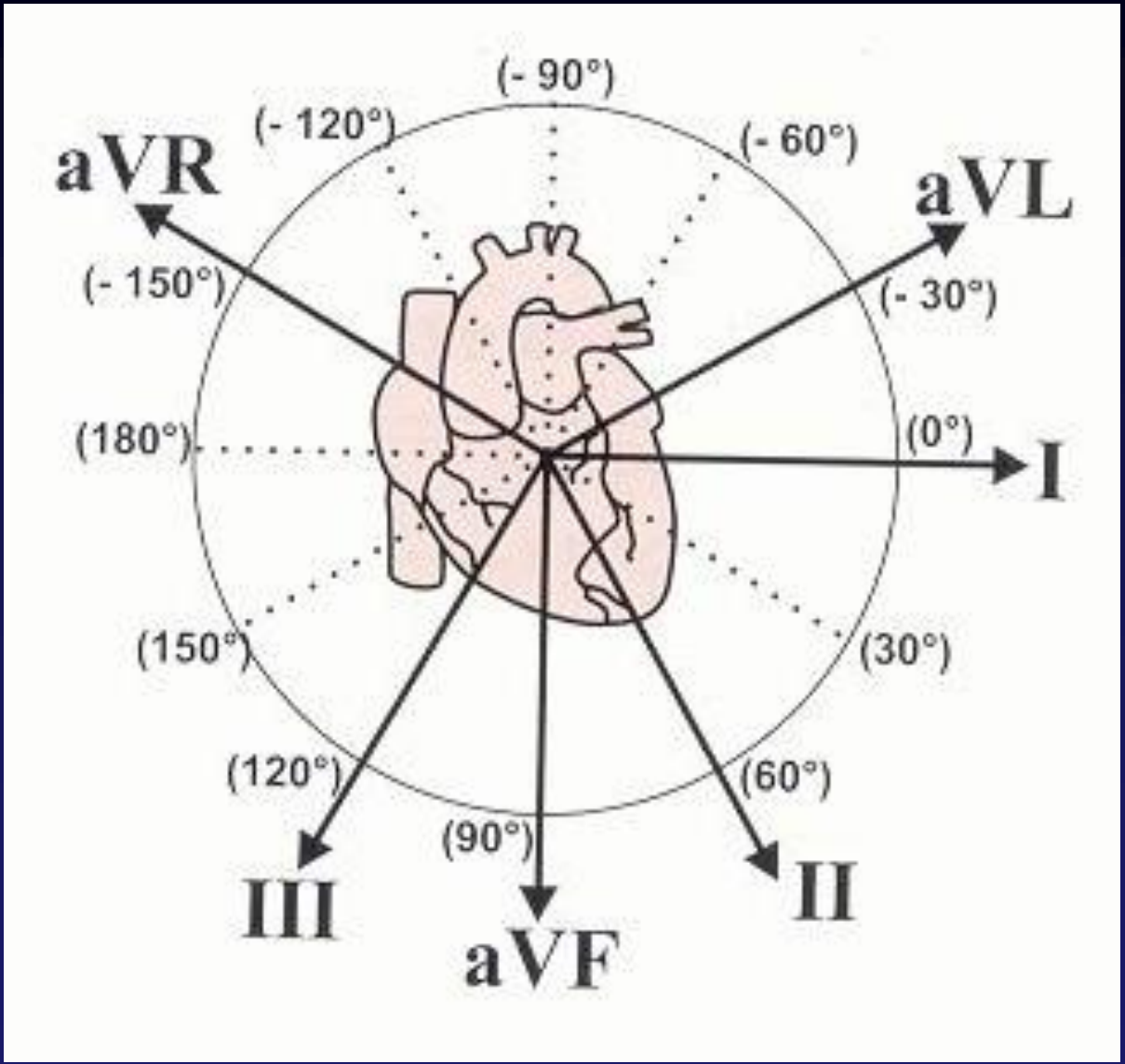

Tehran Arrhythmia Center

3-D Representation of Cardiac Electrical Activity

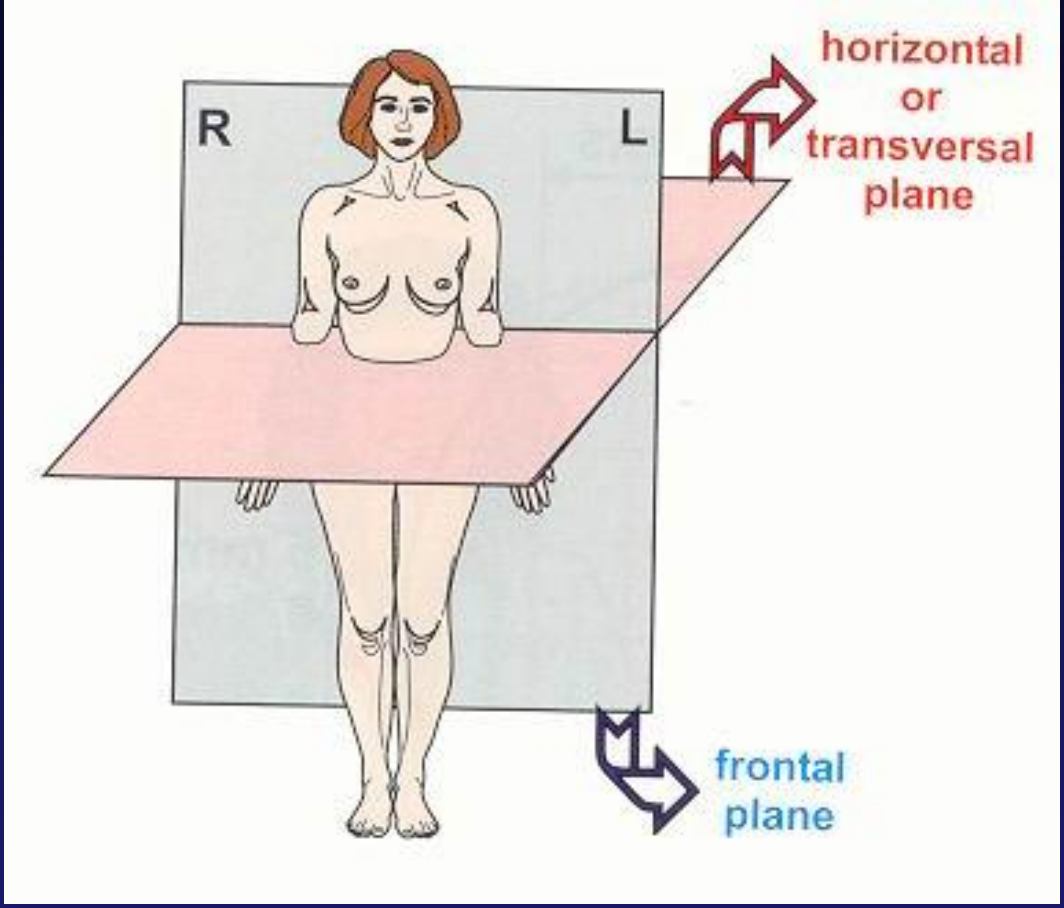

Precordial Leads

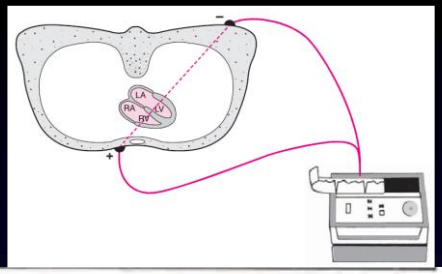

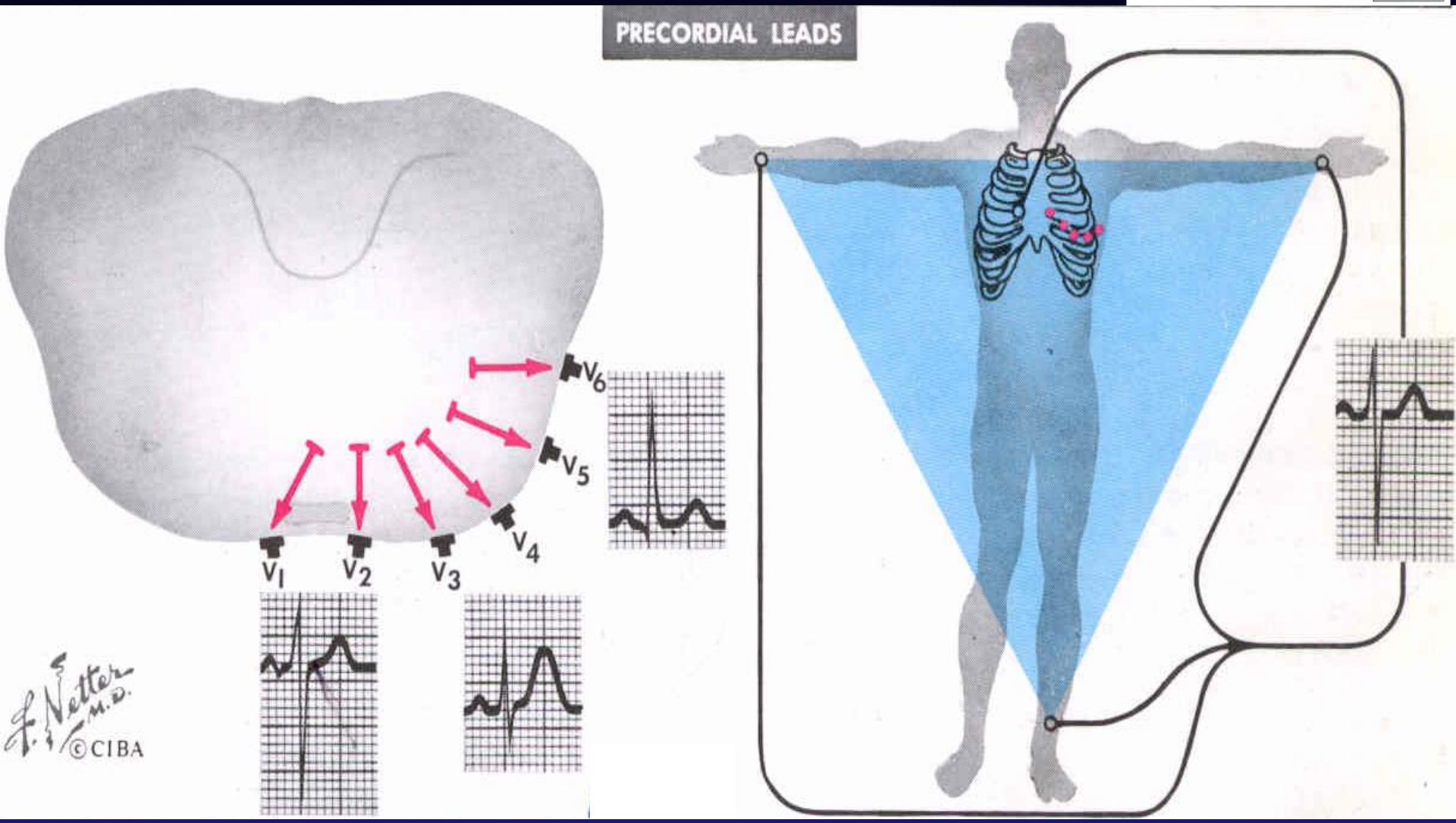

Position of Precordial Electrodes

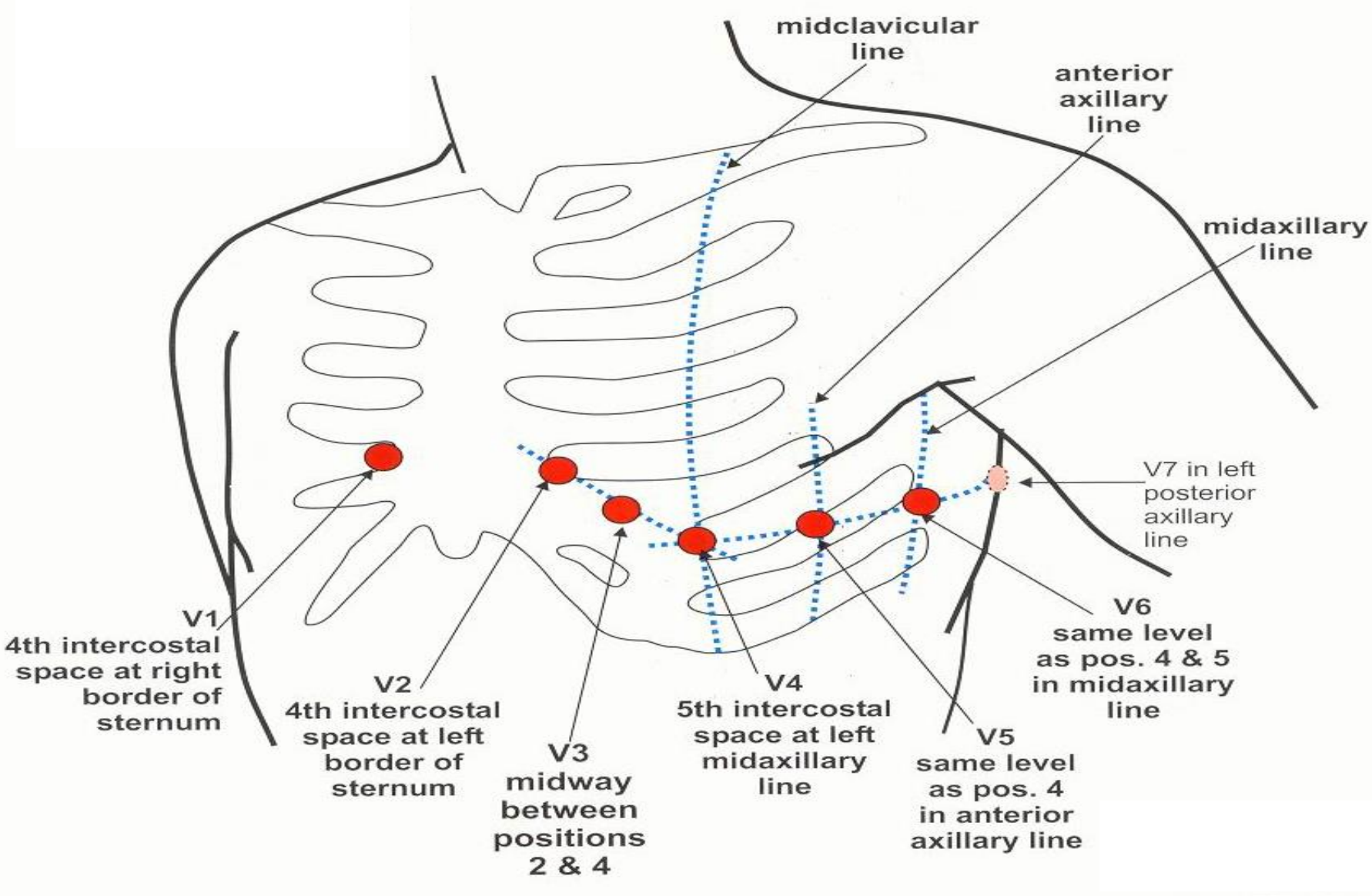

Precordial Leads

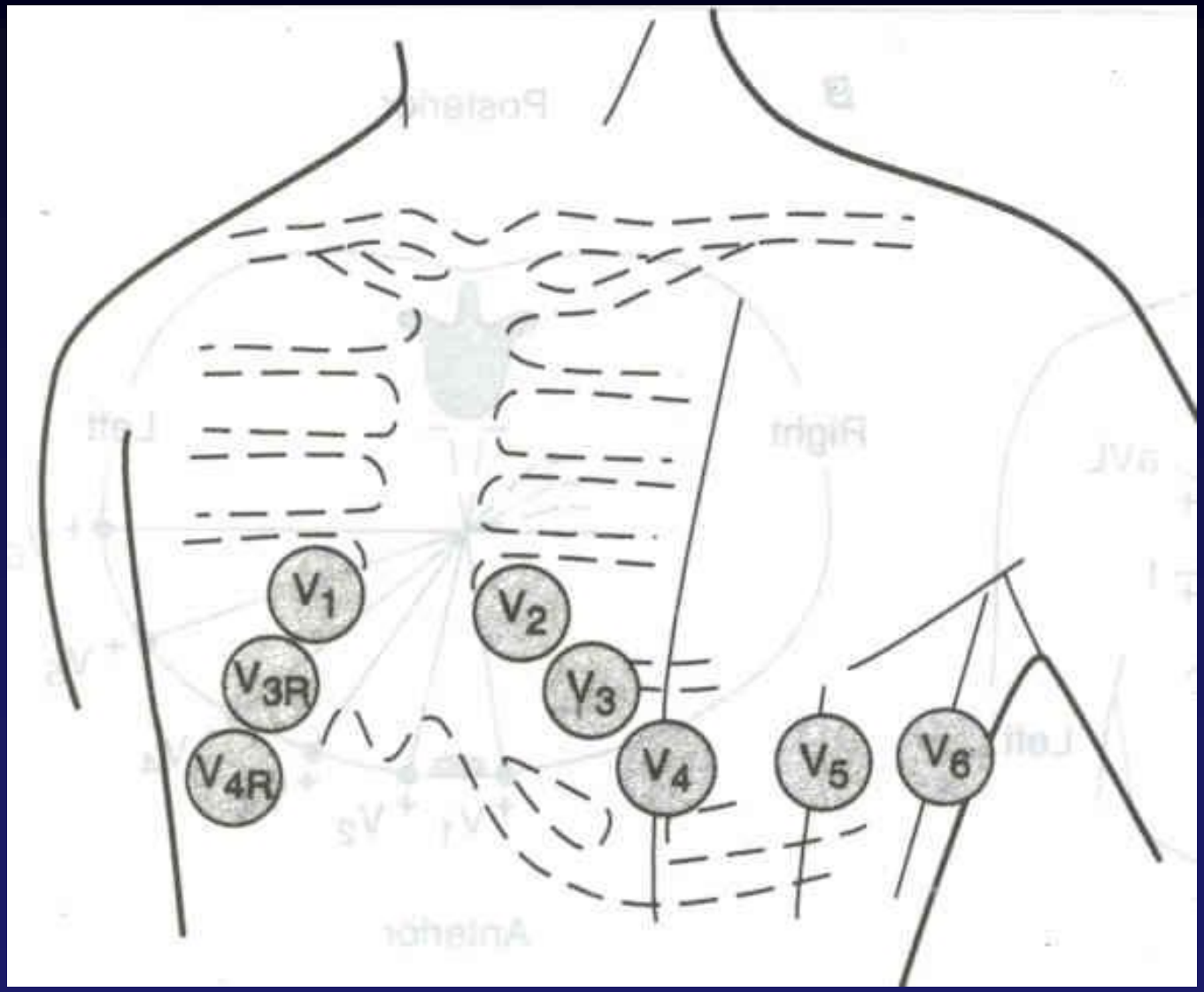

Tehran Arrhythmia Center

Normal Electrocardiogram

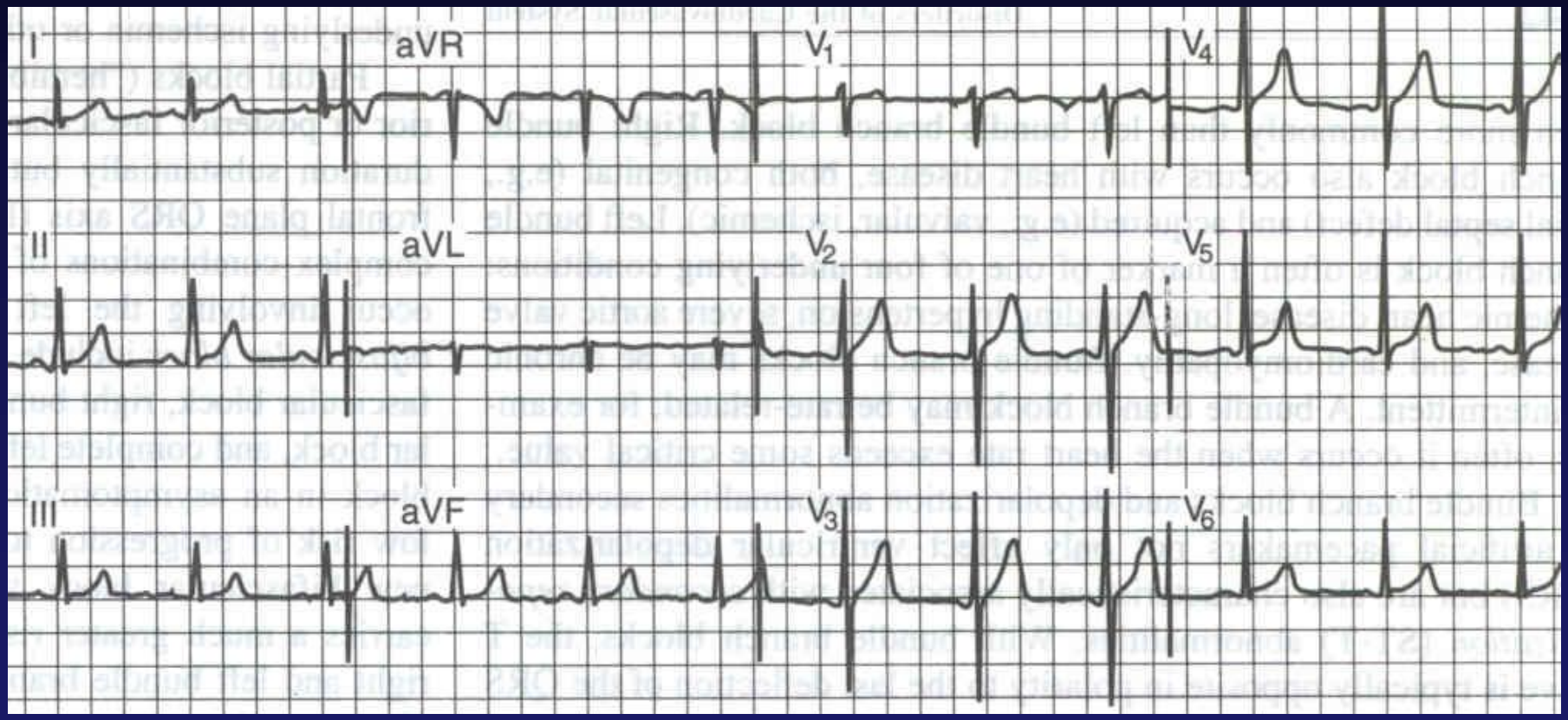

Tehran Arrhythmia Center

QRS Waveforms

Alphabetical terms:

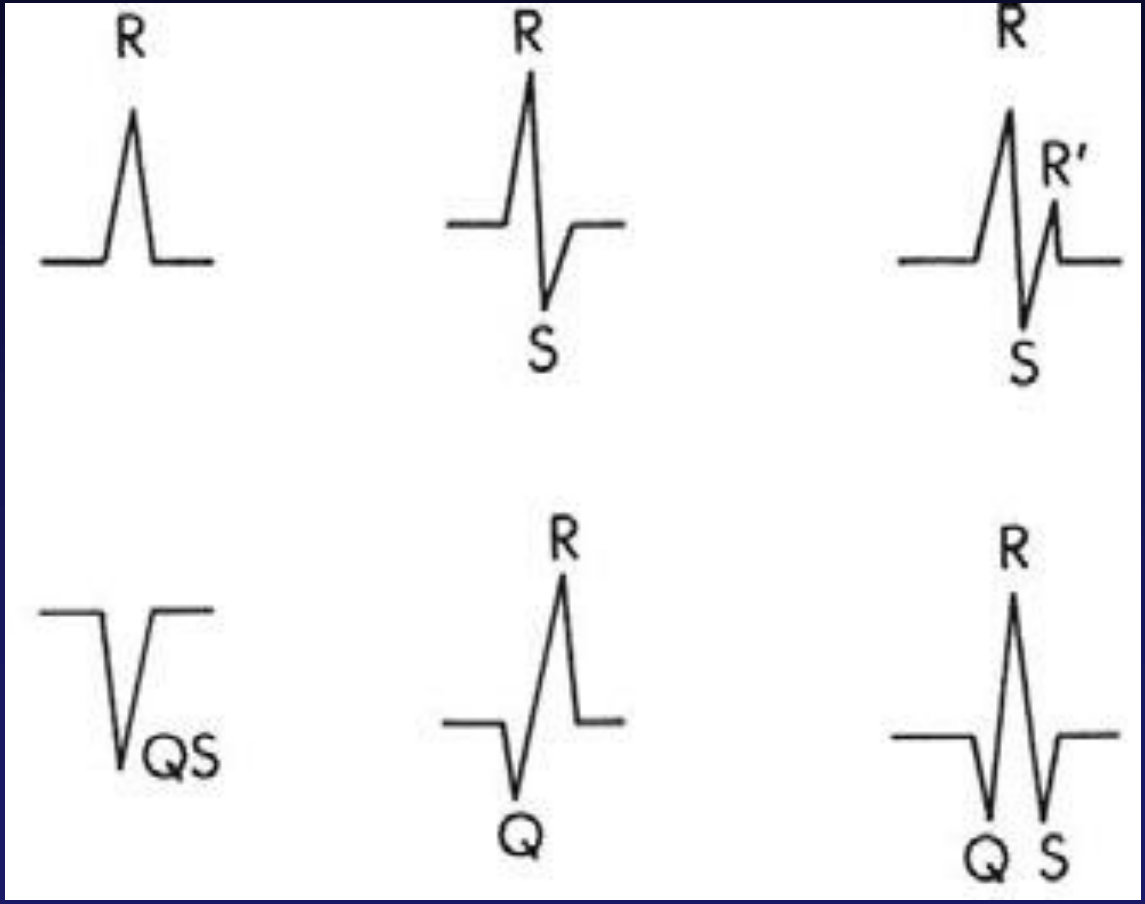

Ventricular Depolarization Axis

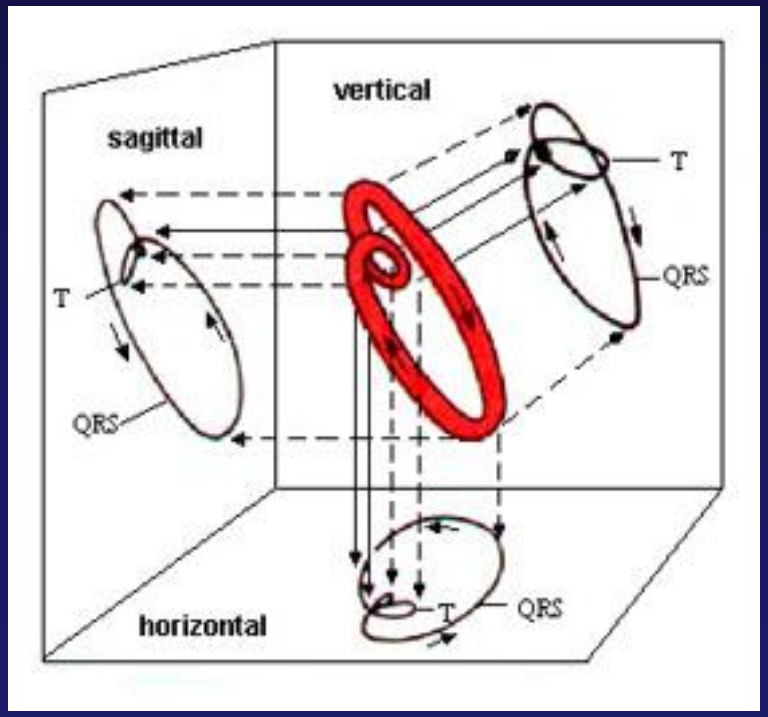

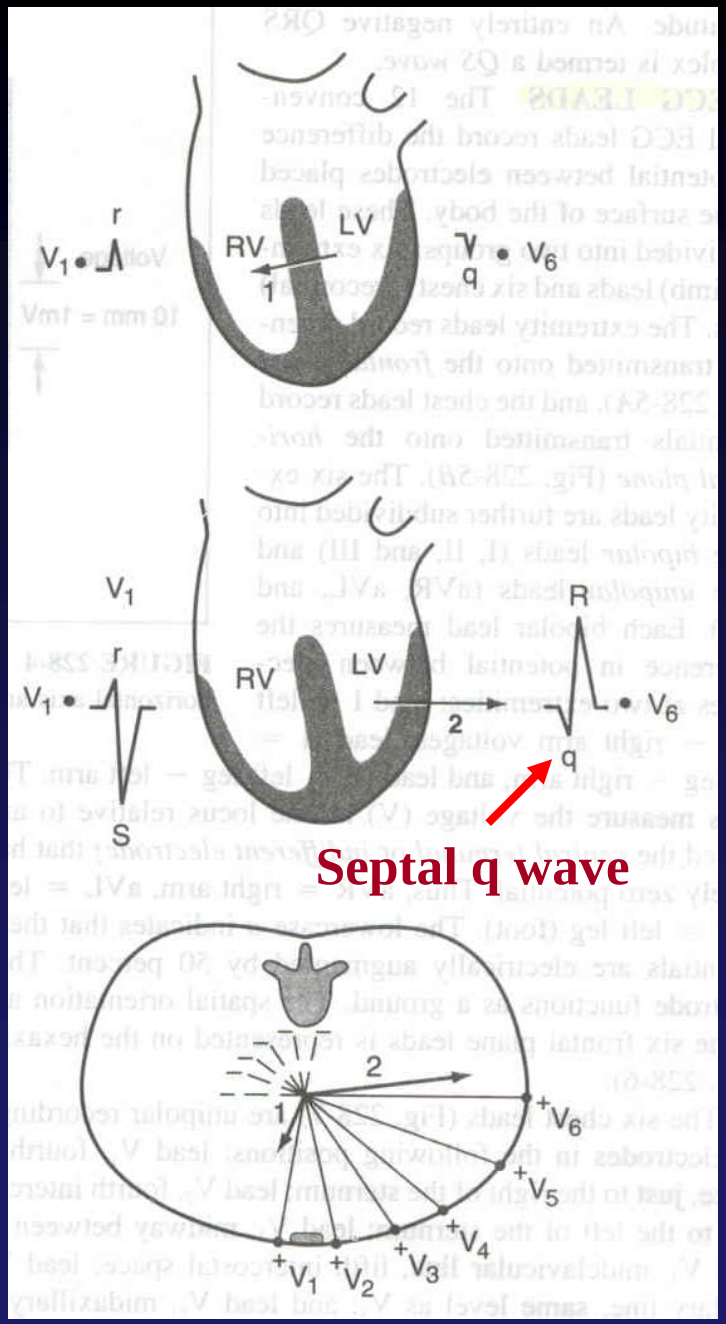

Tehran Arrhythmia Center

Normal Q Waves

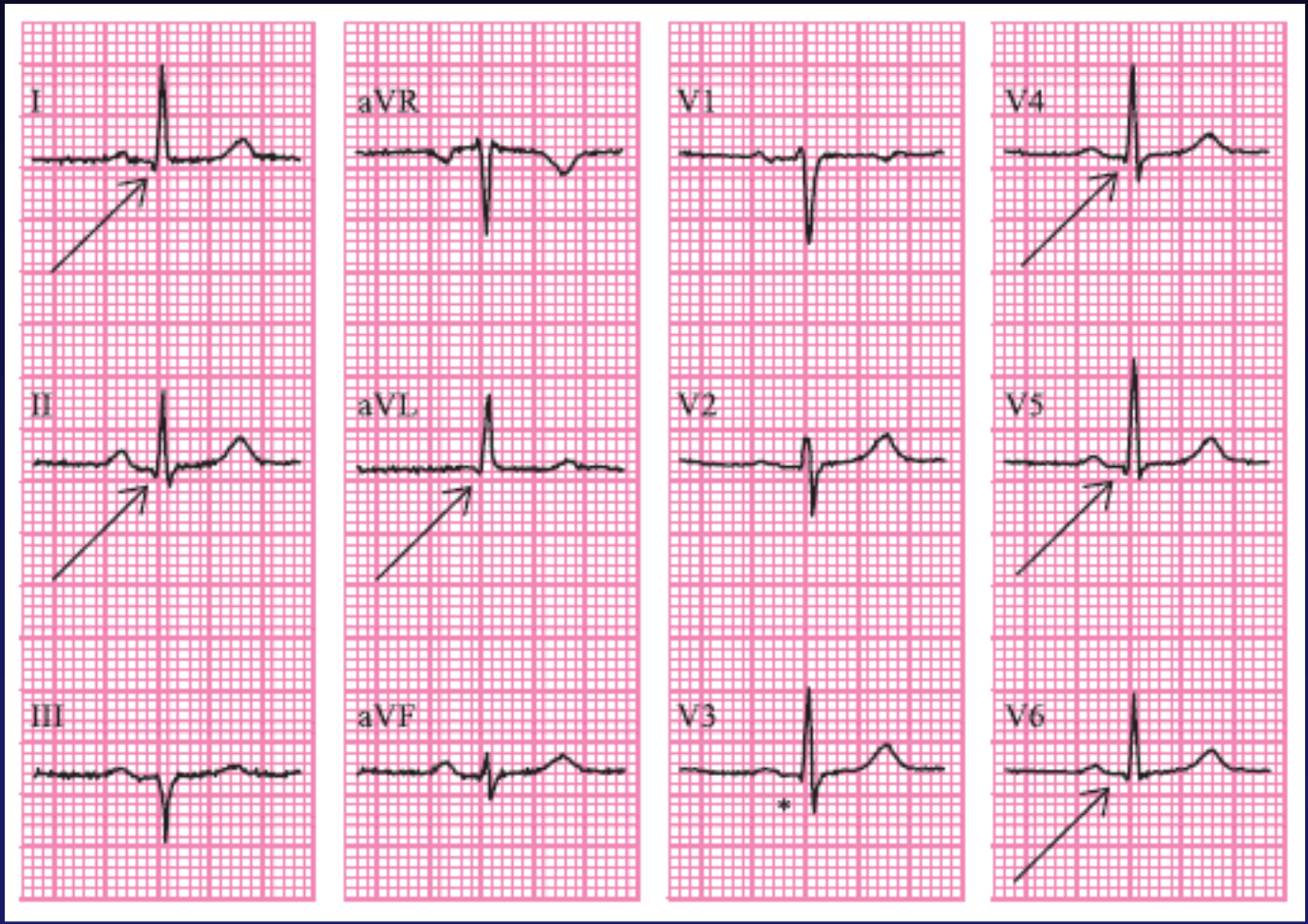

Tehran Arrhythmia Center

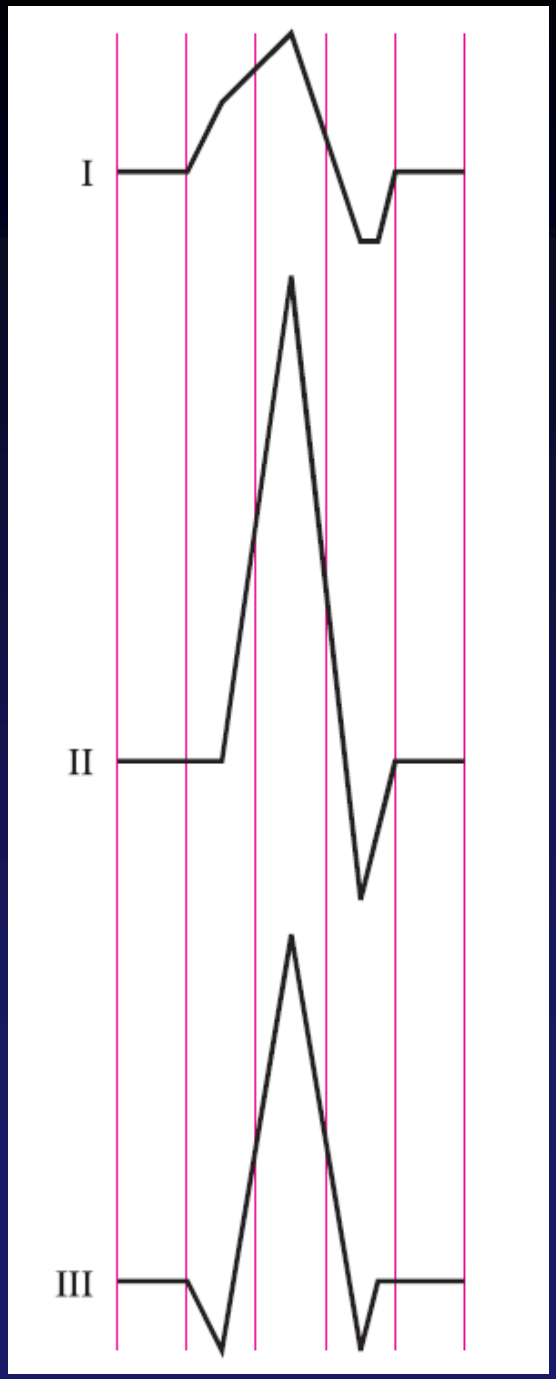

QRS Timing

Each part of QRS may have a different vector (axis).

Mean Activation Vector

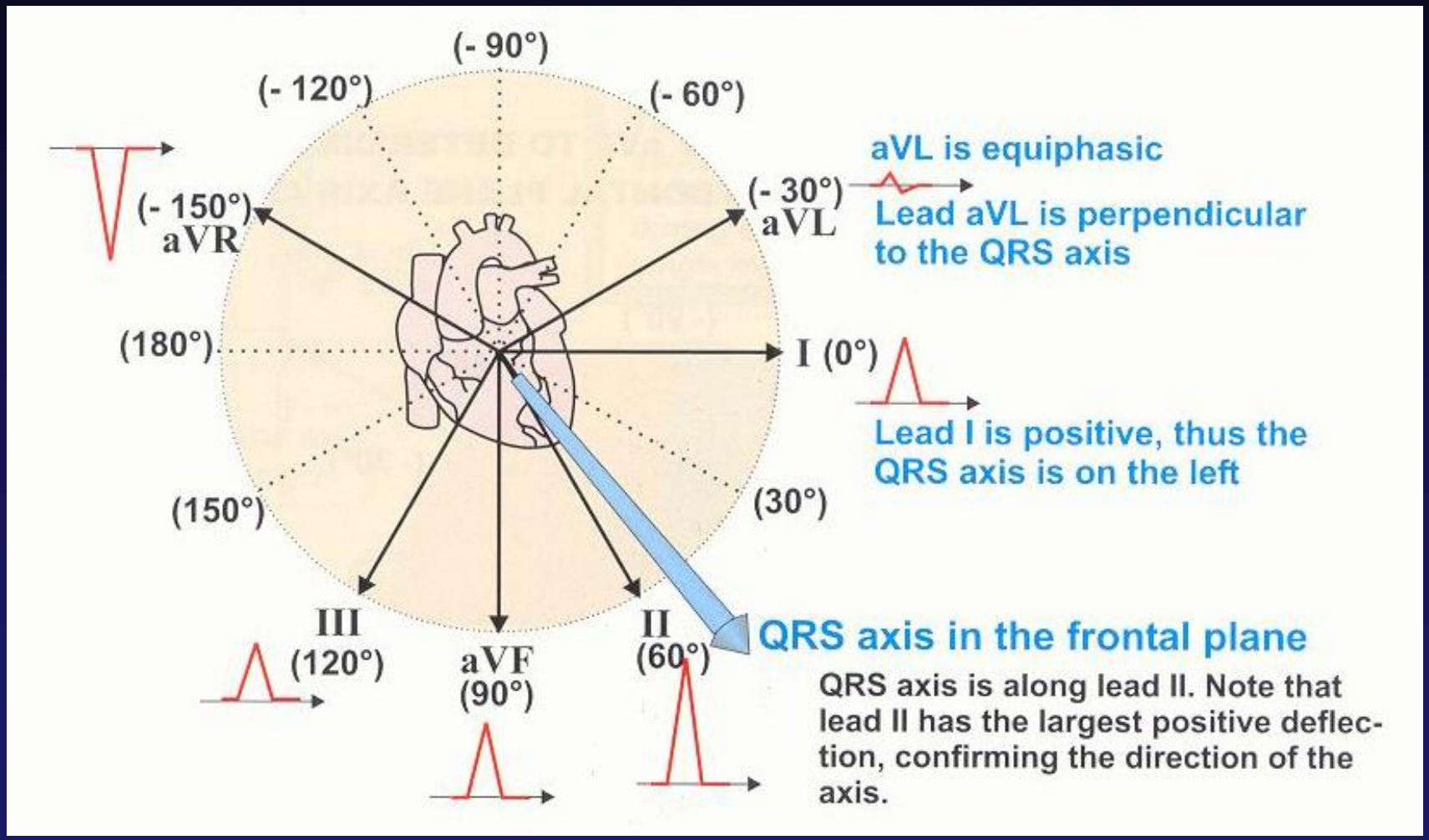

Determination of QRS Axis

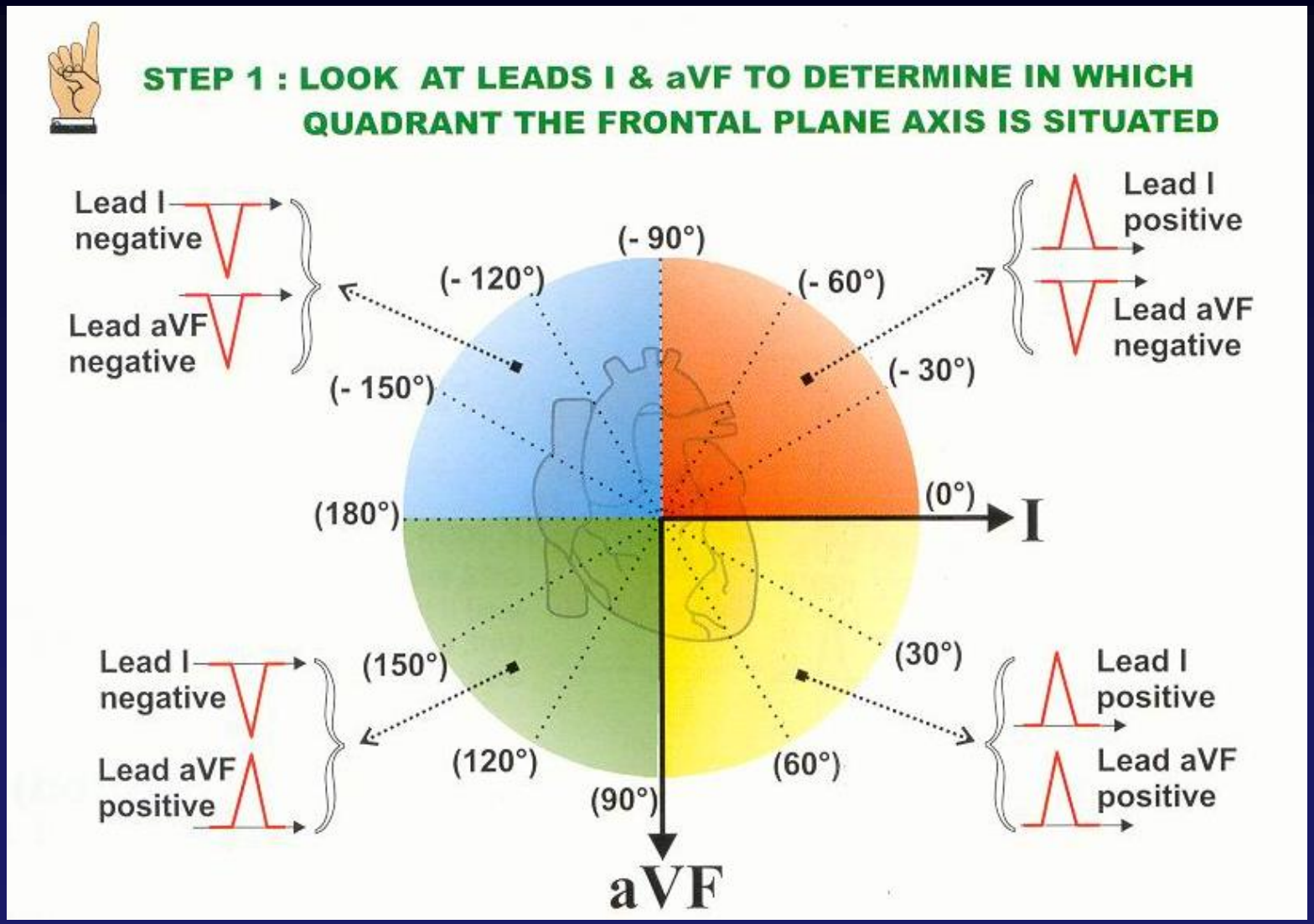

Tehran Arrhythmia Center

Direction of Propagation

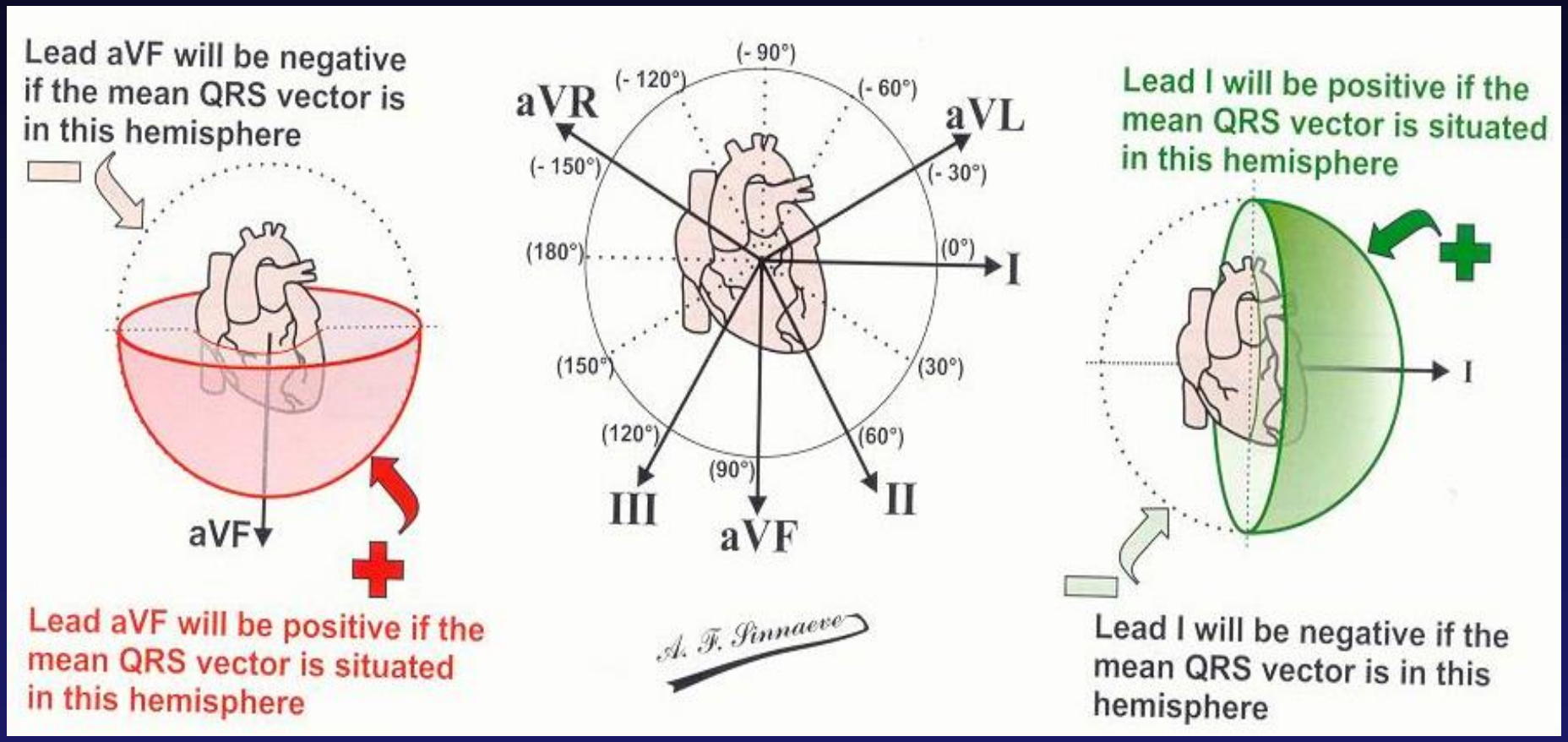

Determination of QRS Axis

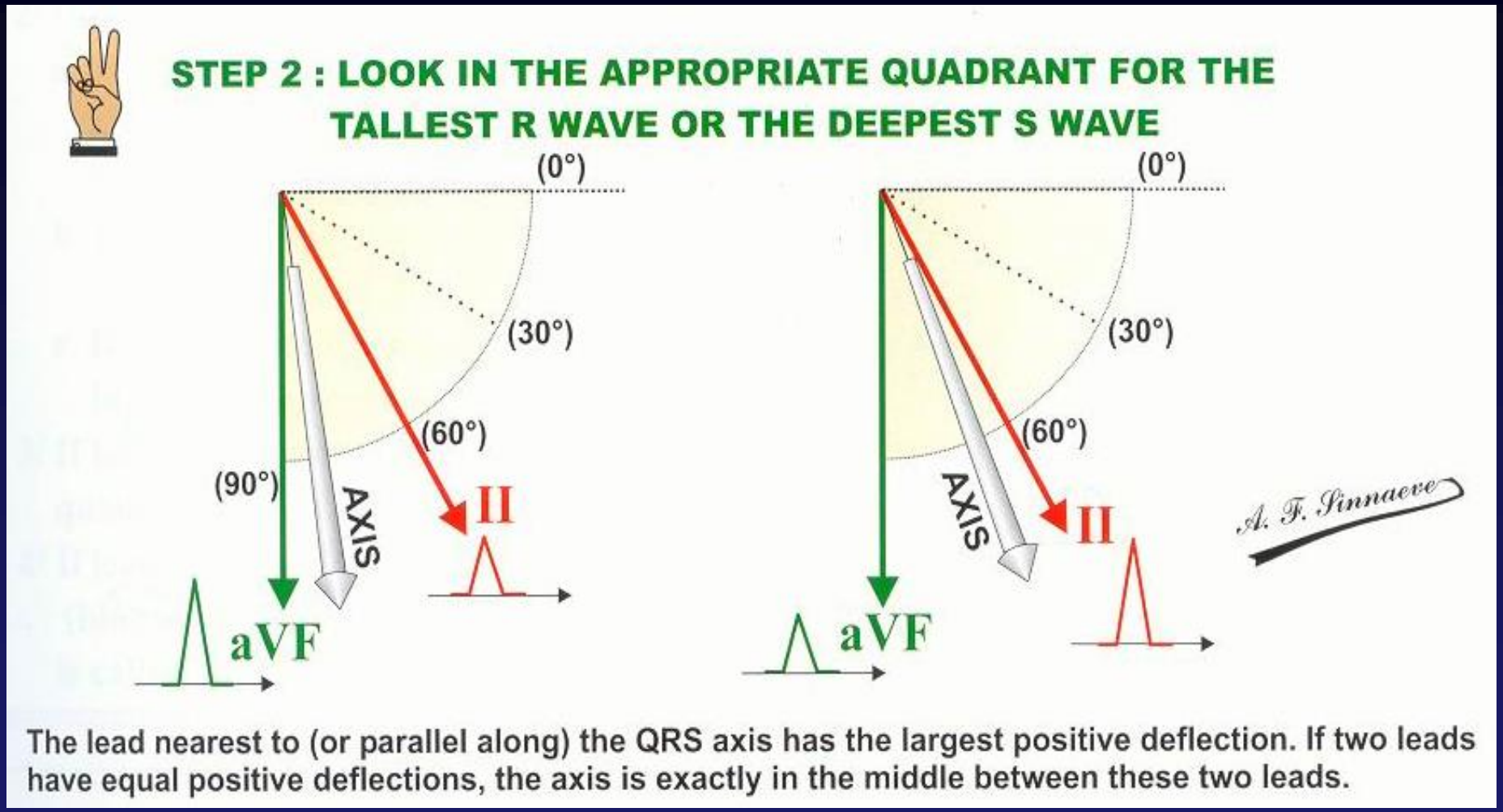

Determination of QRS Axis

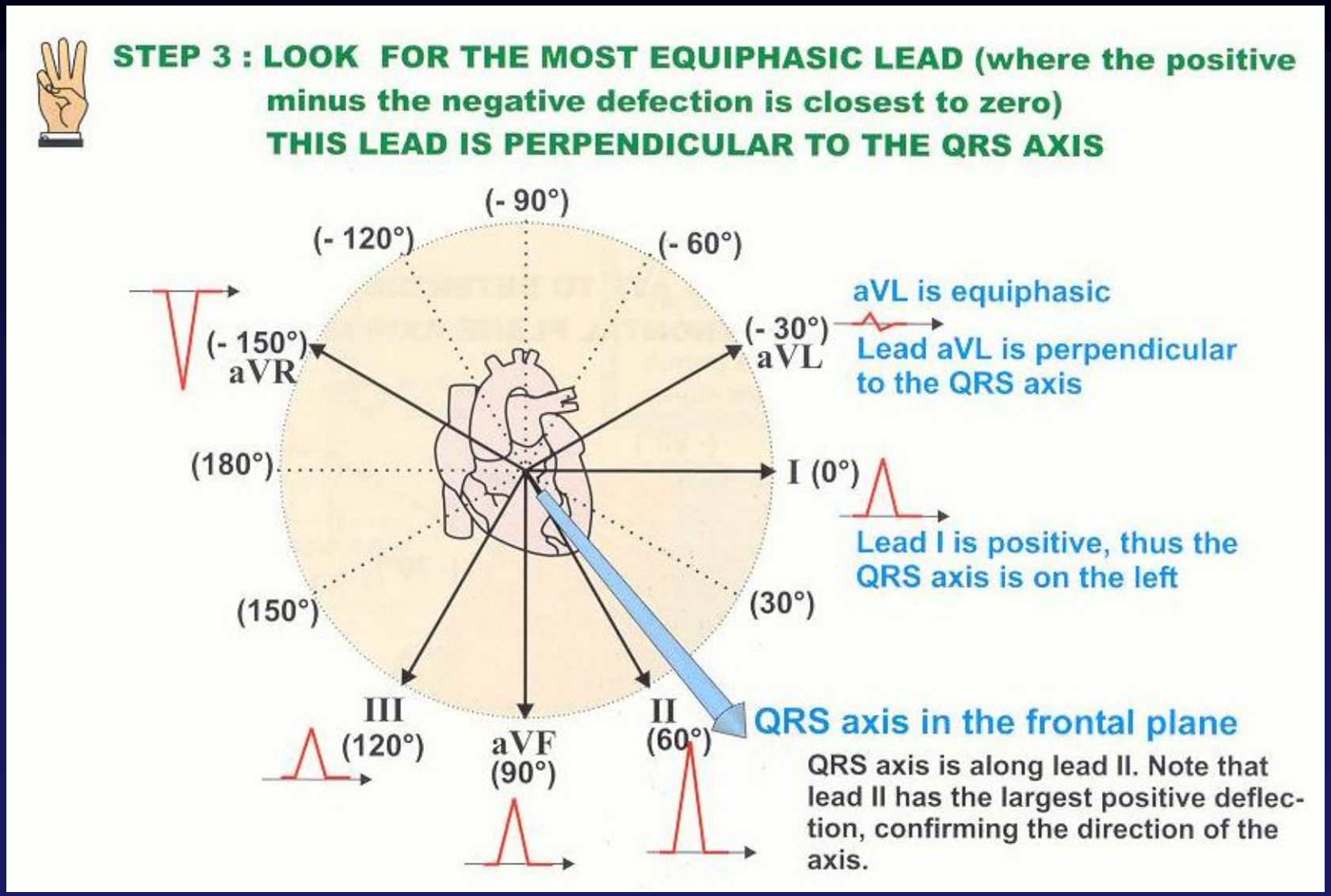

Tehran Arrhythmia Center

QRS Axis

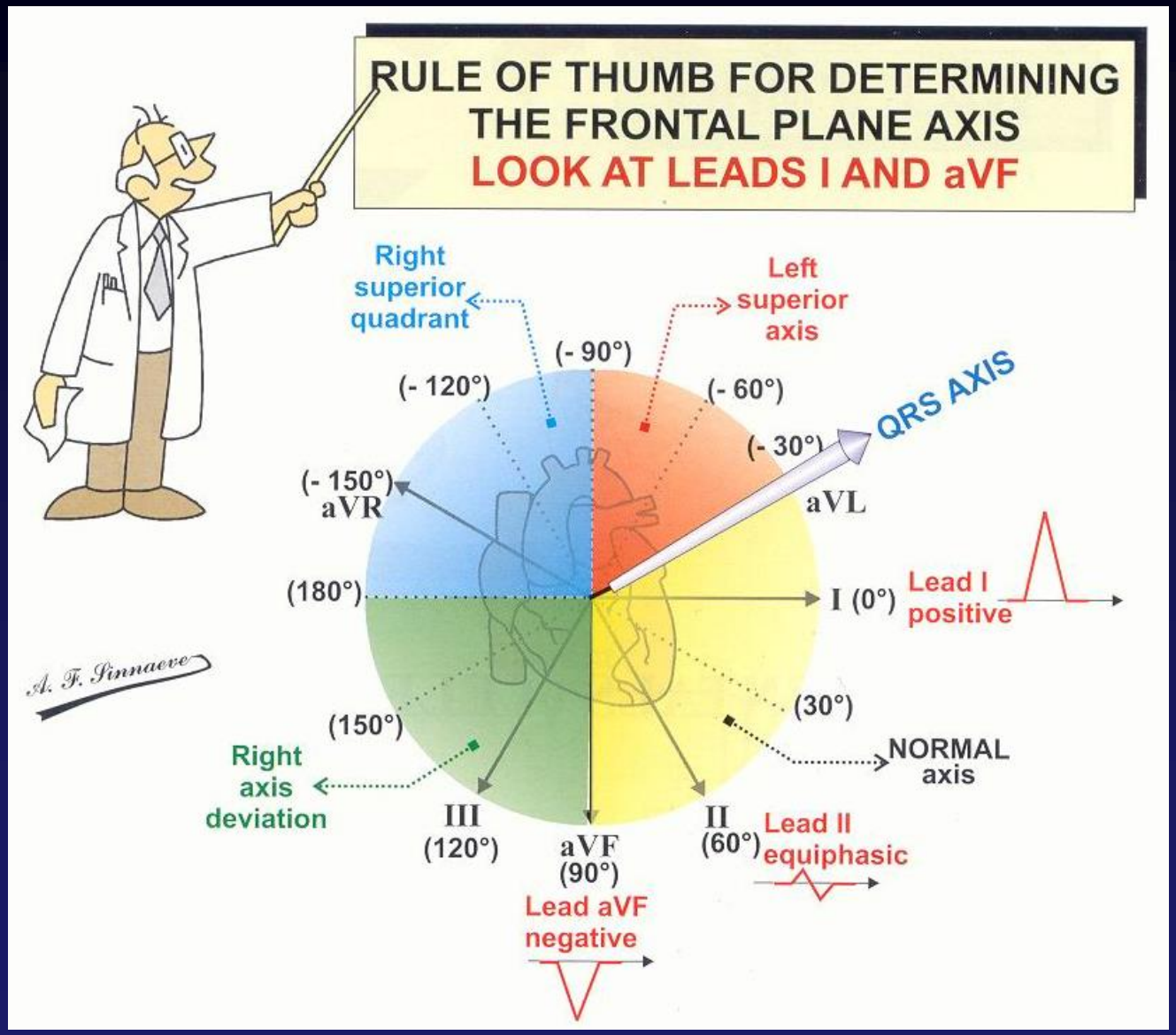

Tehran Arrhythmia Center

Normal QRS Axis

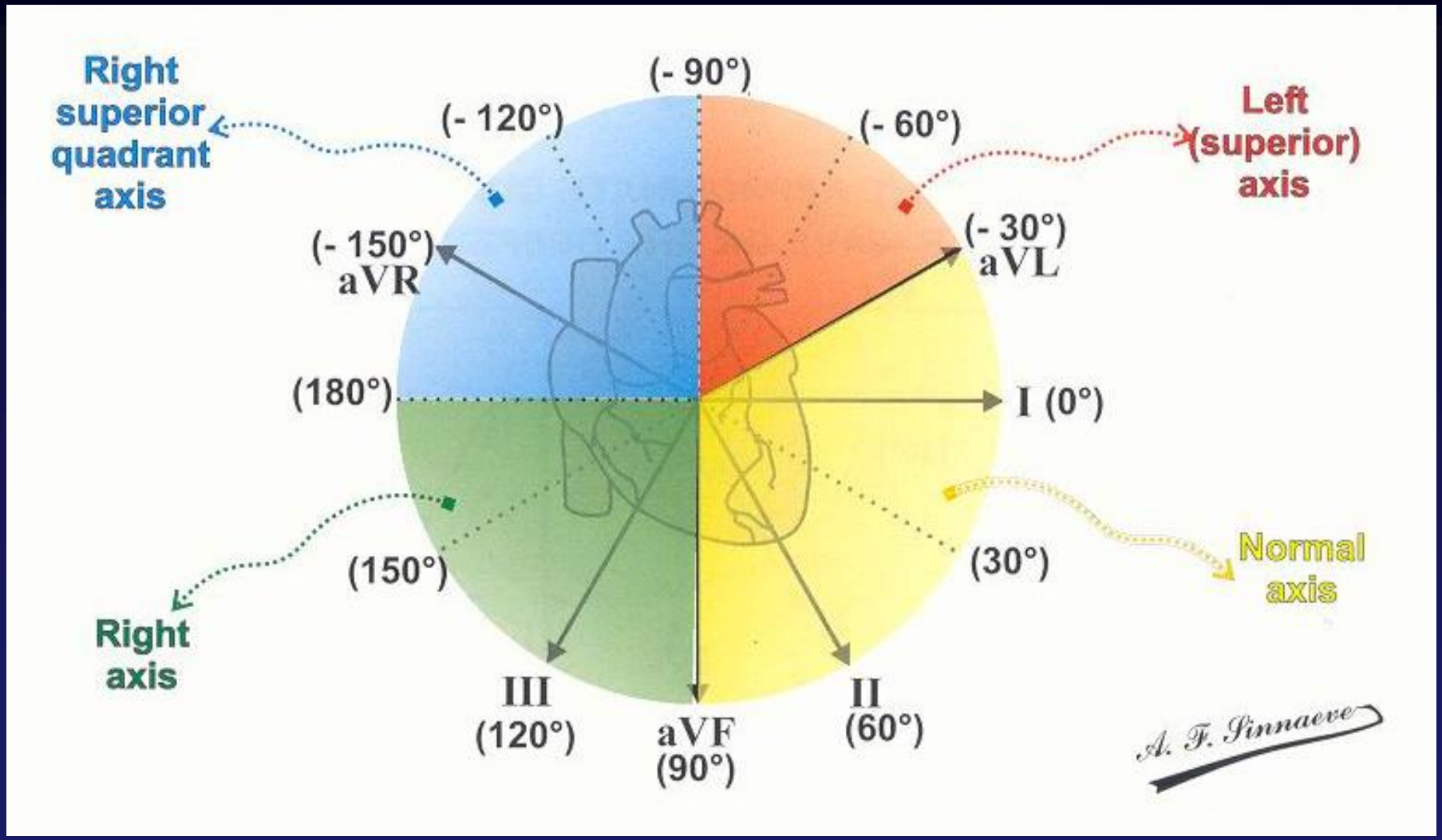

Left Axis Deviation

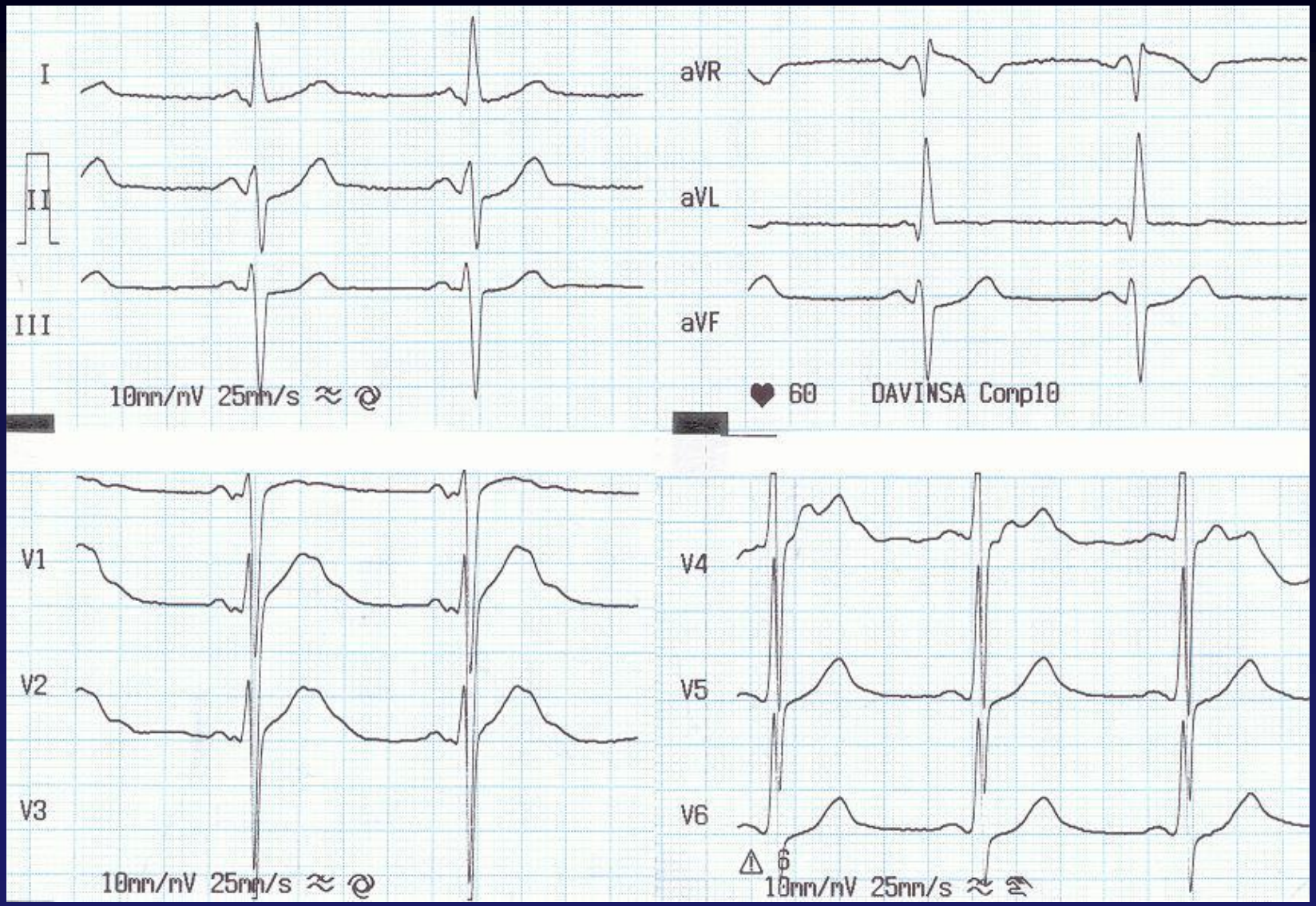

Tehran Arrhythmia Center

Right Axis Deviation

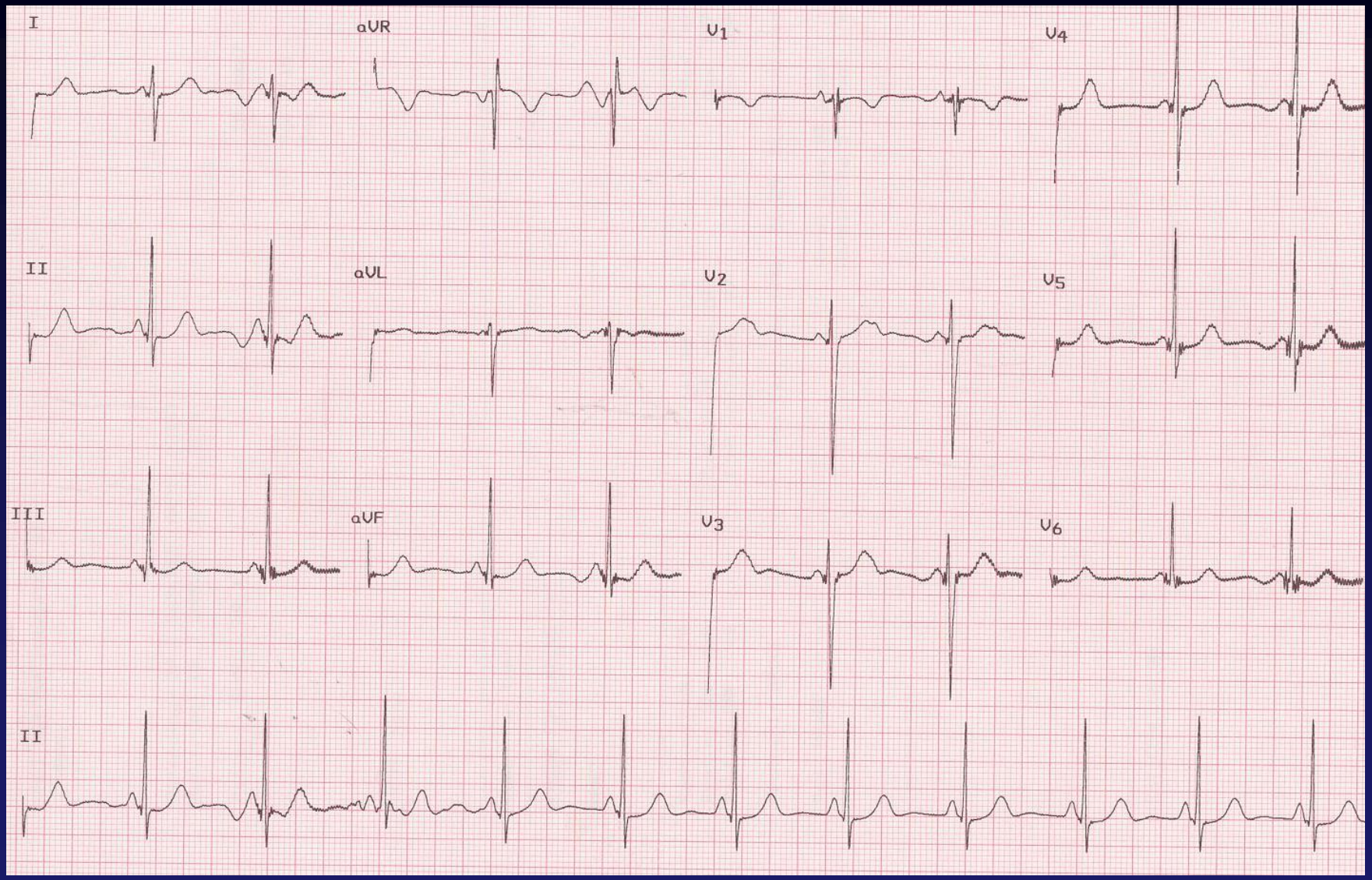

Tehran Arrhythmia Center

Sinus P Wave

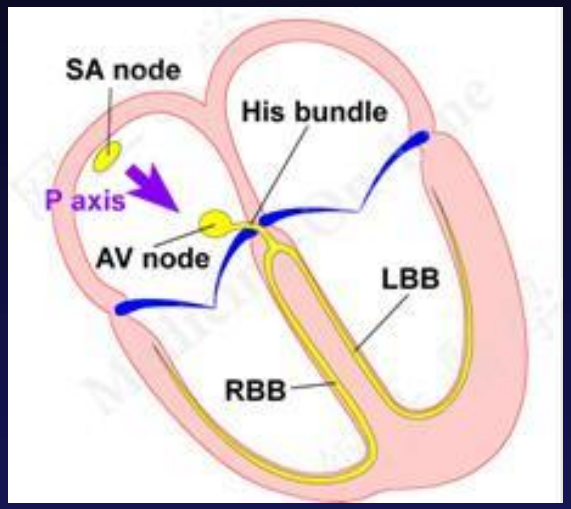

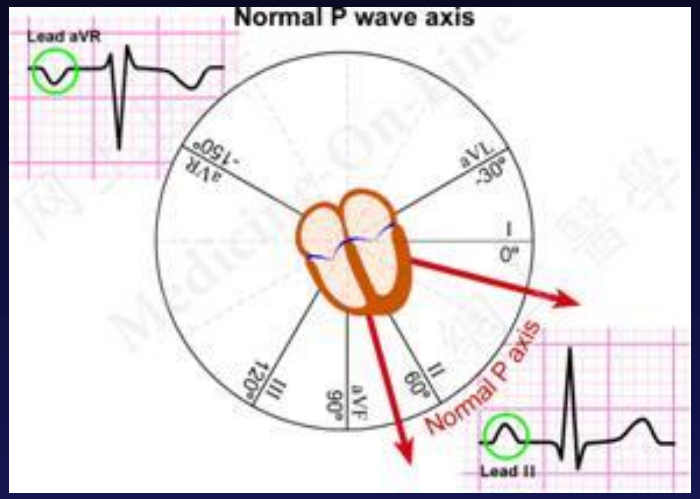

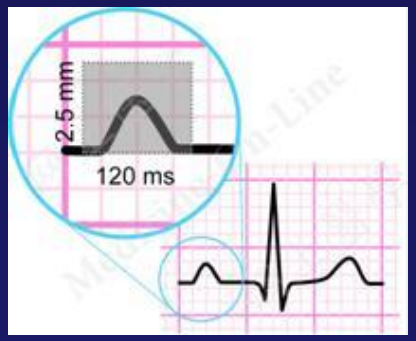

II

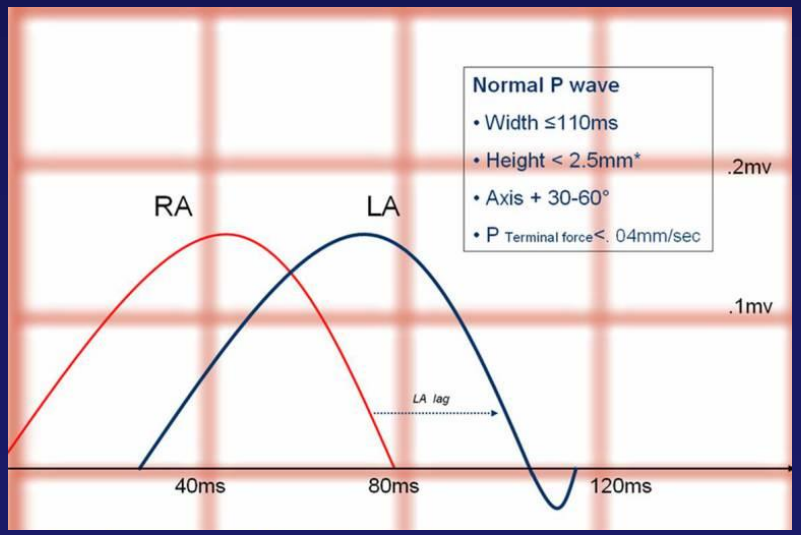

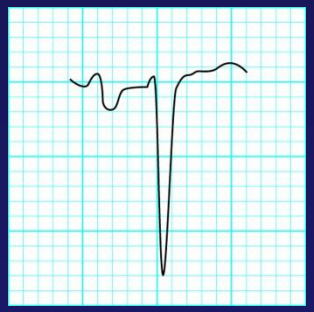

V1

Tehran Arrhythmia Center

TIMING INTERVALS VERSUS RATE

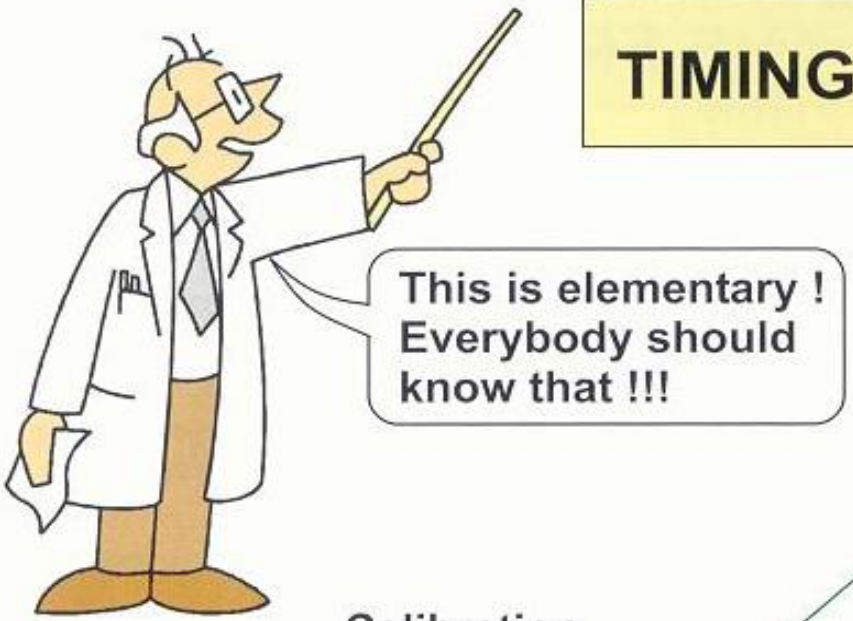

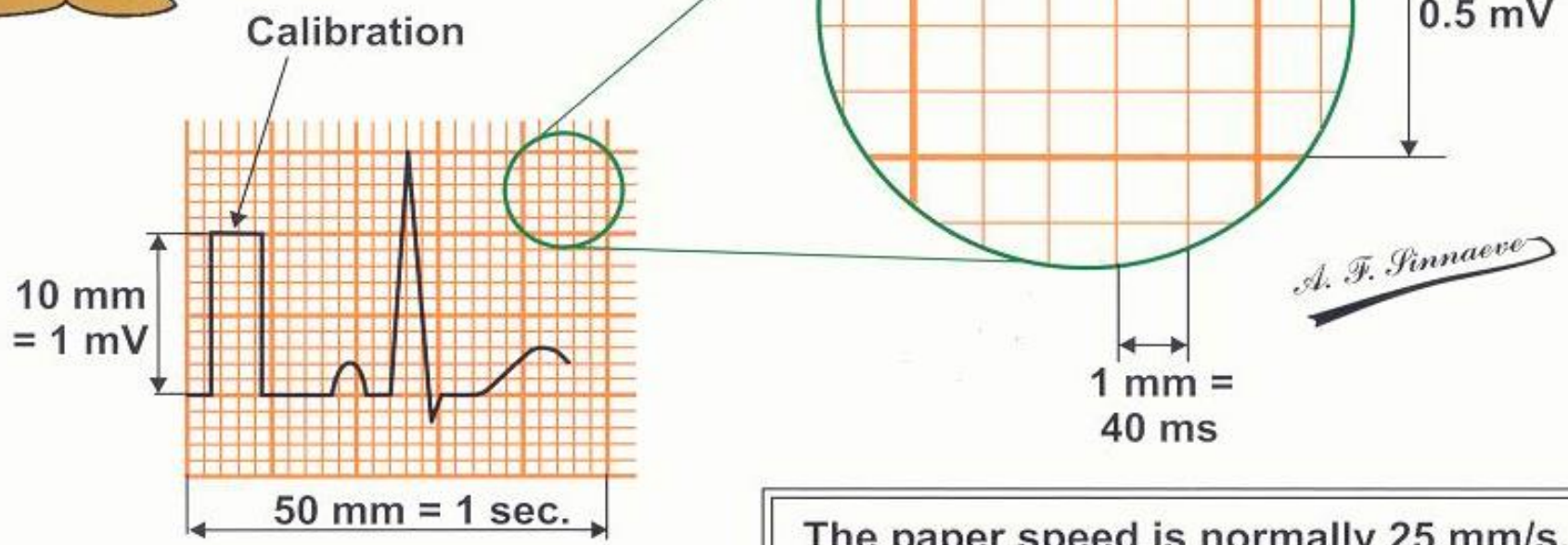

The paper speed is normally 25 mm/s, thus 1 mm on the paper corresponds with 1/25 s = 0.04 s = 40 ms

The ECG Paper

- Horizontally
  - One small box - 0.04 s
  - One large box - 0.20 s
- Vertically
  - One large box - 0.5 mV

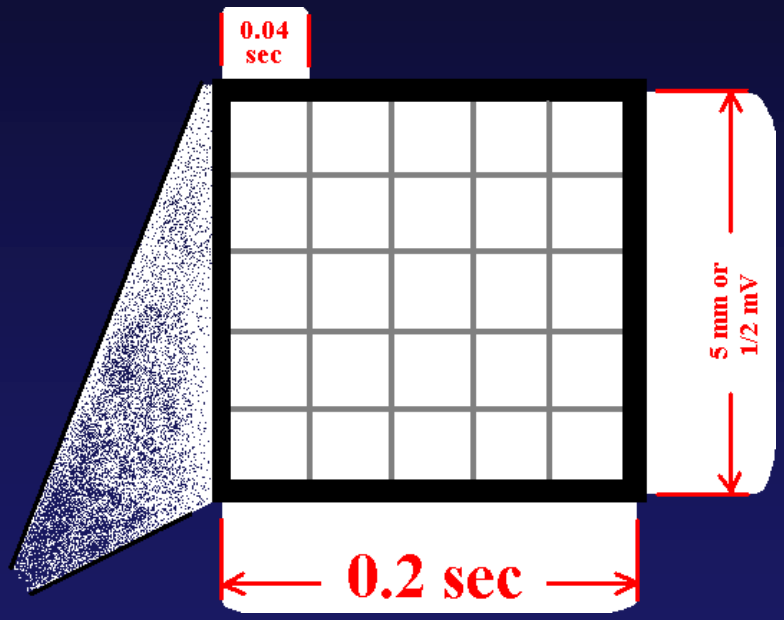

Timing in the ECG Paper

- Every 3 seconds (15 large boxes) is marked by a vertical line.
- This helps when calculating the heart rate.

Major ECG Abnormalities

Right Atrial Enlargement

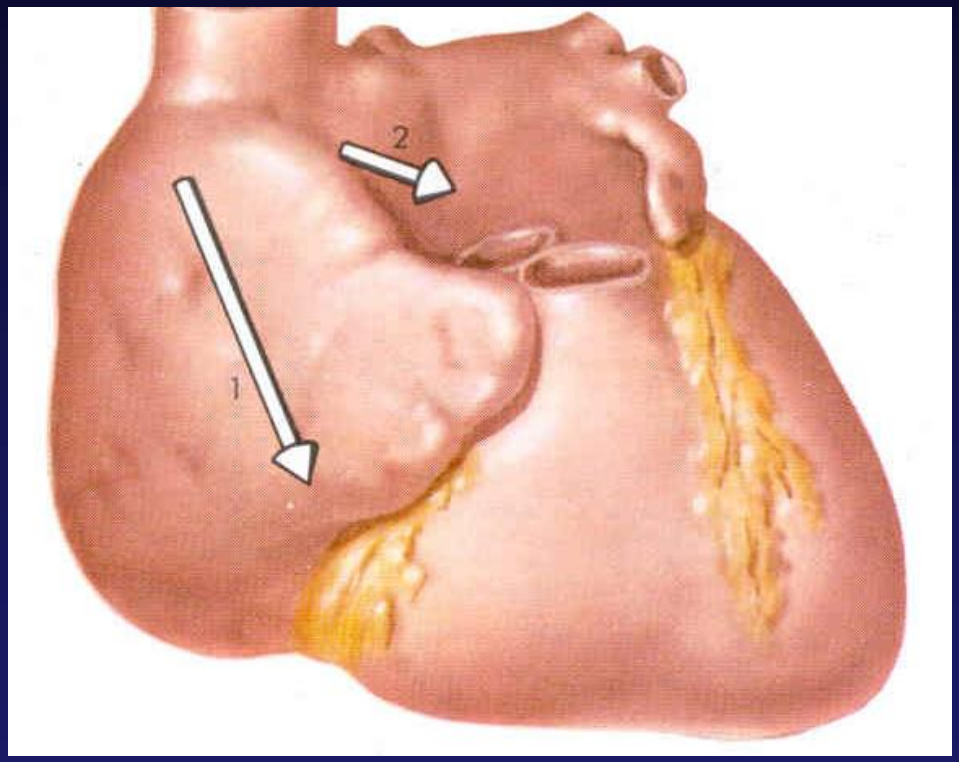

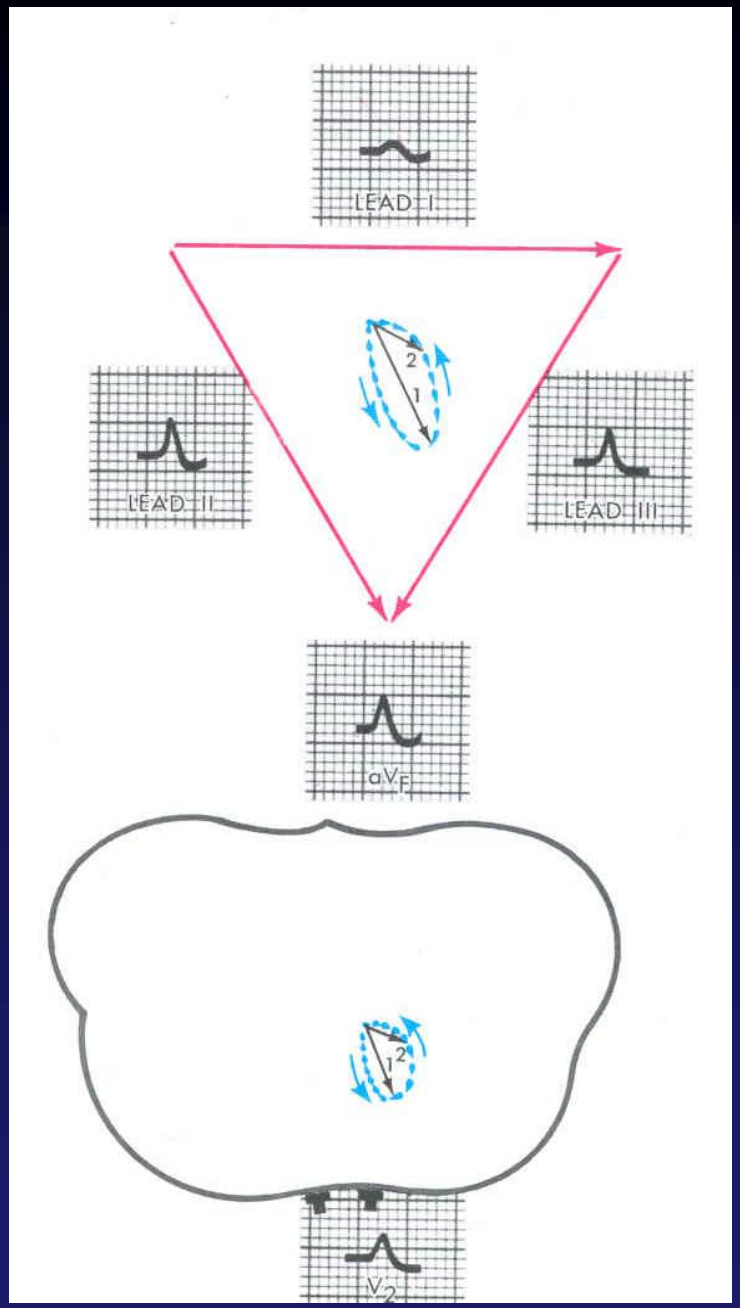

P Pulmonale, Amplitude ≥ 2.5 mm

Tehran Arrhythmia Center

Atrial Activation

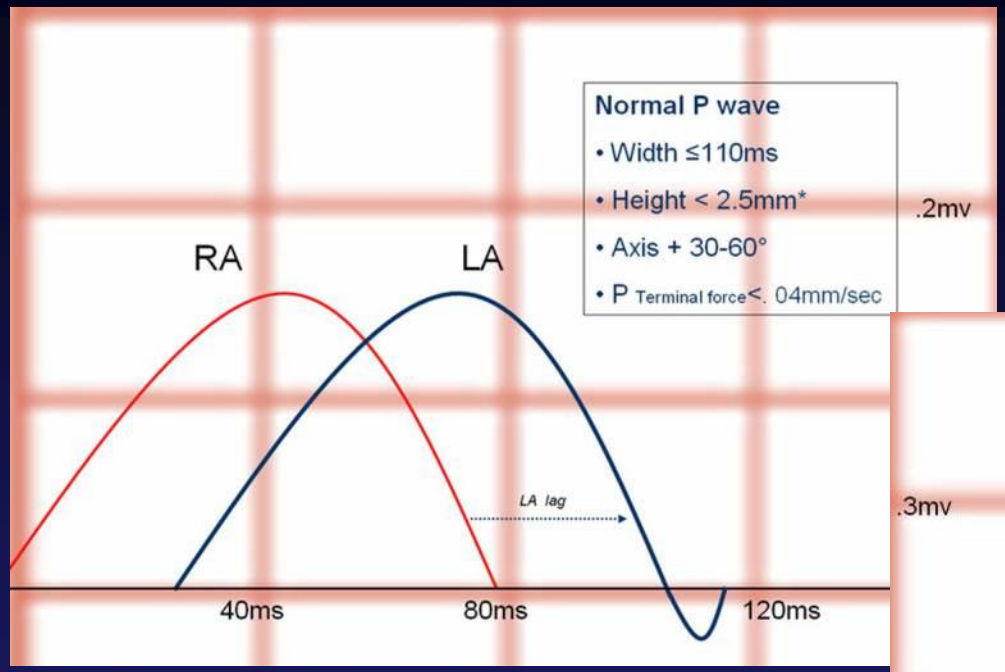

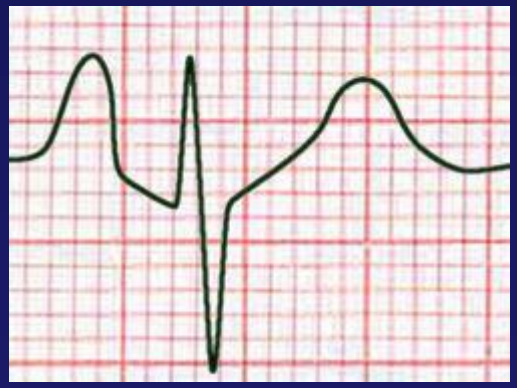

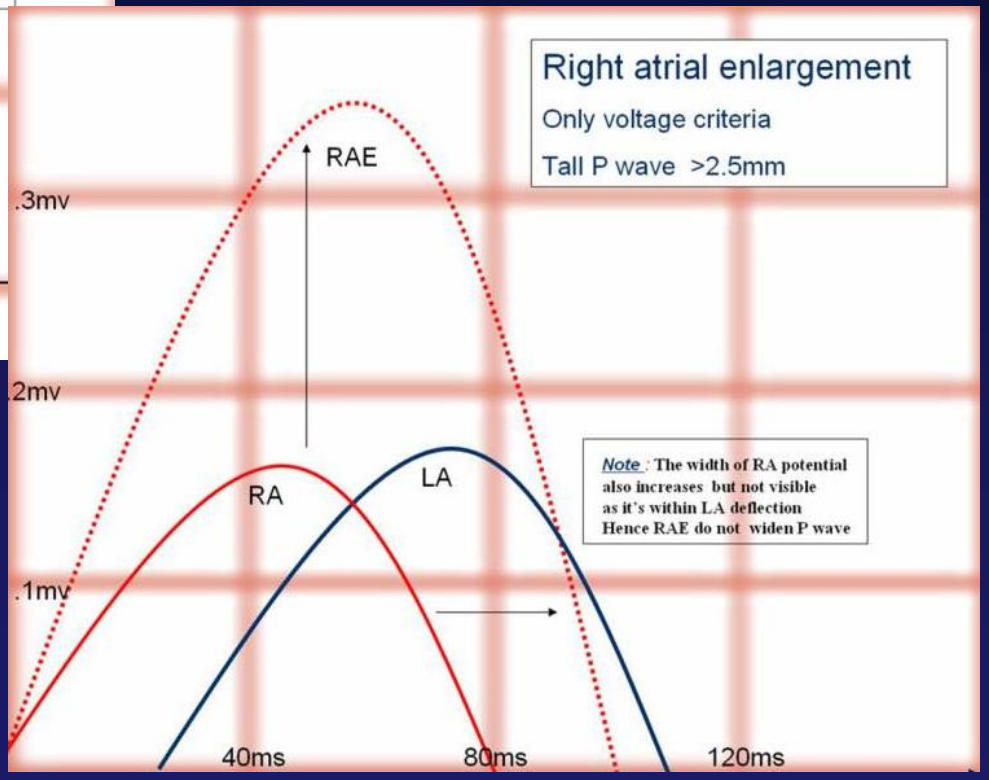

Tehran Arrhythmia Center

Right Atrial Enlargement

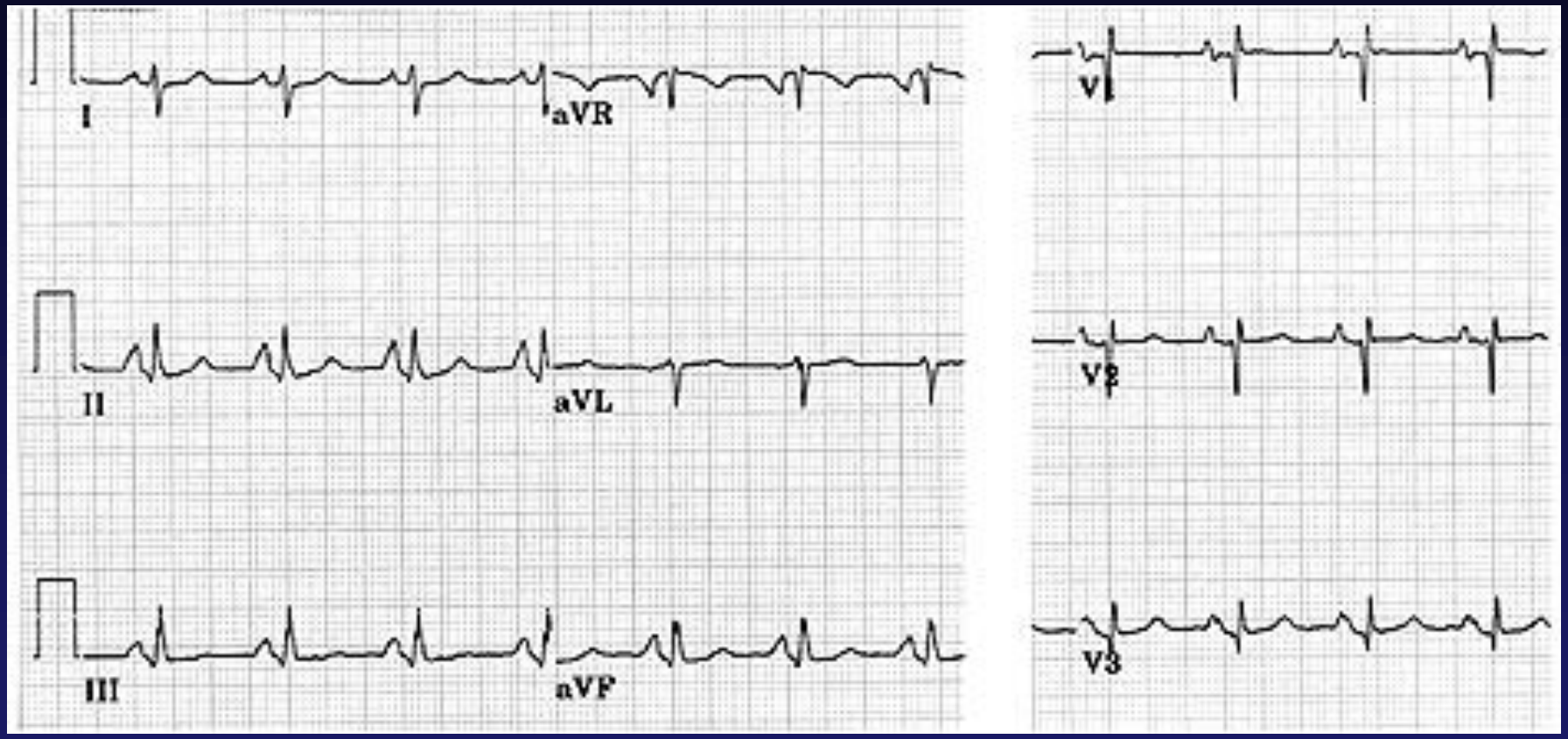

The P waves are tall, especially in leads II, III and avF.

Tehran Arrhythmia Center

Right Atrial Enlargement

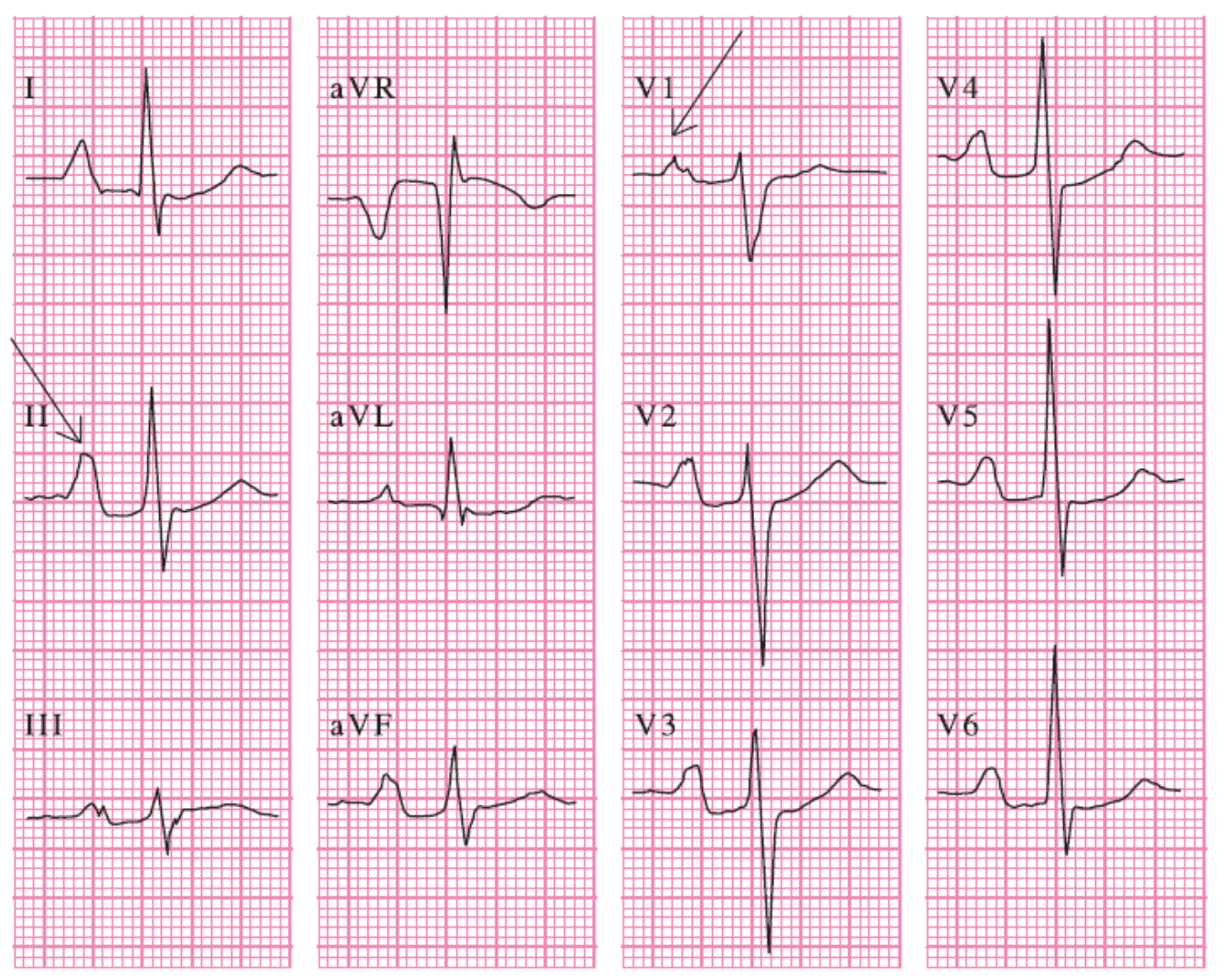

Tehran Arrhythmia Center

Right Atrial Enlargement

– To diagnose RAE you can use the following criteria:

- II P > 2.5 mm, or
- V1 or V2 P > 1.5 mm

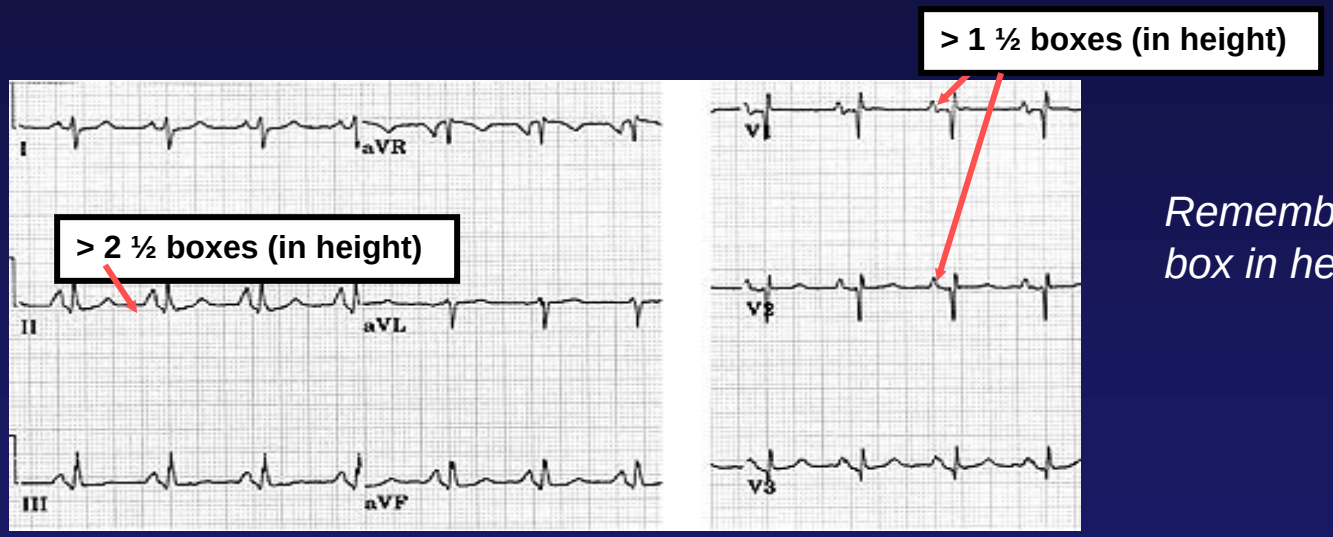

Remember 1 small box in height = 1 mm

A cause of RAE is RVH from pulmonary hypertension, hence P Pulmonale.

Left Atrial Enlargement

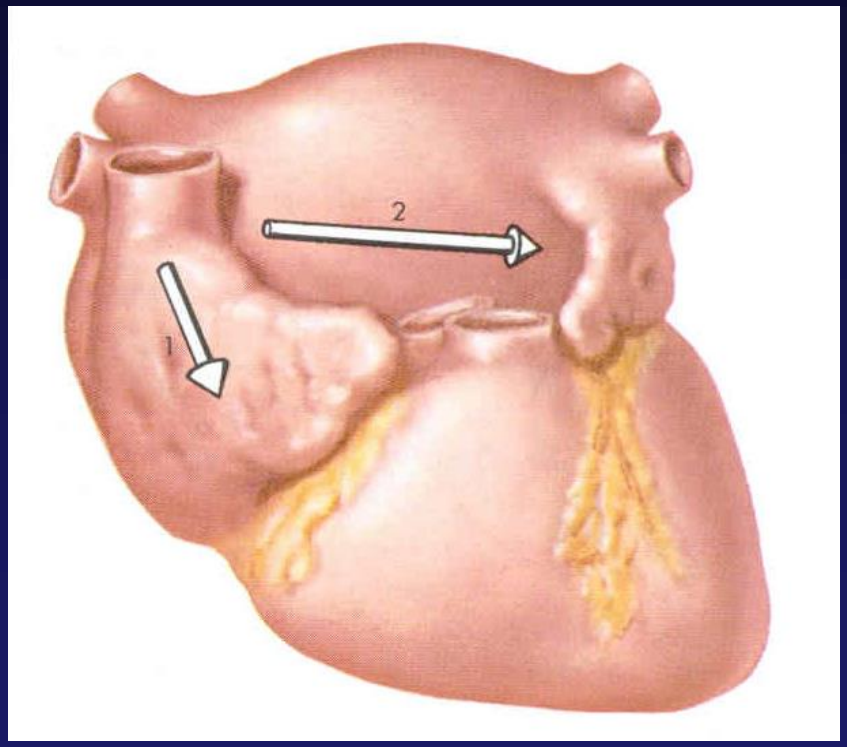

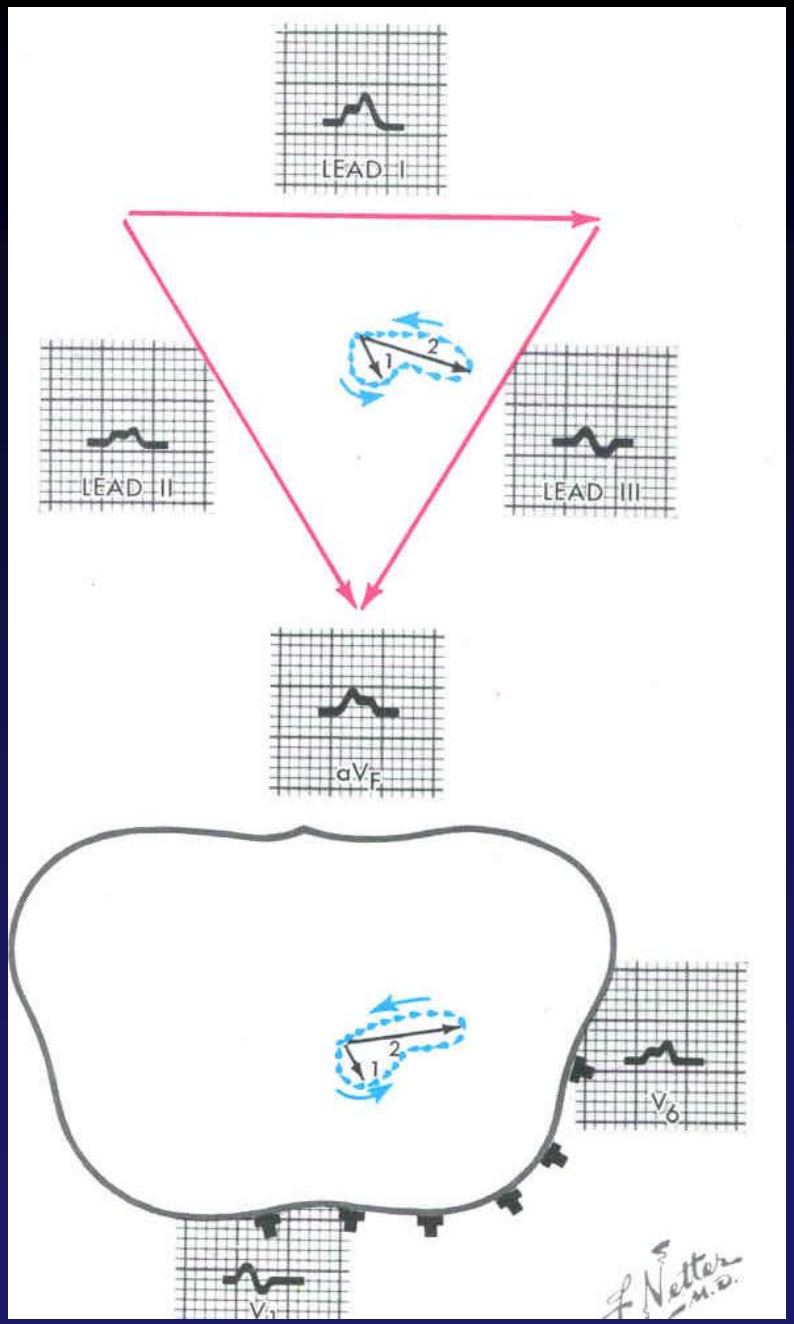

P Mitrale, Duration ≥ 120 ms

Tehran Arrhythmia Center

Atrial Activation

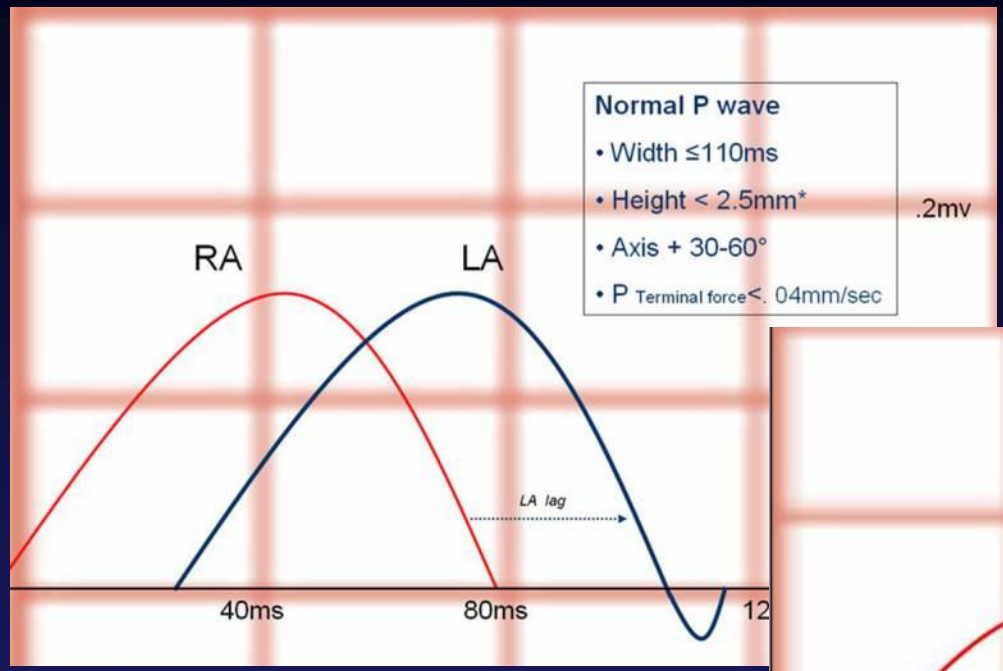

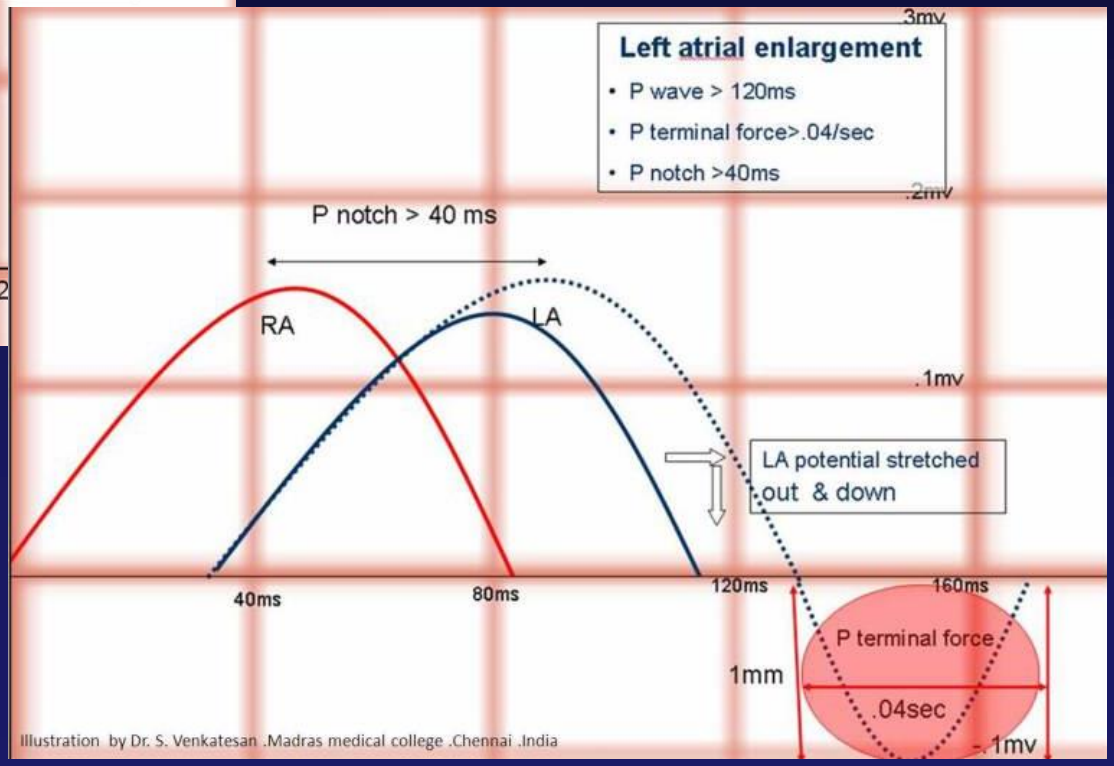

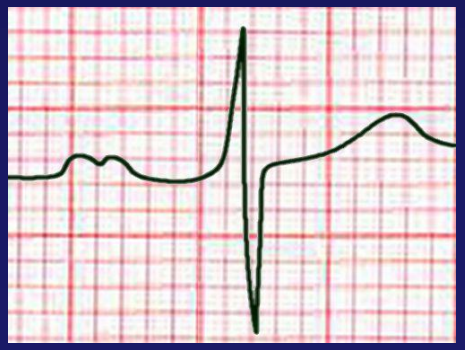

Tehran Arrhythmia Center

Left Atrial Enlargement

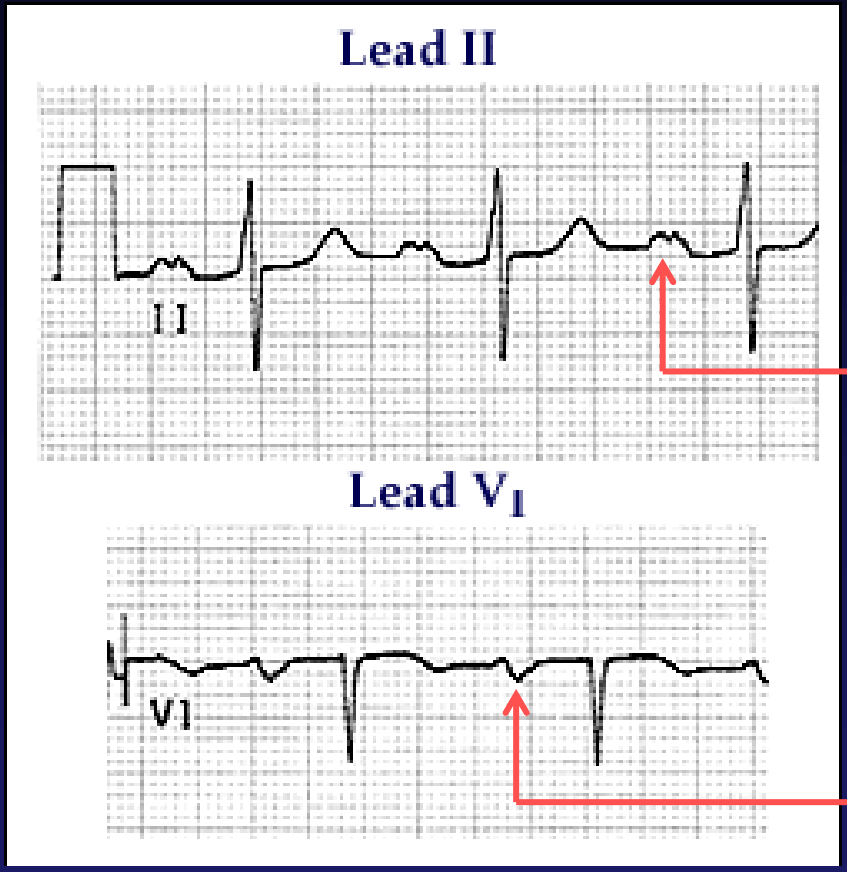

Notched

Negative deflection

The P waves in lead II are notched and in lead V1 they have a deep and wide negative component.

Left Atrial Enlargement

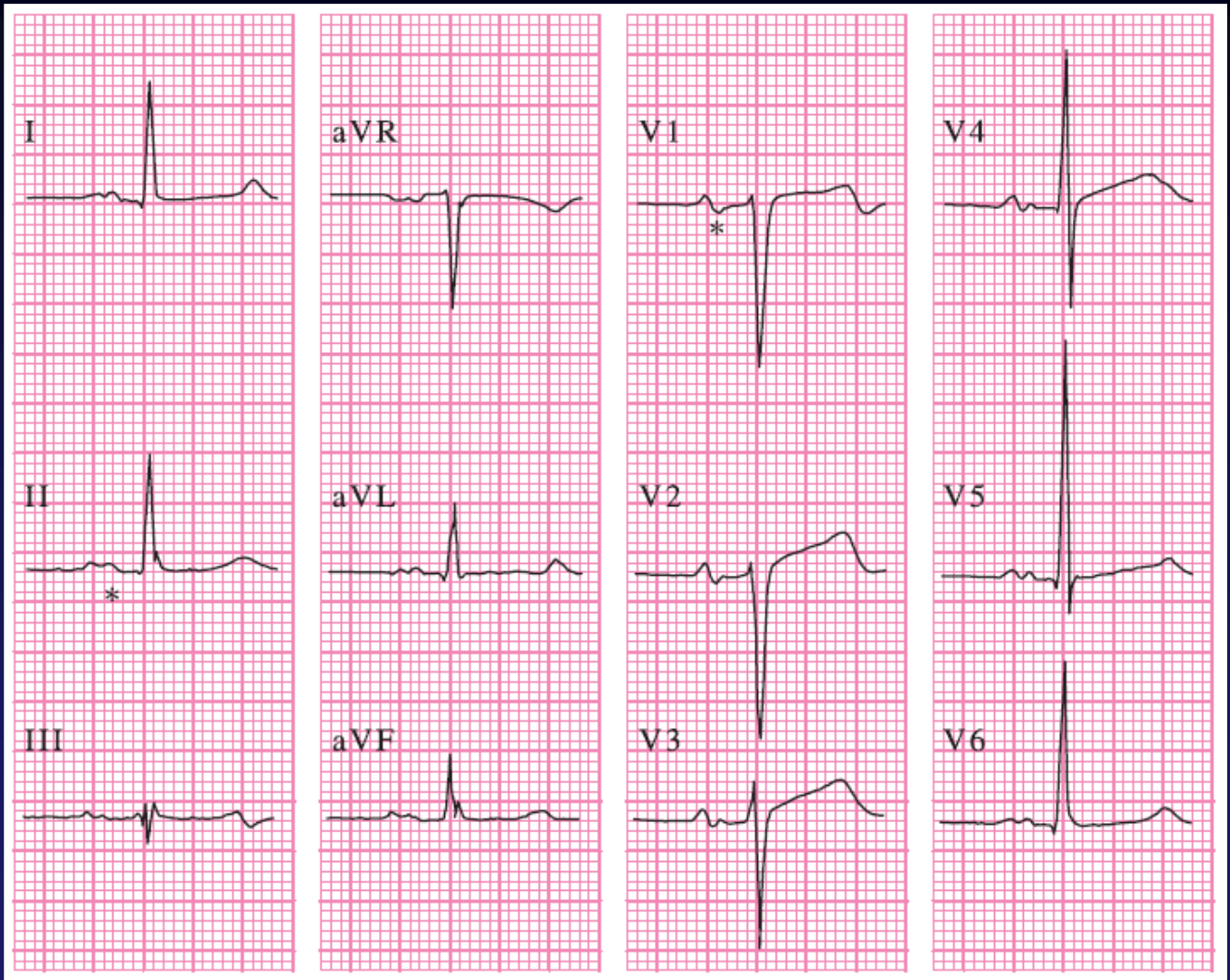

Tehran Arrhythmia Center

Left Atrial Enlargement

– To diagnose LAE you can use the following criteria:

- II > 0.04 s (1 box) between notched peaks, or
- V1 Neg. deflection > 1 box wide x 1 box deep

Normal

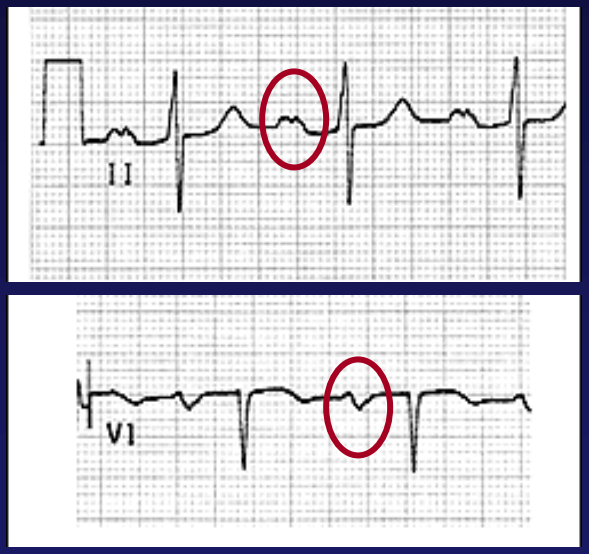

LAE

A common cause of LAE has been Mitral Stenosis, hence P Mitrale.

Bi-atrial Enlargement

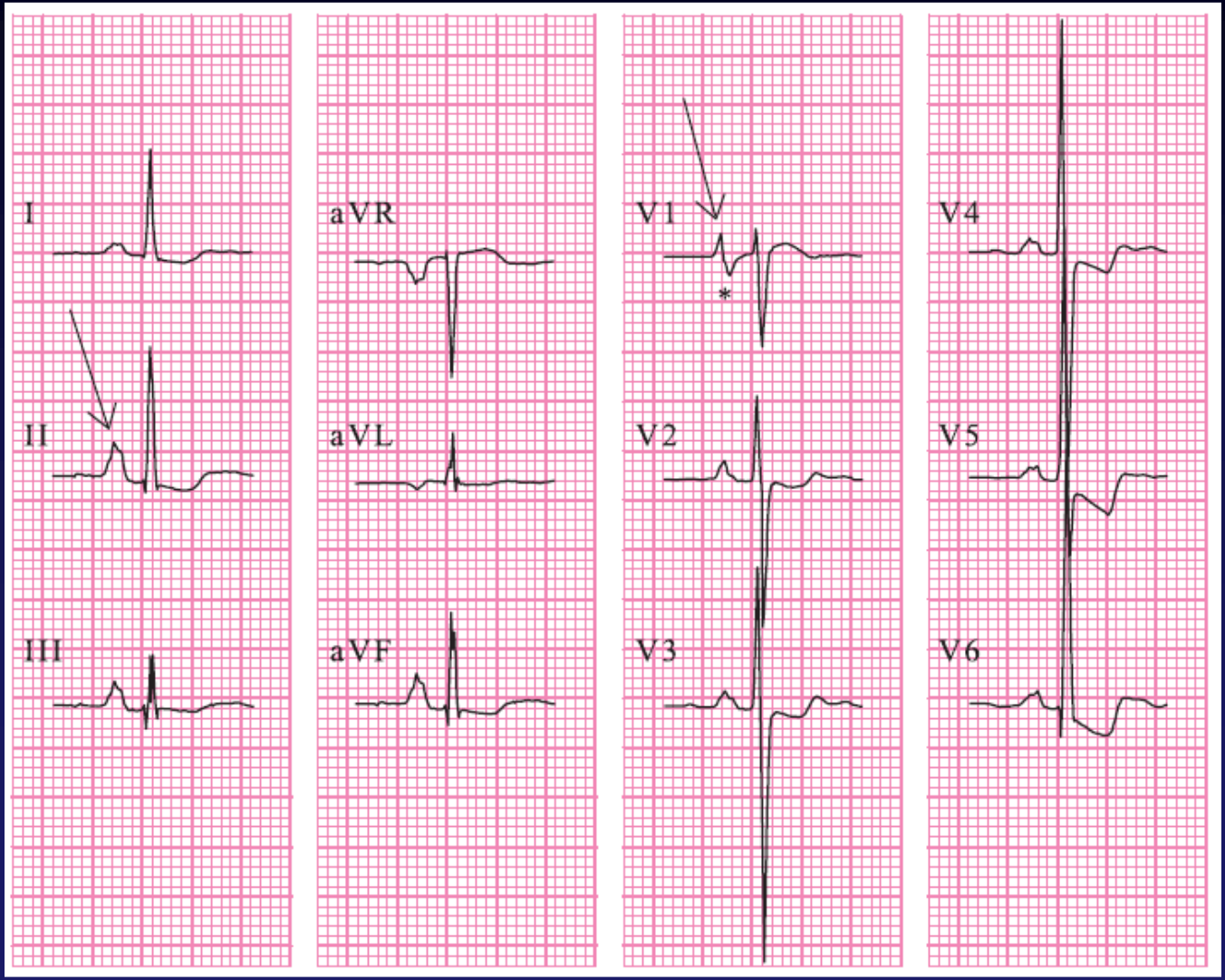

Tehran Arrhythmia Center

Left Ventricular Hypertrophy

Why is left ventricular hypertrophy characterized by tall QRS complexes?

As the heart muscle wall thickens there is an increase in electrical forces moving through the myocardium resulting in increased QRS voltage.

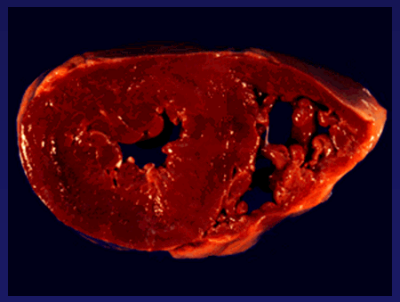

LVH

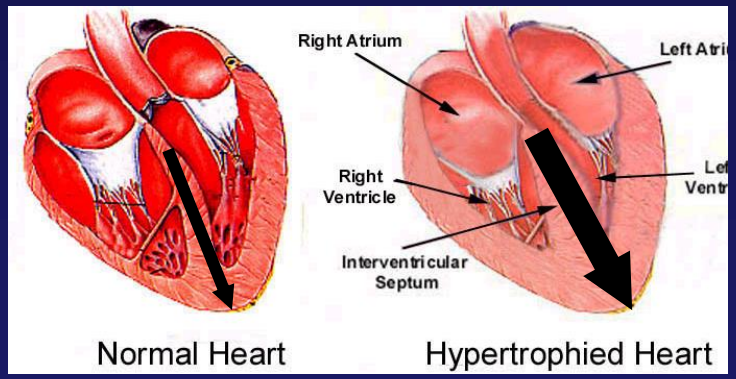

Increased QRS voltage

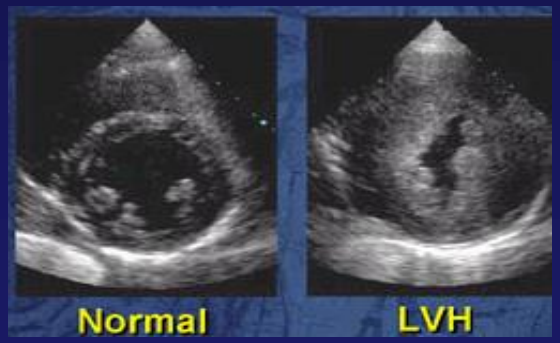

Echocardiogram

Left Ventricular Hypertrophy

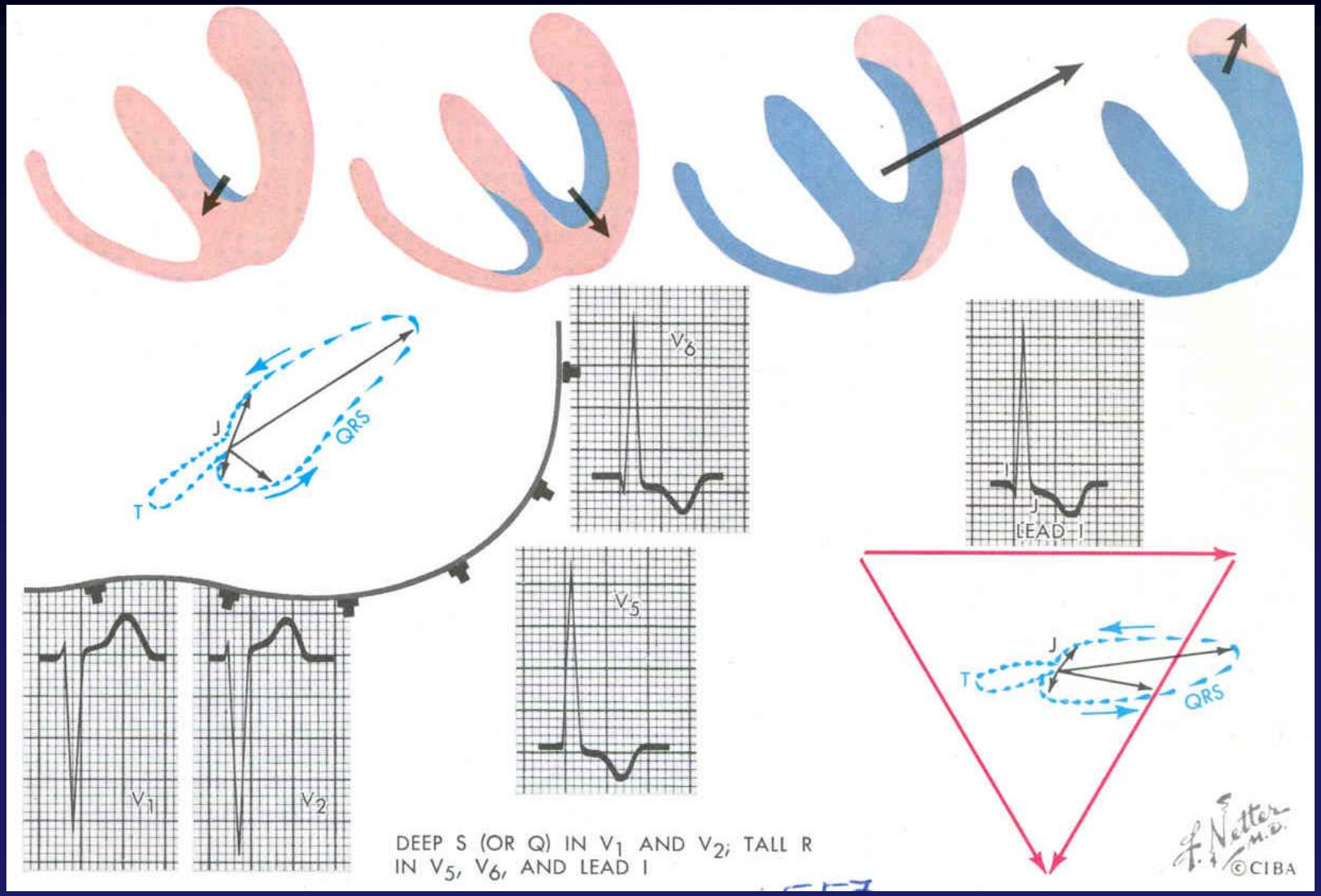

Tehran Arrhythmia Center

Left Ventricular Hypertrophy

Compare these two 12-lead ECGs. What stands out as different with the second one?

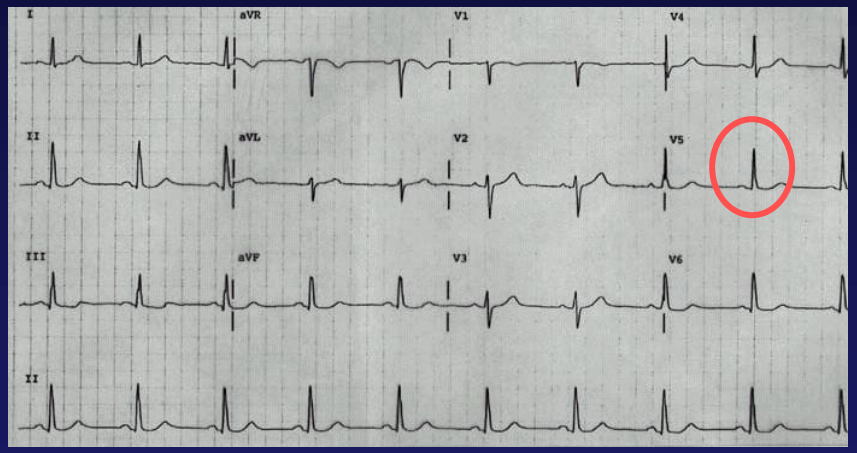

Normal

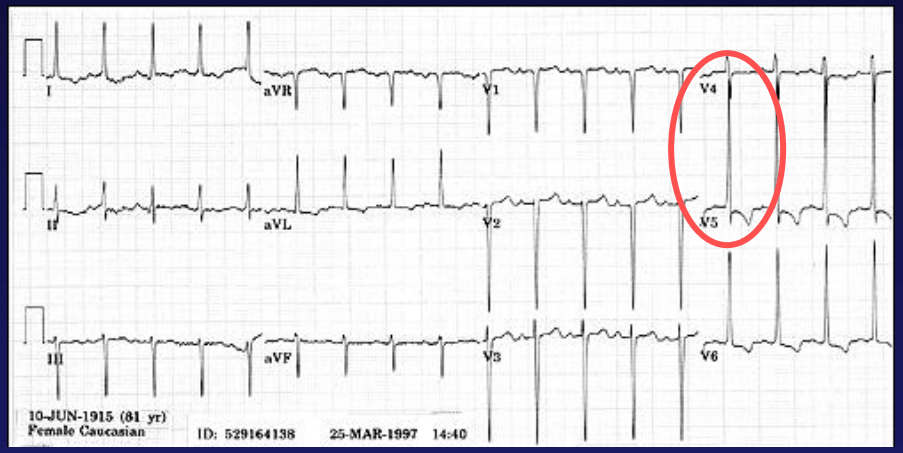

Left Ventricular Hypertrophy

Answer: The QRS complexes are very tall (increased voltage)

Tehran Arrhythmia Center

Left Ventricular Hypertrophy

- Criteria exists to diagnose LVH using a 12-lead ECG.
  - For example:
    - The R wave in V5 or V6 plus the S wave in V1 or V2 exceeds 35 mm.

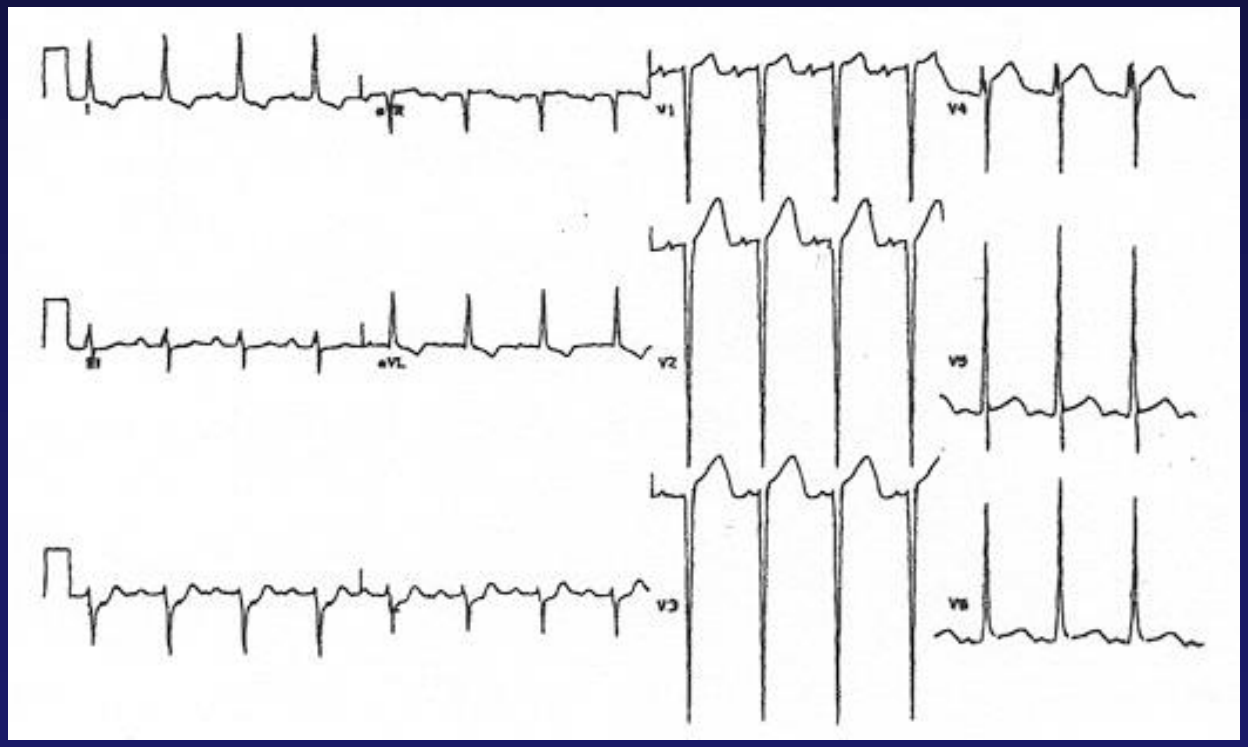

Tehran Arrhythmia Center

LVH

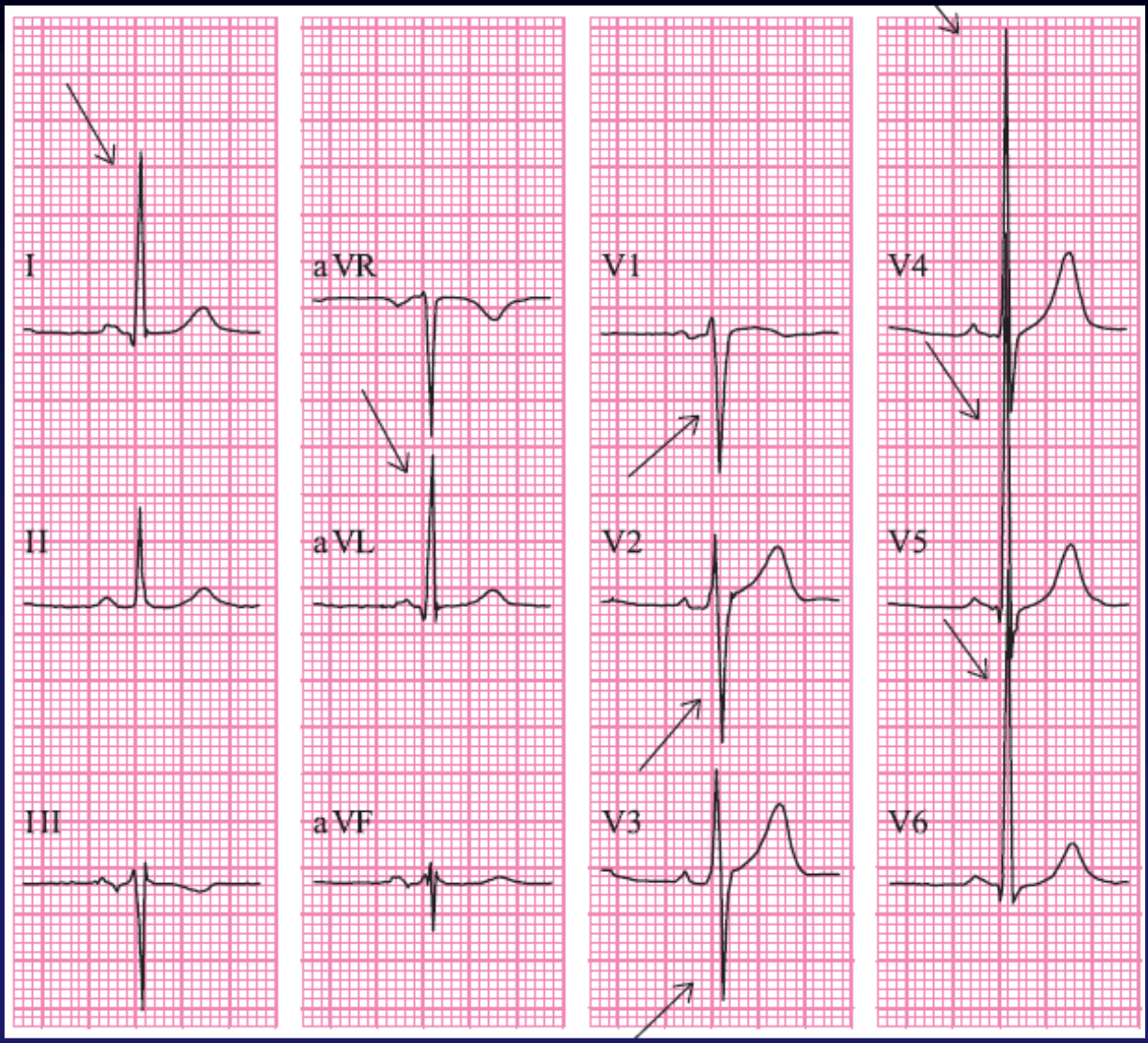

Tehran Arrhythmia Center

LVH, Severe

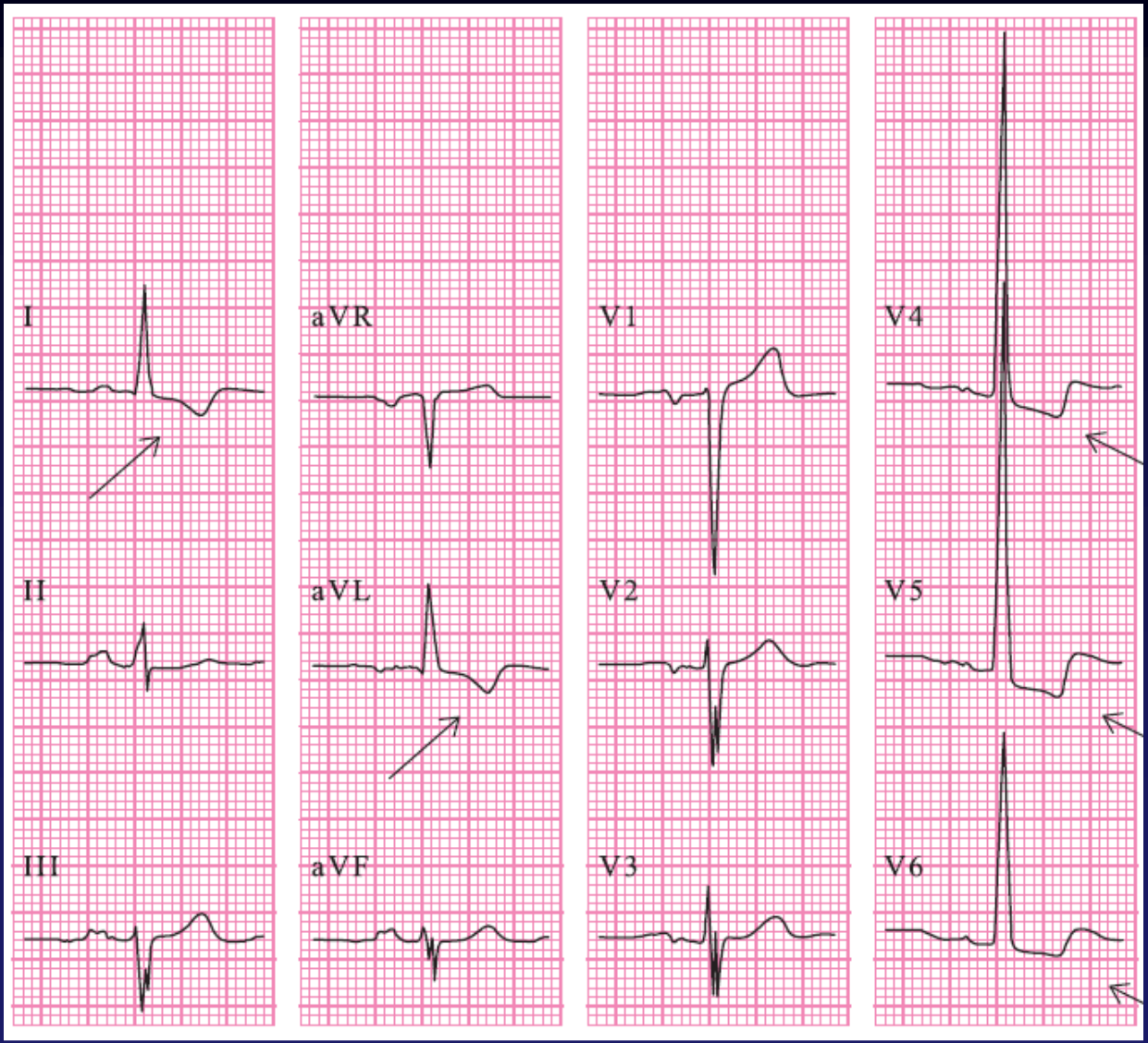

Tehran Arrhythmia Center

LVH Scoring System

Romhilt–Estes Scoring System for Left-Ventricular Hypertrophy[a]

	Points
1. R or S wave in any limb ≥2 mV	3
or S in lead V1 or V2	
or R in lead V5 or V6 ≥3 mV	
2. Left-ventricular strain	
ST segment and T wave in opposite direction to QRS complex	
without digitalis	3
with digitalis	1
3. Left-atrial enlargement	
Terminal negativity of the P wave in lead V1 is ≥0.10 mV in depth and ≥0.04 s in duration	3
4. Left-axis deviation ≥−30 degrees	2
5. QRS duration ≥0.09 s	1
6. Intrinsicoid detection in lead V5 or V6 ≥0.05 s	1
Maximally attainable	13

Right Ventricular Hypertrophy

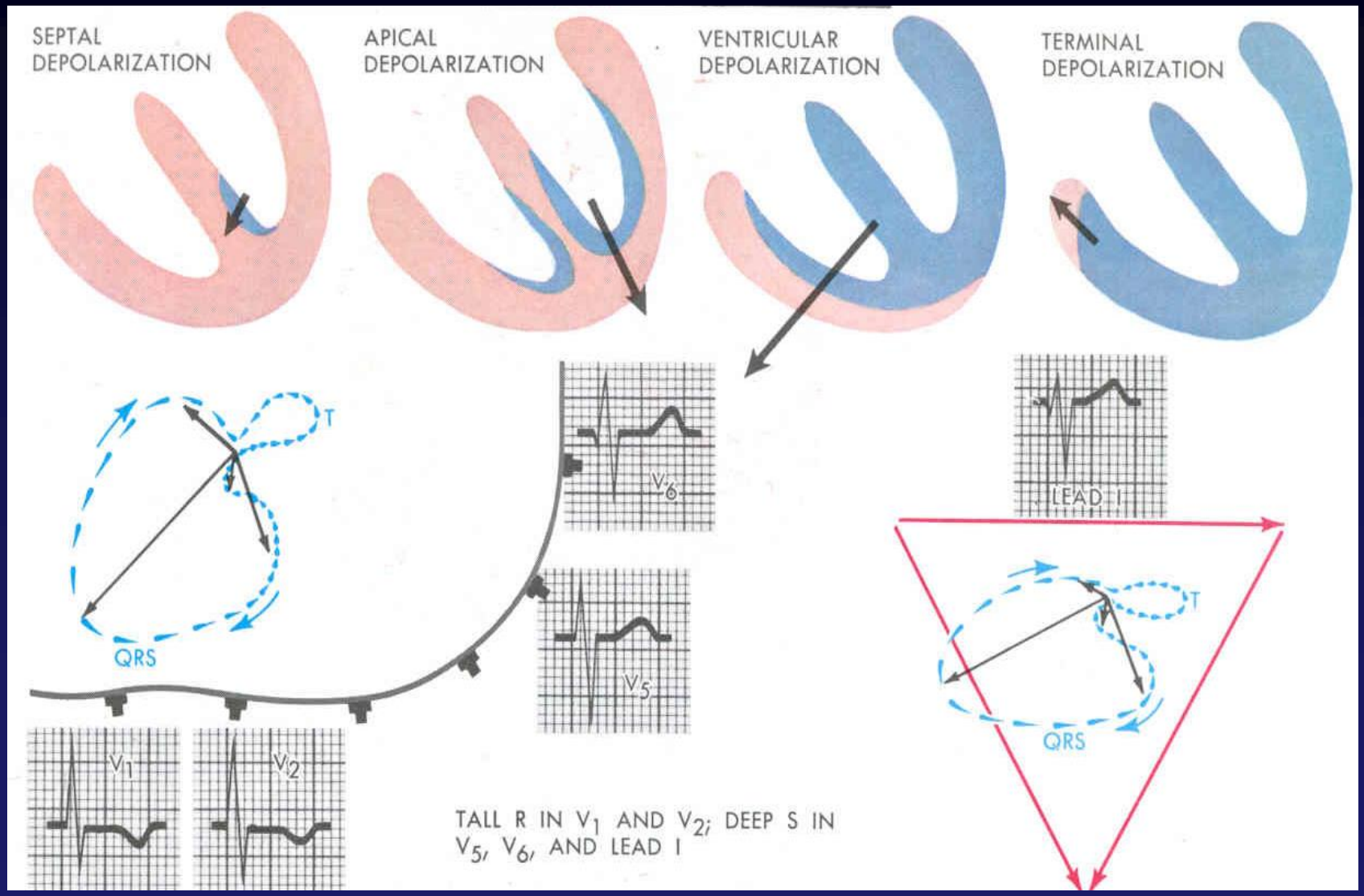

Tehran Arrhythmia Center

Right Ventricular Hypertrophy

- Compare the R waves in V1, V2 from a normal ECG and one from a person with RVH.
- Notice the R wave is normally small in V1, V2 because the right ventricle does not have a lot of muscle mass.
- But in the hypertrophied right ventricle the R wave is tall in V1, V2.

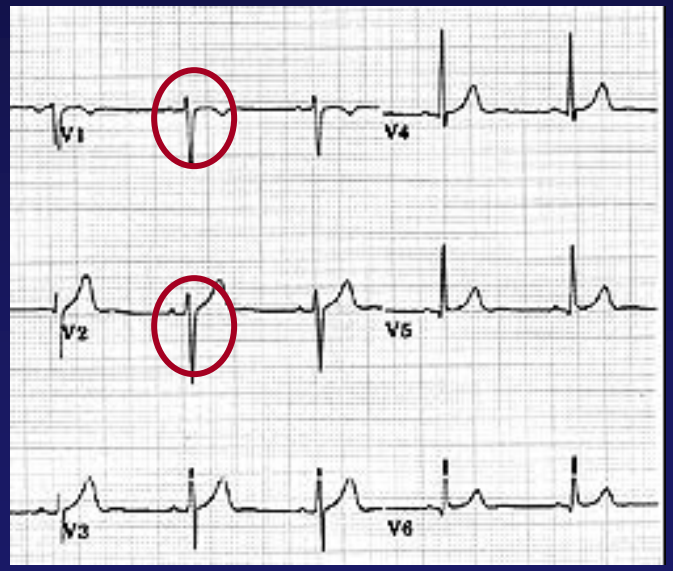

Normal

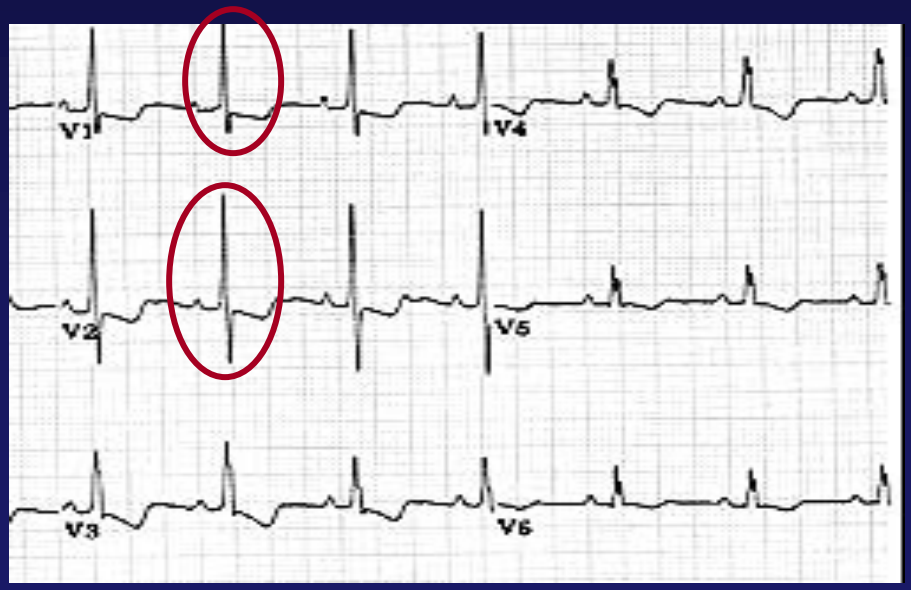

RVH

Tehran Arrhythmia Center

RVH, Mild

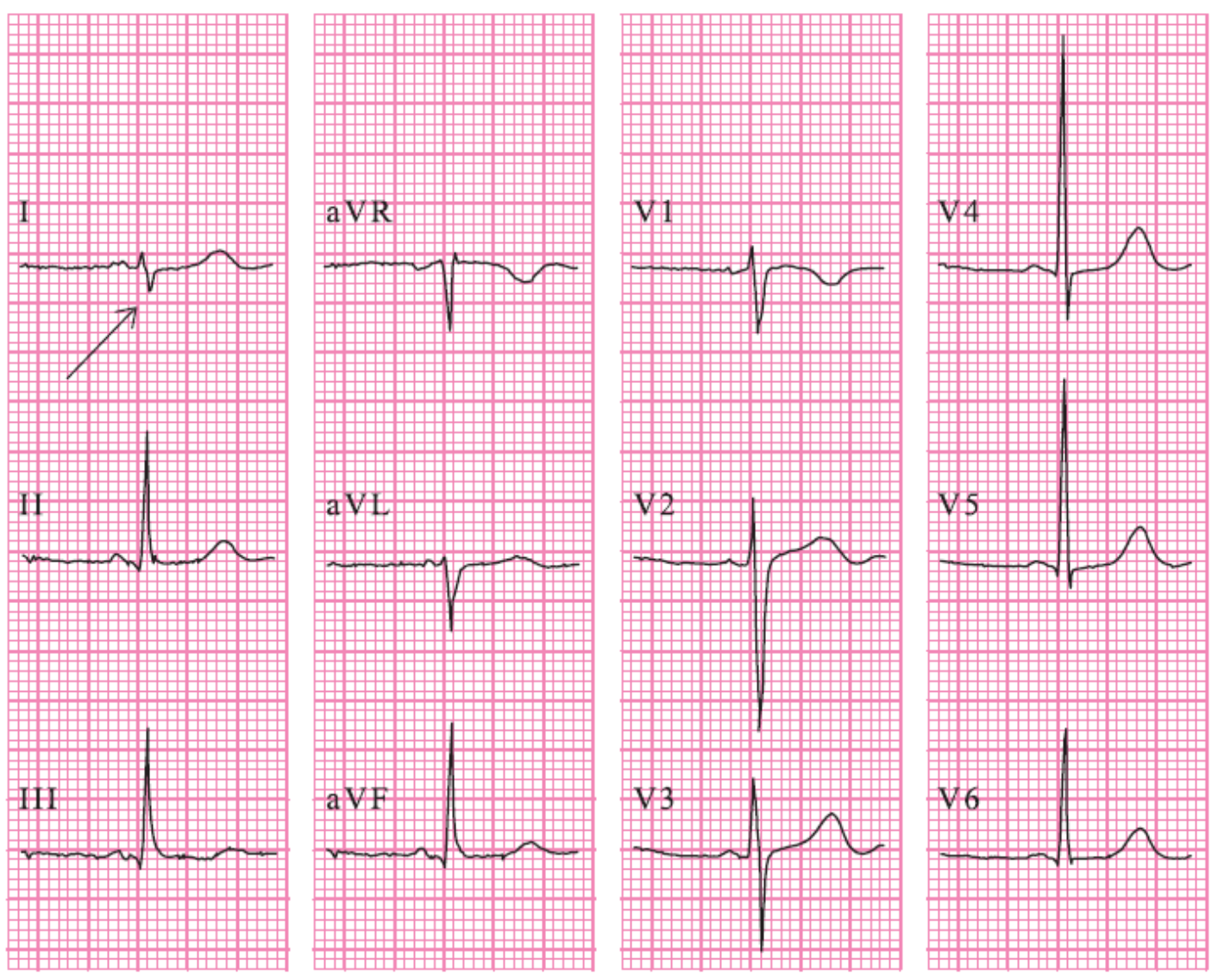

Tehran Arrhythmia Center

RVH, Moderate

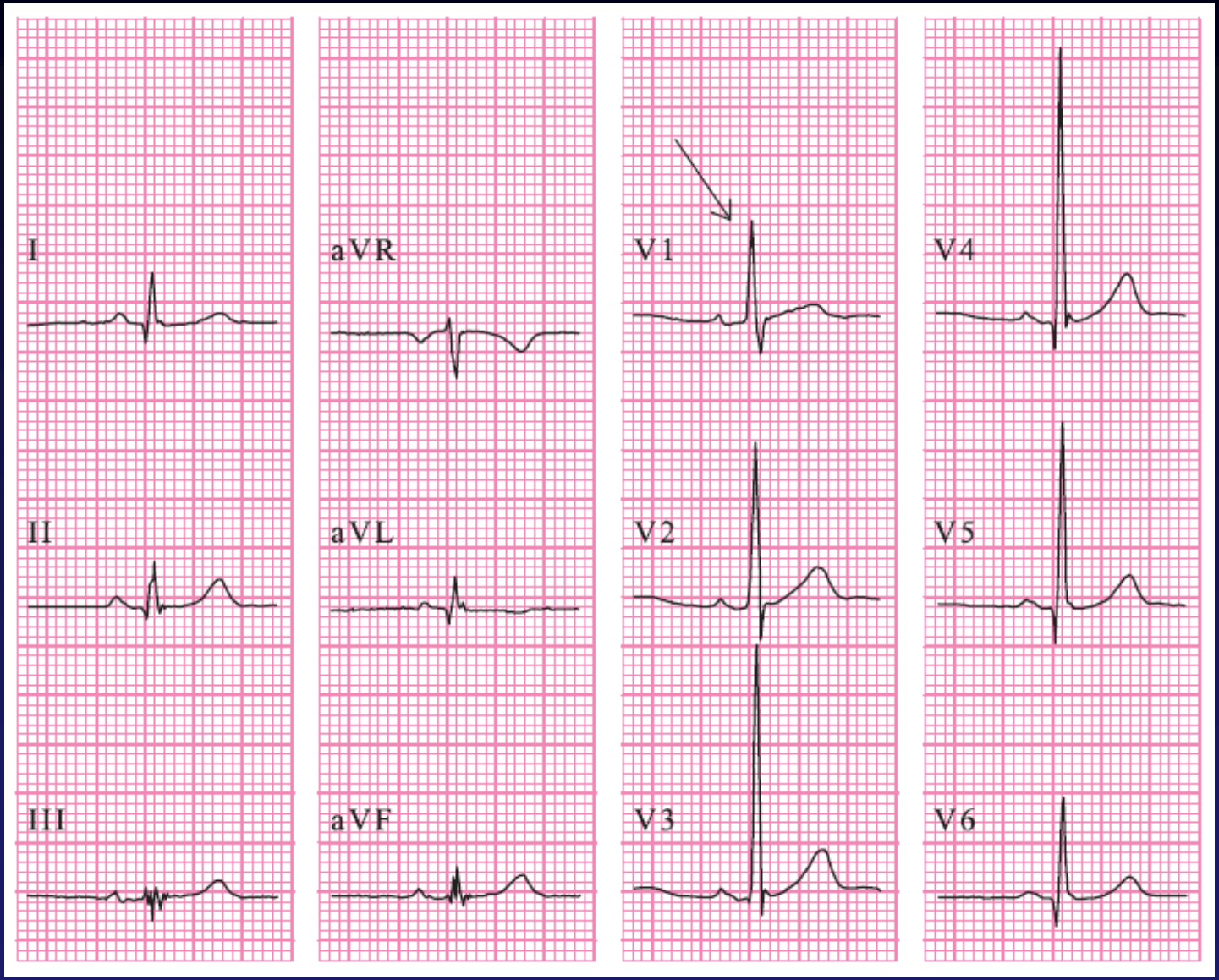

Tehran Arrhythmia Center

RVH, Severe

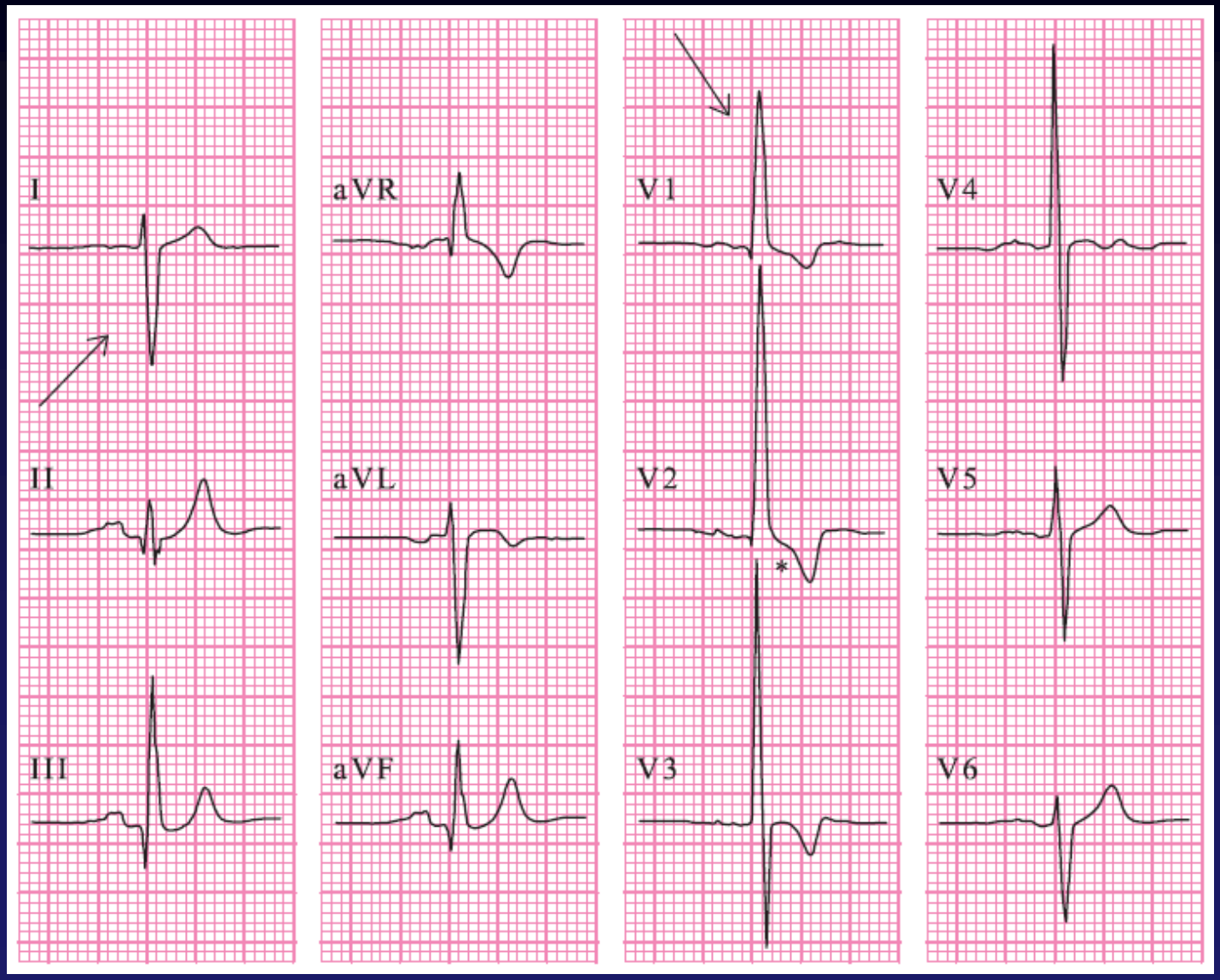

Tehran Arrhythmia Center

Right Ventricular Hypertrophy

To diagnose RVH you can use the following criteria:

- Right axis deviation, and
- V1 R wave > 7mm tall

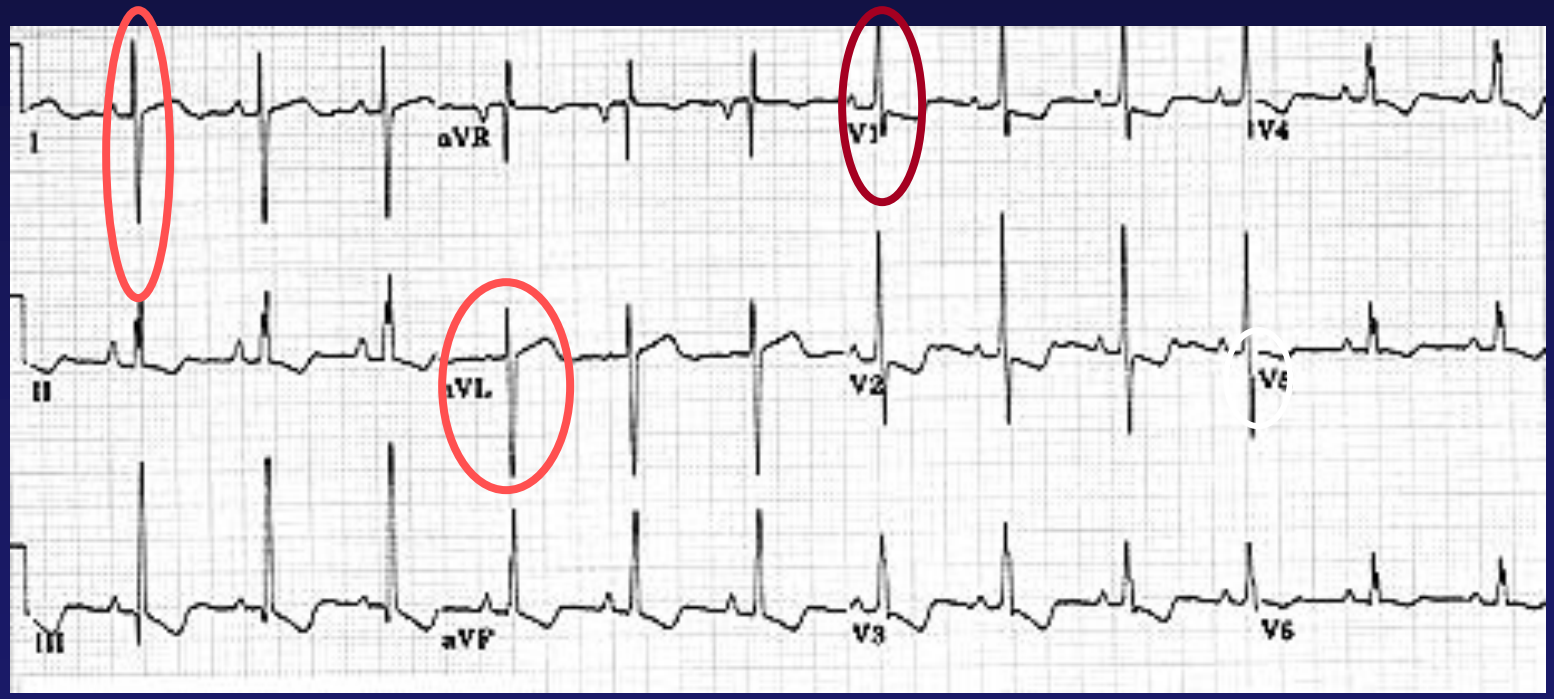

Tehran Arrhythmia Center

RVH, RA enlargement

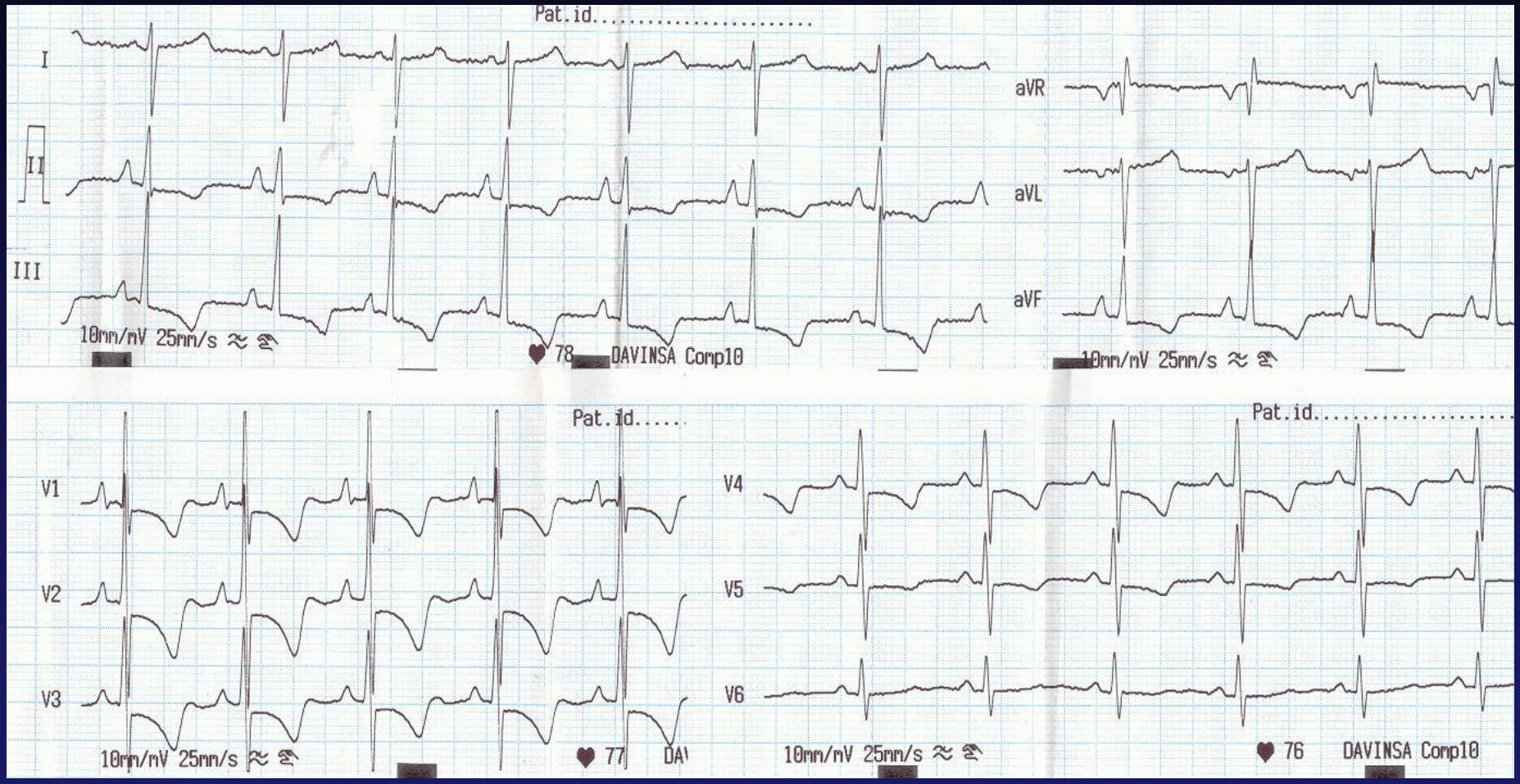

Tehran Arrhythmia Center

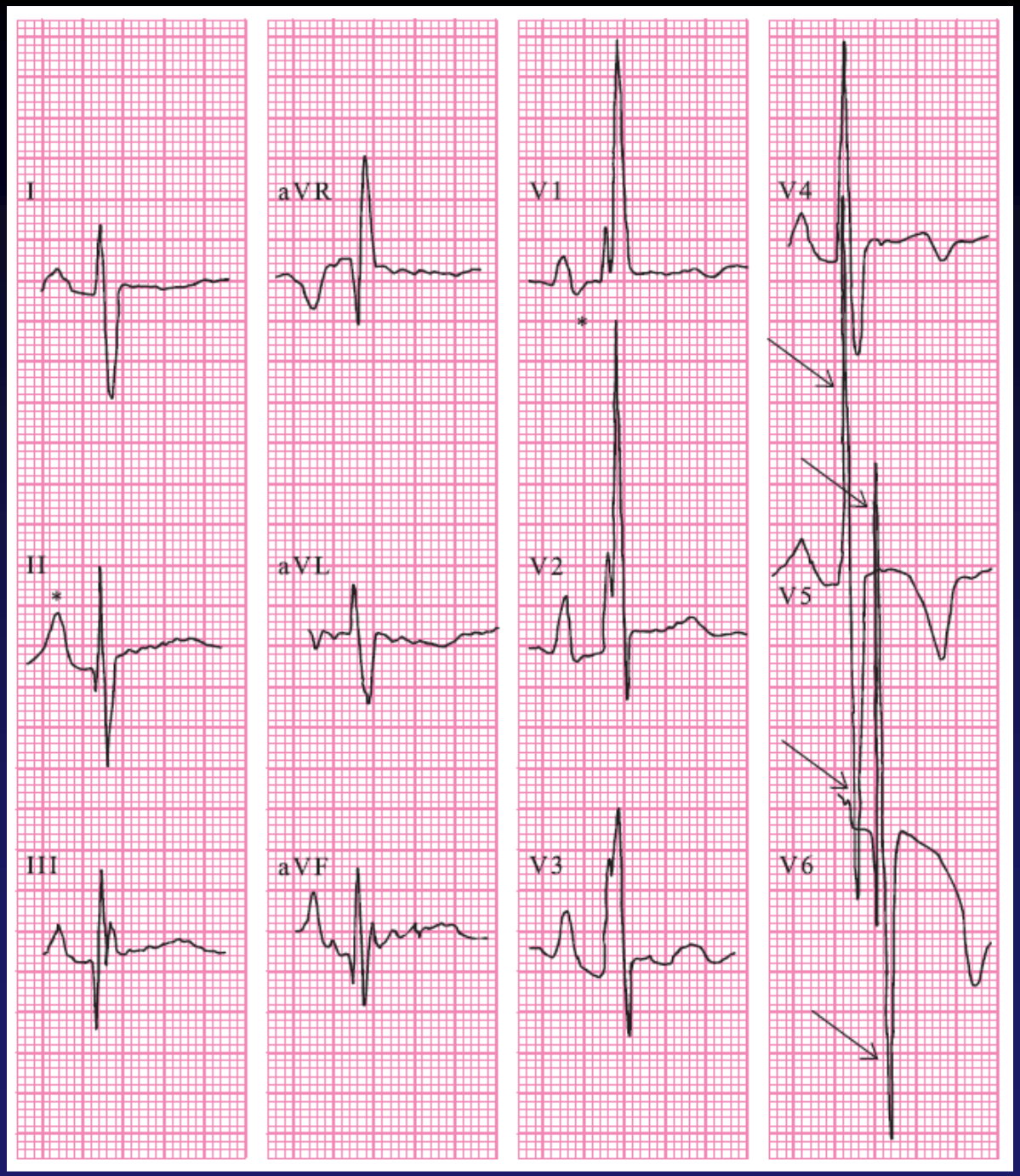

Bi-ventricular Hypertrophy

Tehran Arrhythmia Center

Bundle Branch Blocks

With Bundle Branch Blocks you will see two changes on the ECG.

1. **QRS complex widens (> 0.12 sec).**
2. **QRS morphology changes (varies depending on ECG lead, and if it is a right vs. left bundle branch block).**

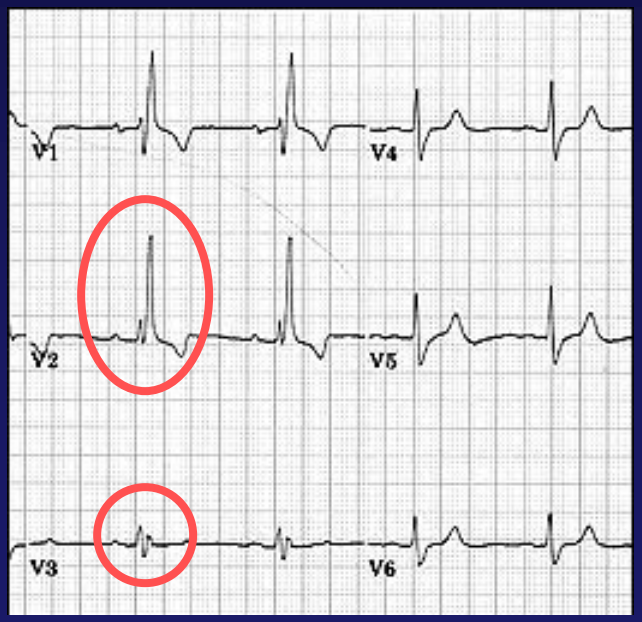

Tehran Arrhythmia Center

Bundle Branch Blocks

Why does the QRS complex widen?

When the conduction pathway is blocked it will take longer for the electrical signal to pass throughout the ventricles.

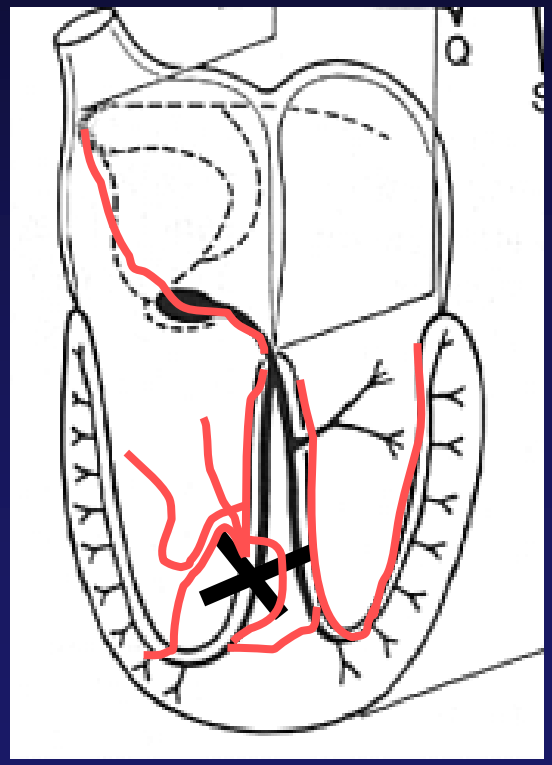

Left Bundle Branch Block

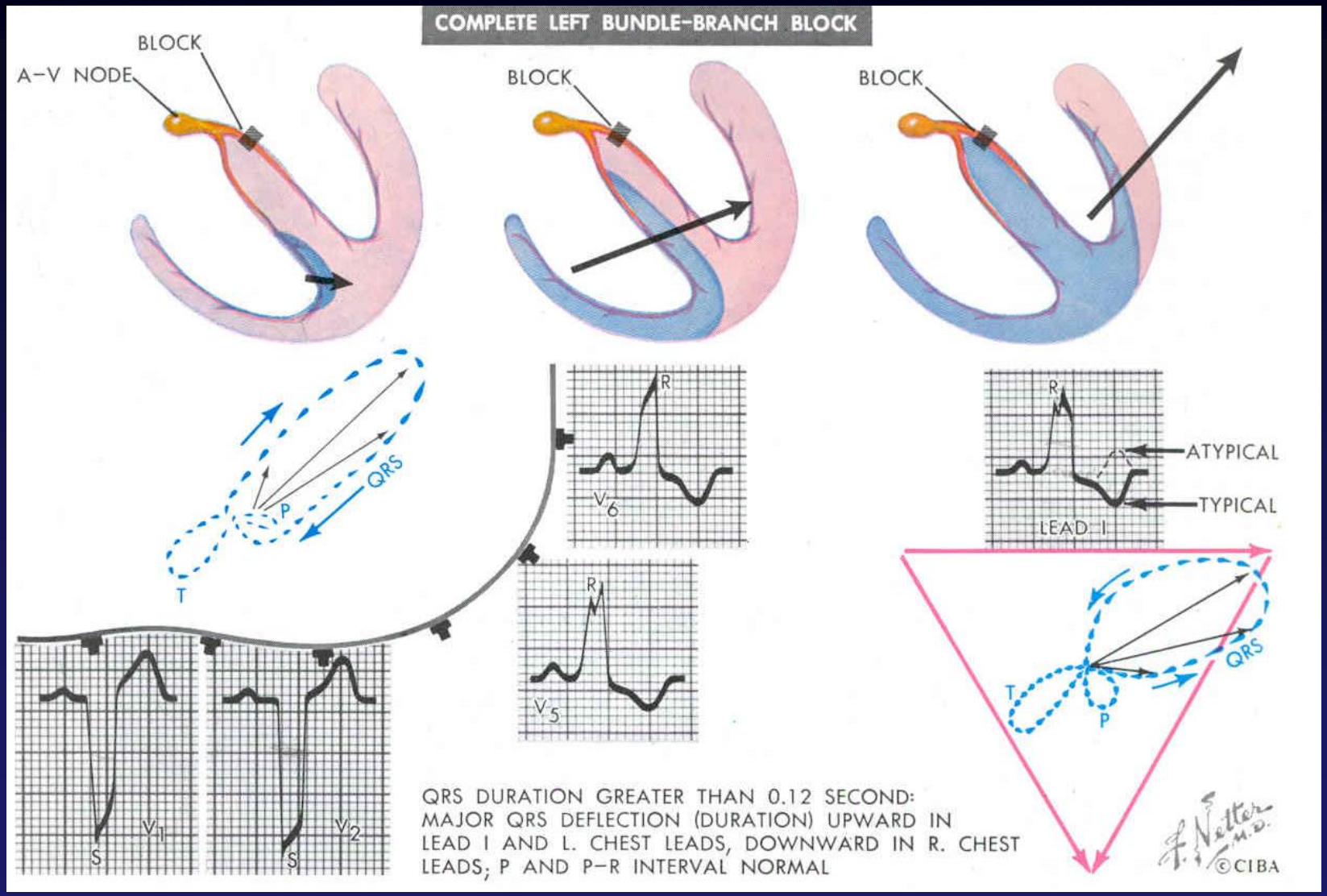

Tehran Arrhythmia Center

Left Bundle Branch Block

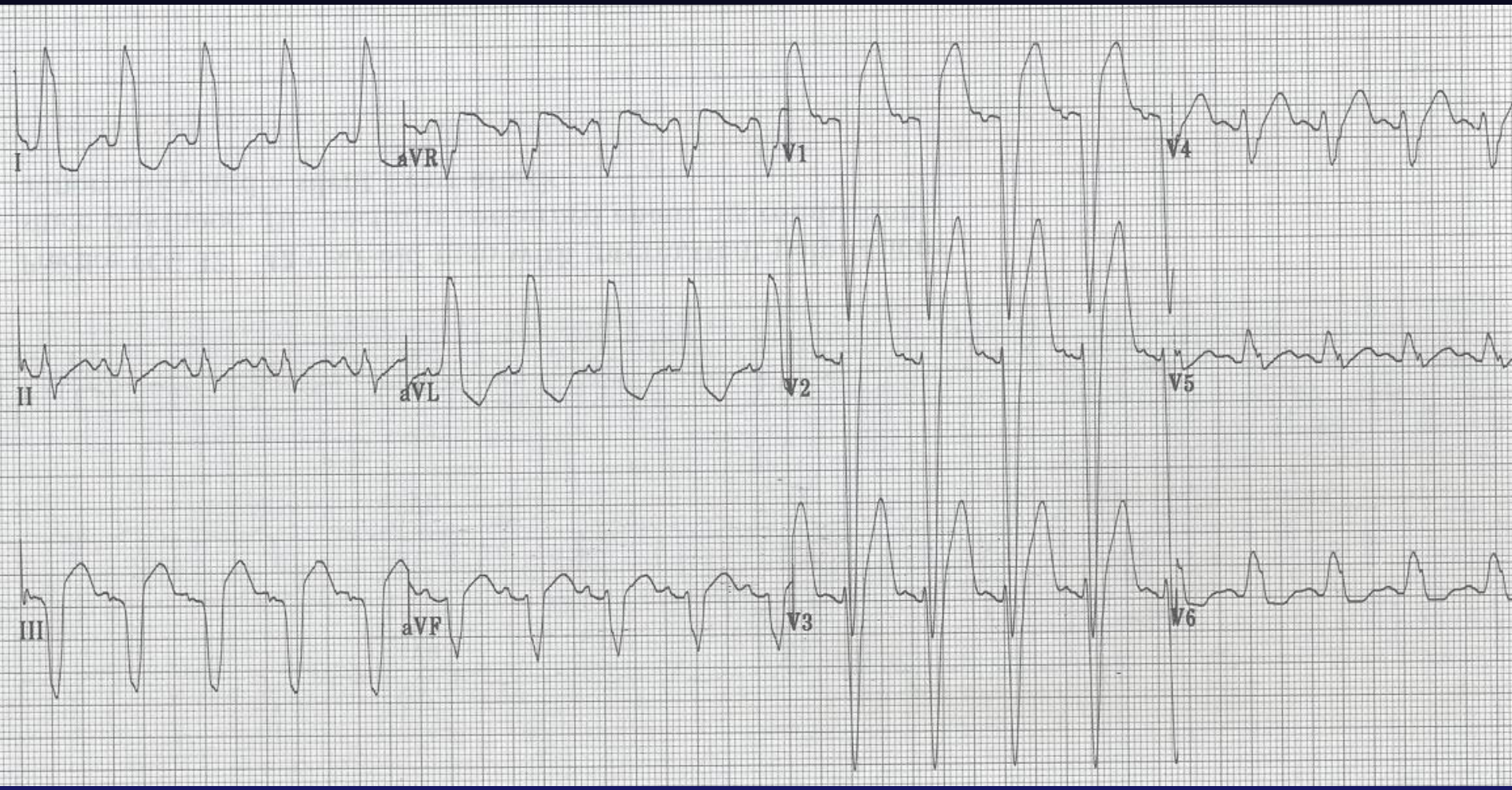

Tehran Arrhythmia Center

Left Bundle Branch Block

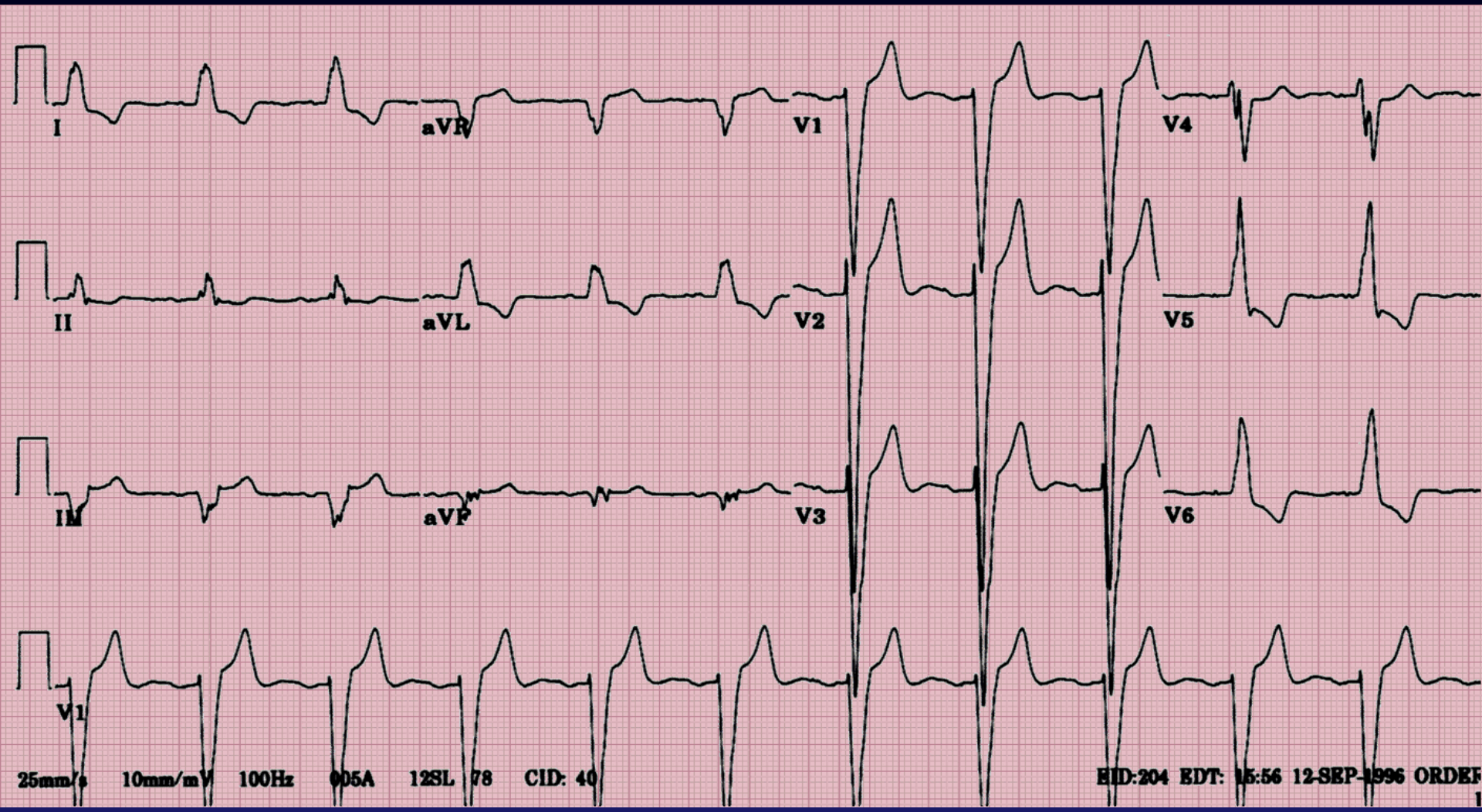

Tehran Arrhythmia Center

LBBB Criteria

Conventional Criteria for Left-Bundle-Branch Block	
Lead V1	QS or rS
Lead V6	Late intrinsicoid (R or R′ peak), no Q waves, monophasic R
Lead I	Monophasic R wave, no Q

Strict Criteria for Left-Bundle-Branch Block	
QRS duration	≥0.13 s in women or ≥0.14 s in men
Lead V1	QS or rS
Mid-QRS notching/slurring in two of the leads I, aVL, V1, V2, V5, or V6	

Right Bundle Branch Block

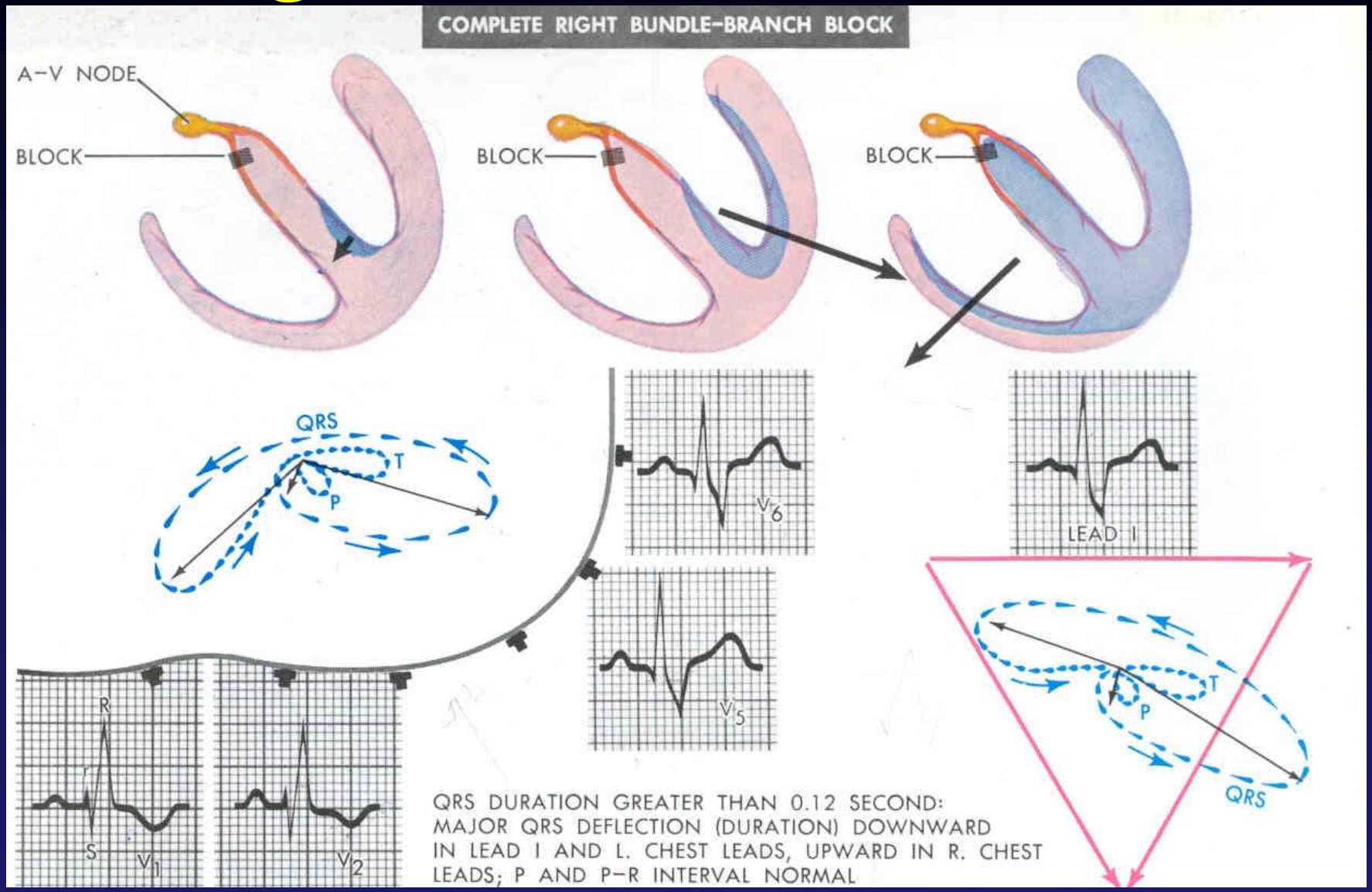

Tehran Arrhythmia Center

Right Bundle Branch Blocks

What QRS morphology is characteristic?

For RBBB the wide QRS complex assumes a unique, virtually diagnostic shape in those leads overlying the right ventricle (V_1 and V_2).



"Rabbit Ears"

Incomplete RBBB

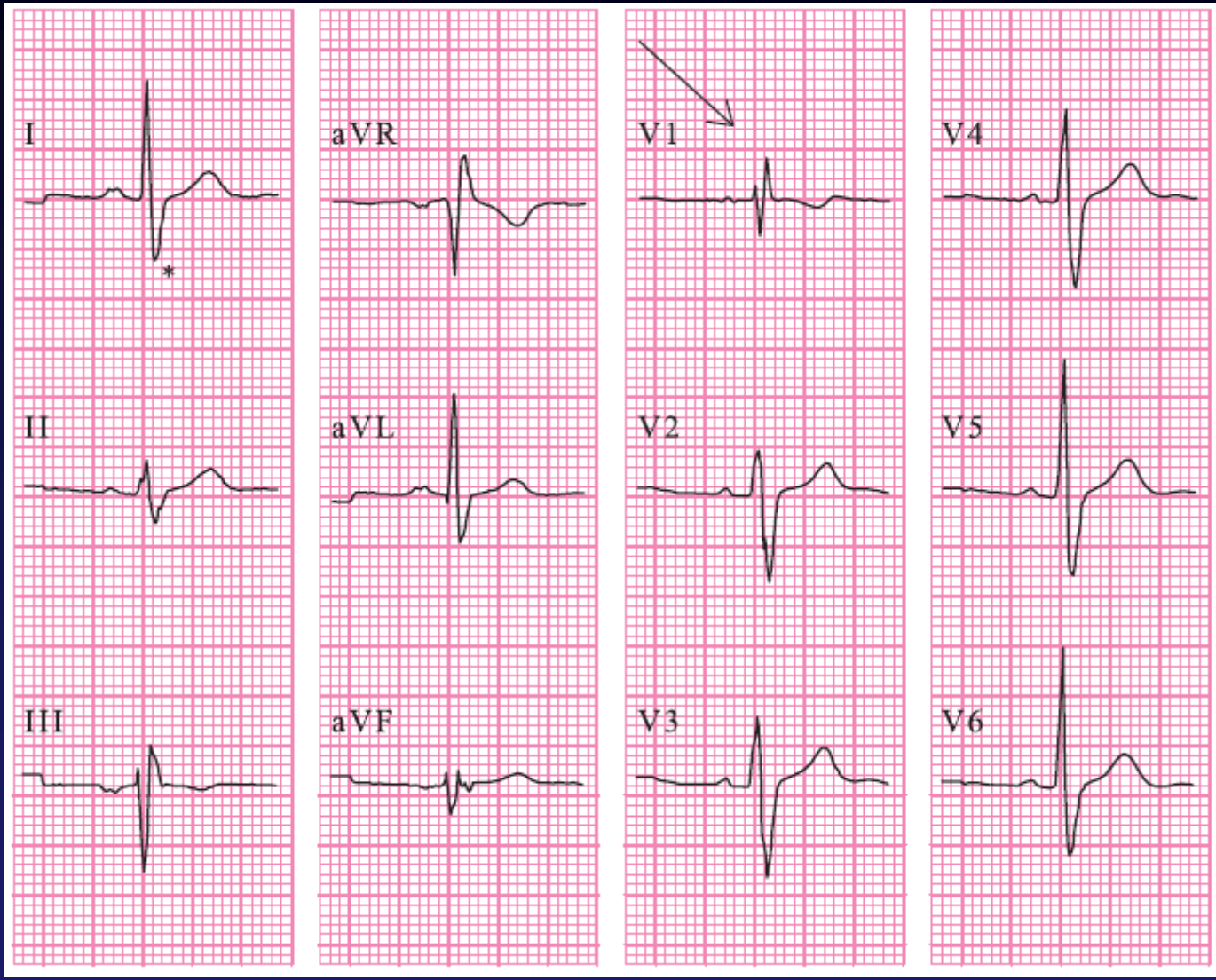

Tehran Arrhythmia Center

RBBB

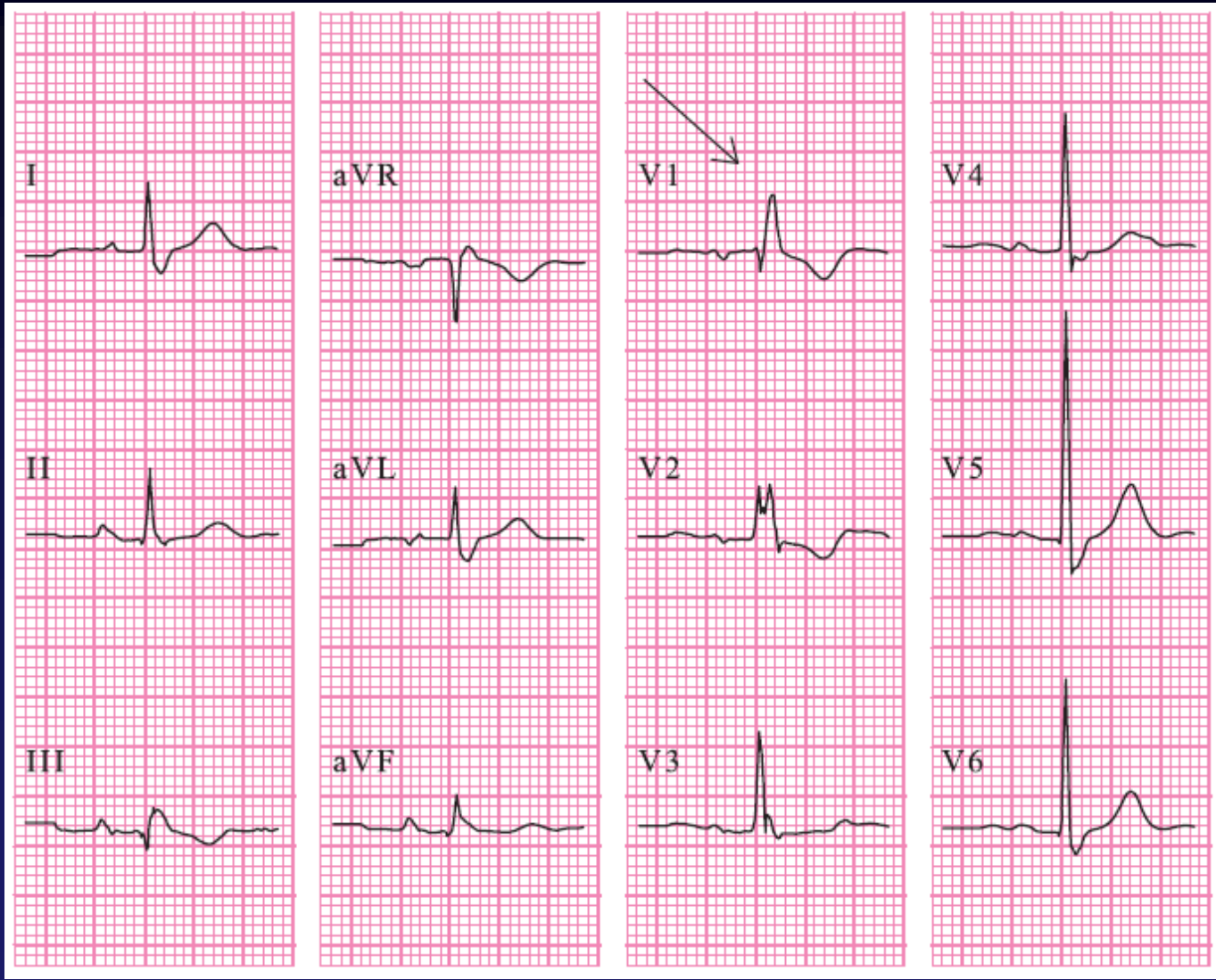

Tehran Arrhythmia Center

RBBB

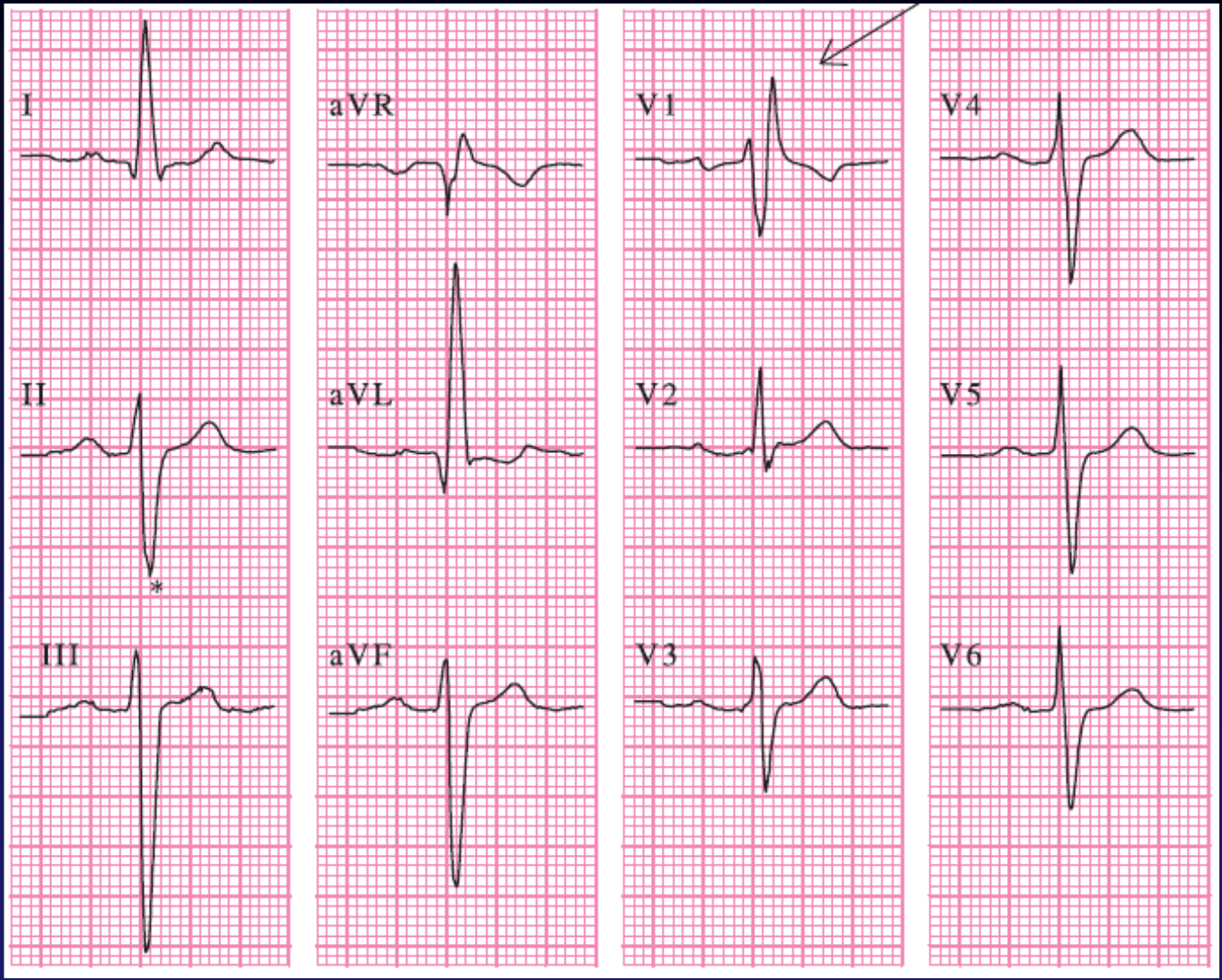

Tehran Arrhythmia Center

RBBB

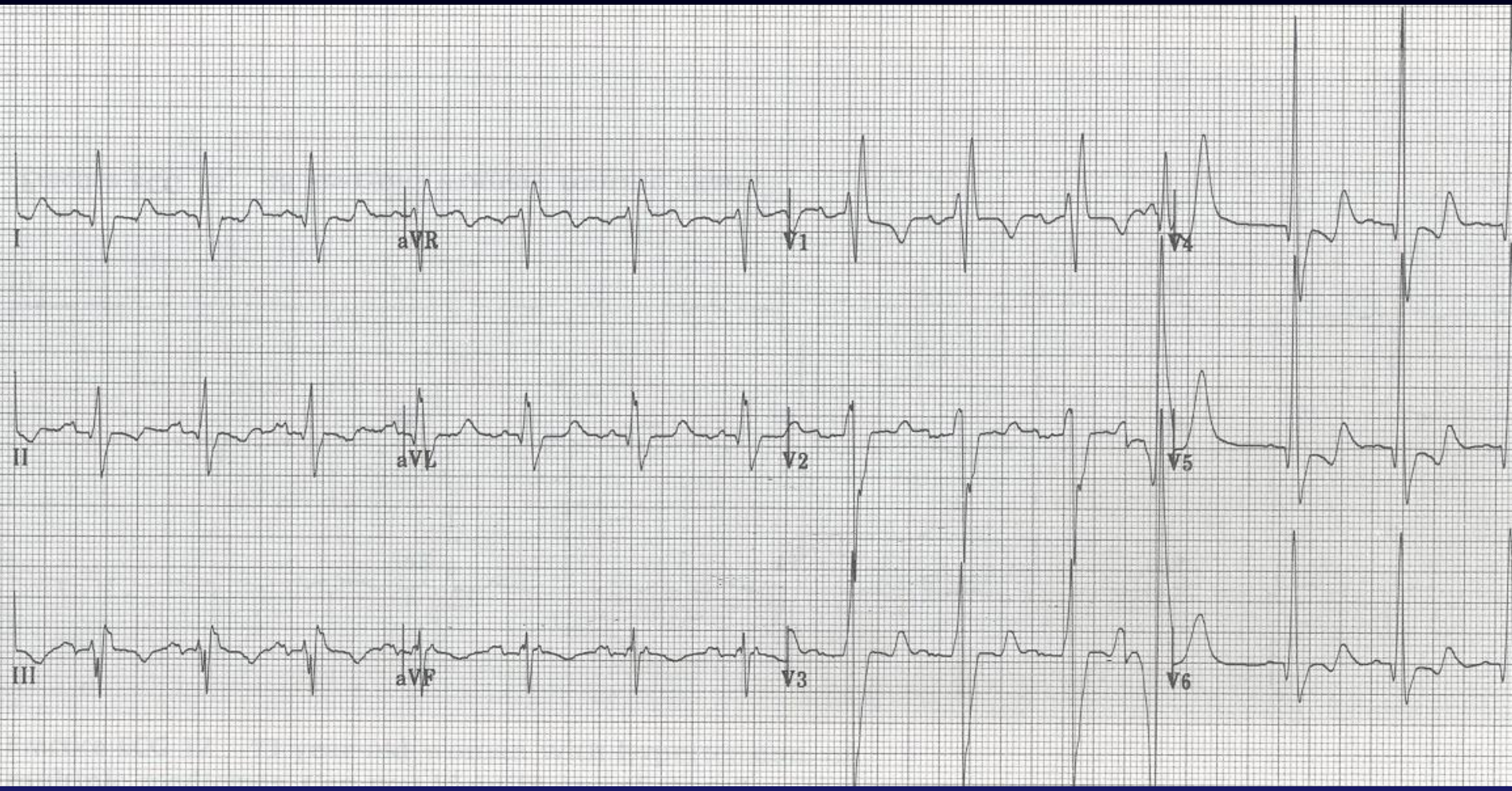

Tehran Arrhythmia Center

RBBB Criteria

Criteria for Right-Bundle-Branch Block	
QRS duration ≥ 0.12 s	
Lead V1	Late intrinsicoid (R′ peak or late R peak), M-shaped QRS (RSR′); sometimes wide R or qR
Lead V6	Early intrinsicoid (R peak), wide S wave
Lead I	Wide S wave

Left Bundle Branch Fascicles

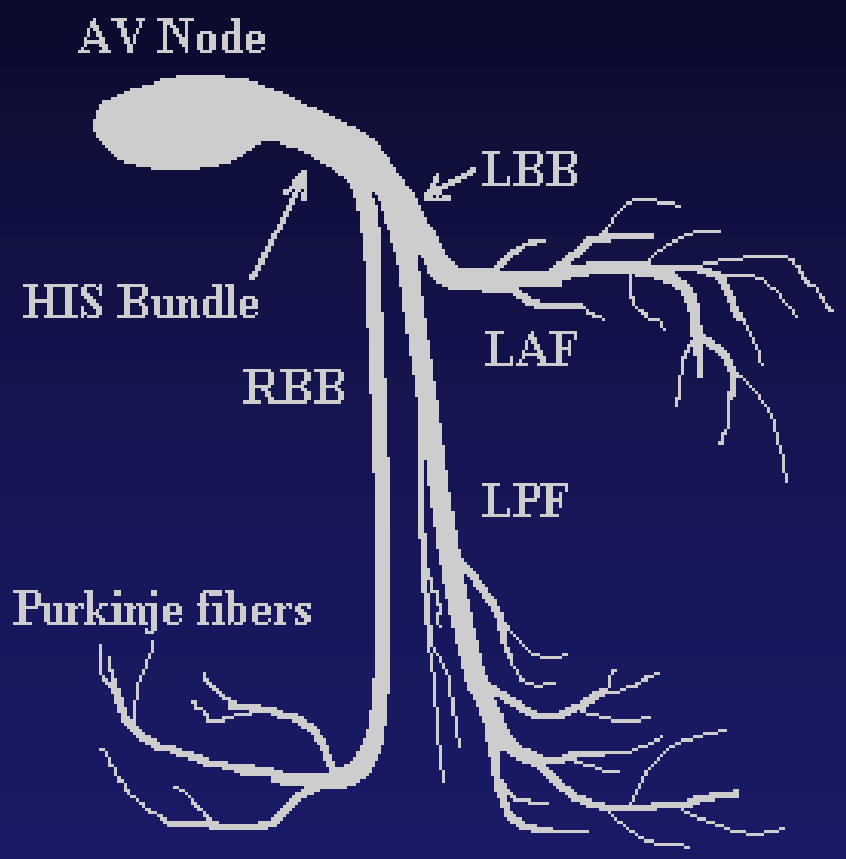

Left Fascicular Blocks

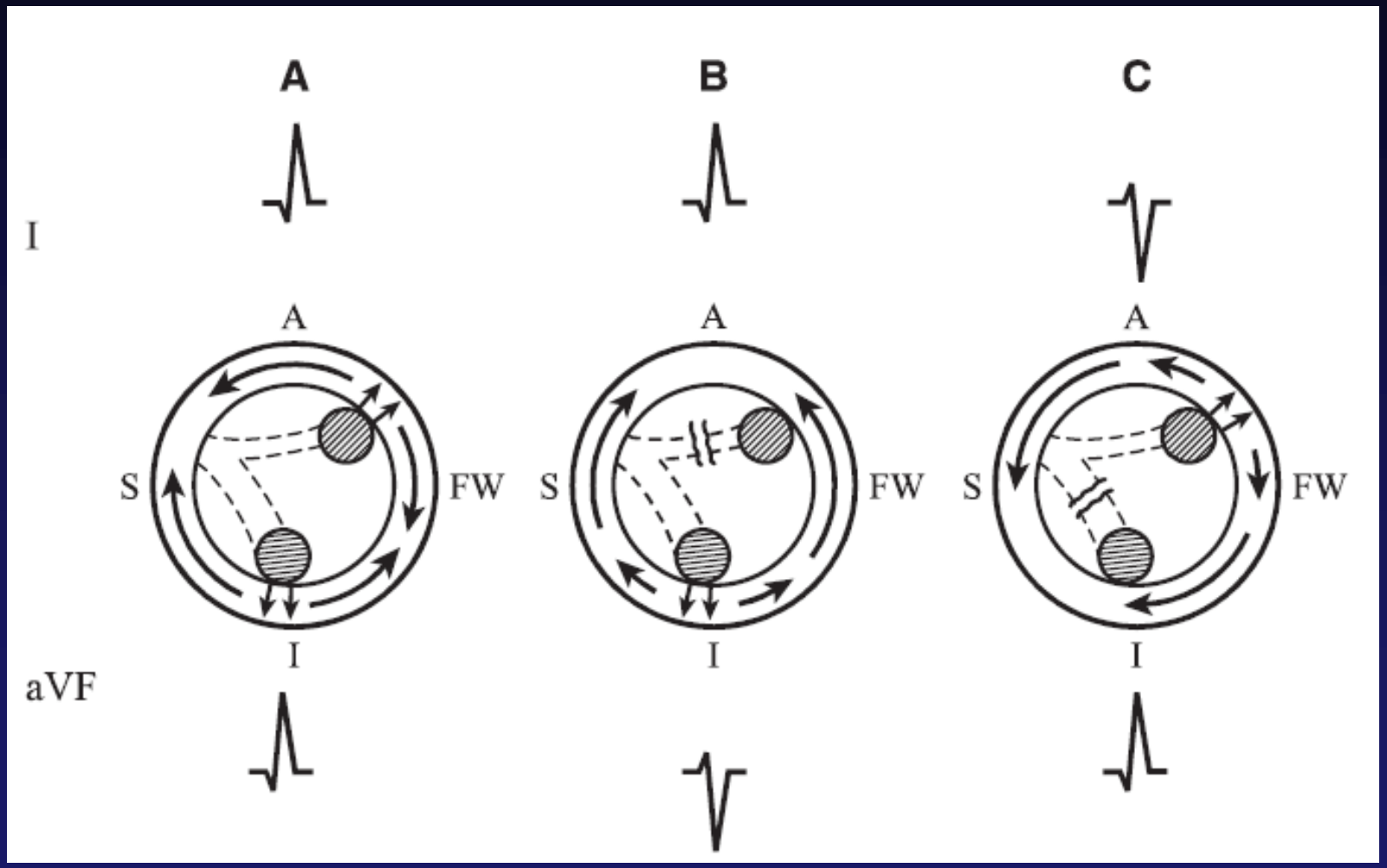

Tehran Arrhythmia Center

Left Anterior Fascicular Block

Left Anterior Hemiblock

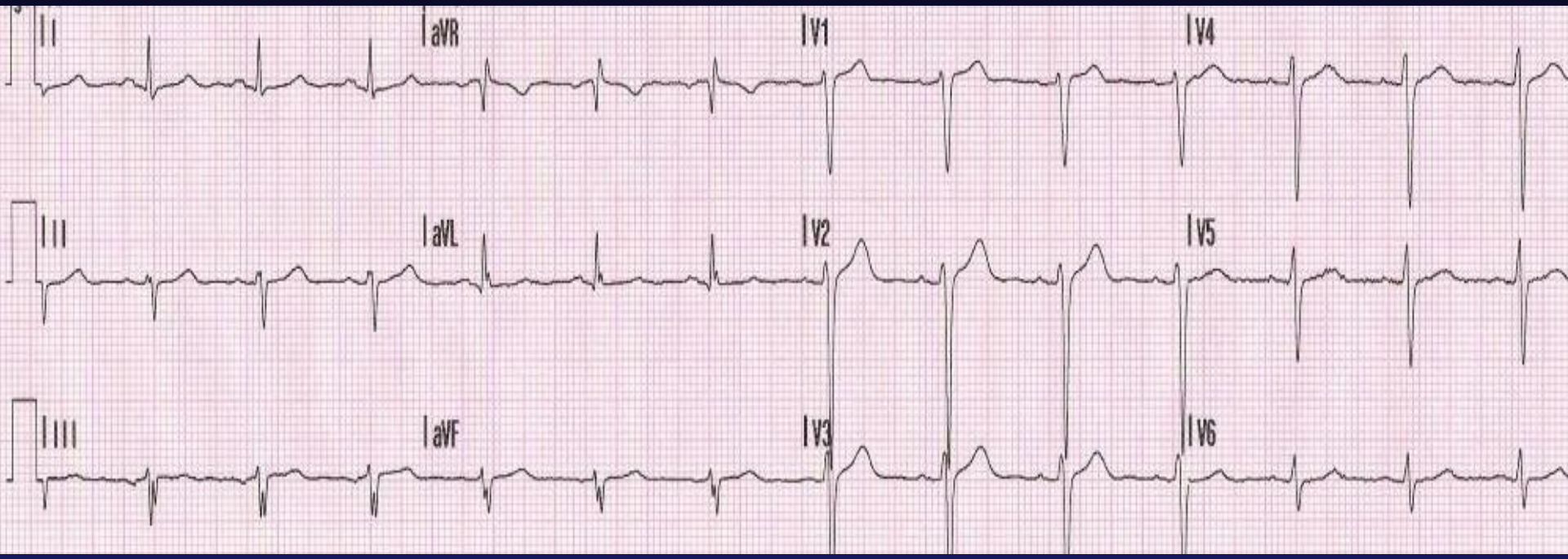



Tehran Arrhythmia Center

Left Anterior Fascicular Block

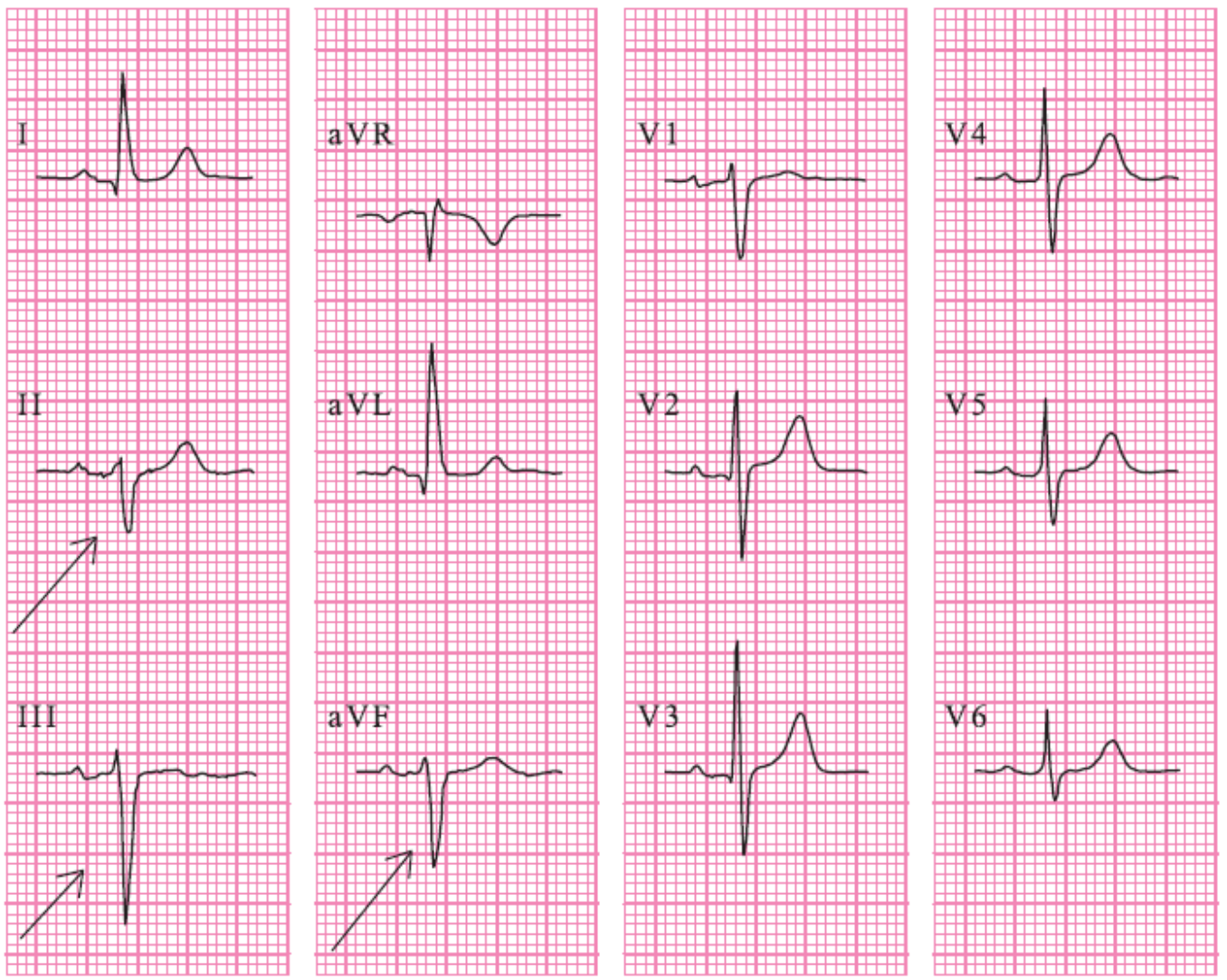

Tehran Arrhythmia Center

Left Anterior Fascicular Block

Left Anterior Hemiblock

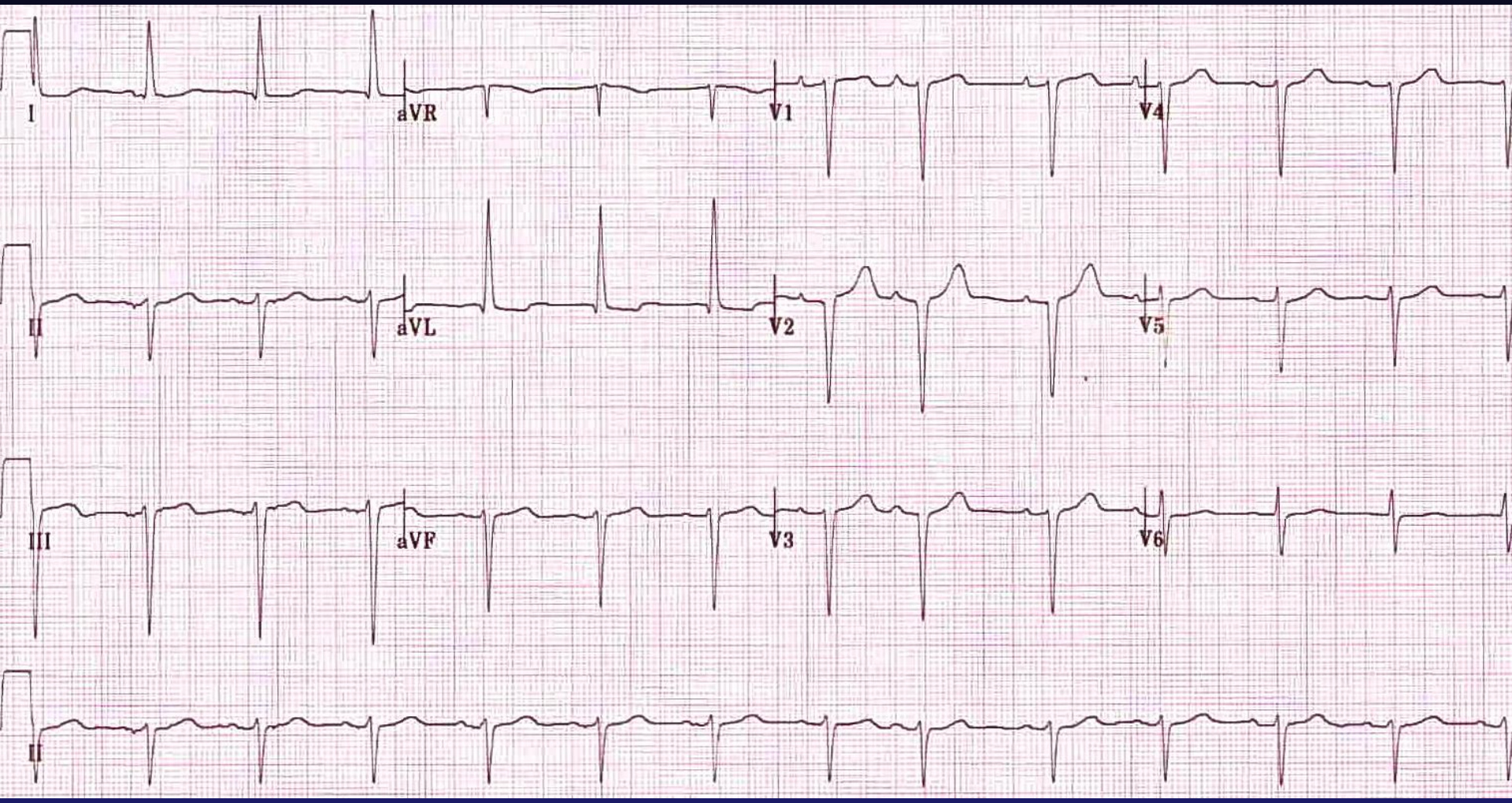

Left Posterior Fascicular Block

Left Posterior Hemiblock

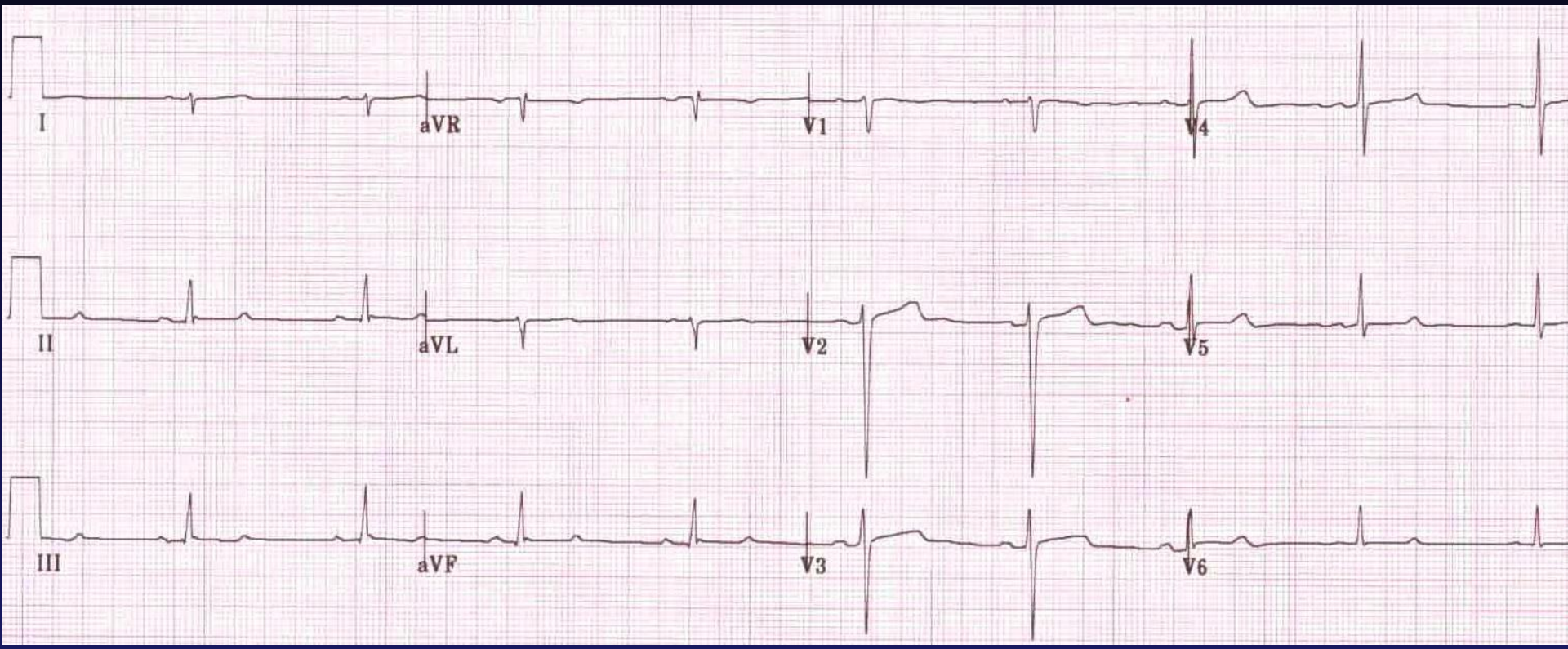



Tehran Arrhythmia Center

Left Posterior Fascicular Block

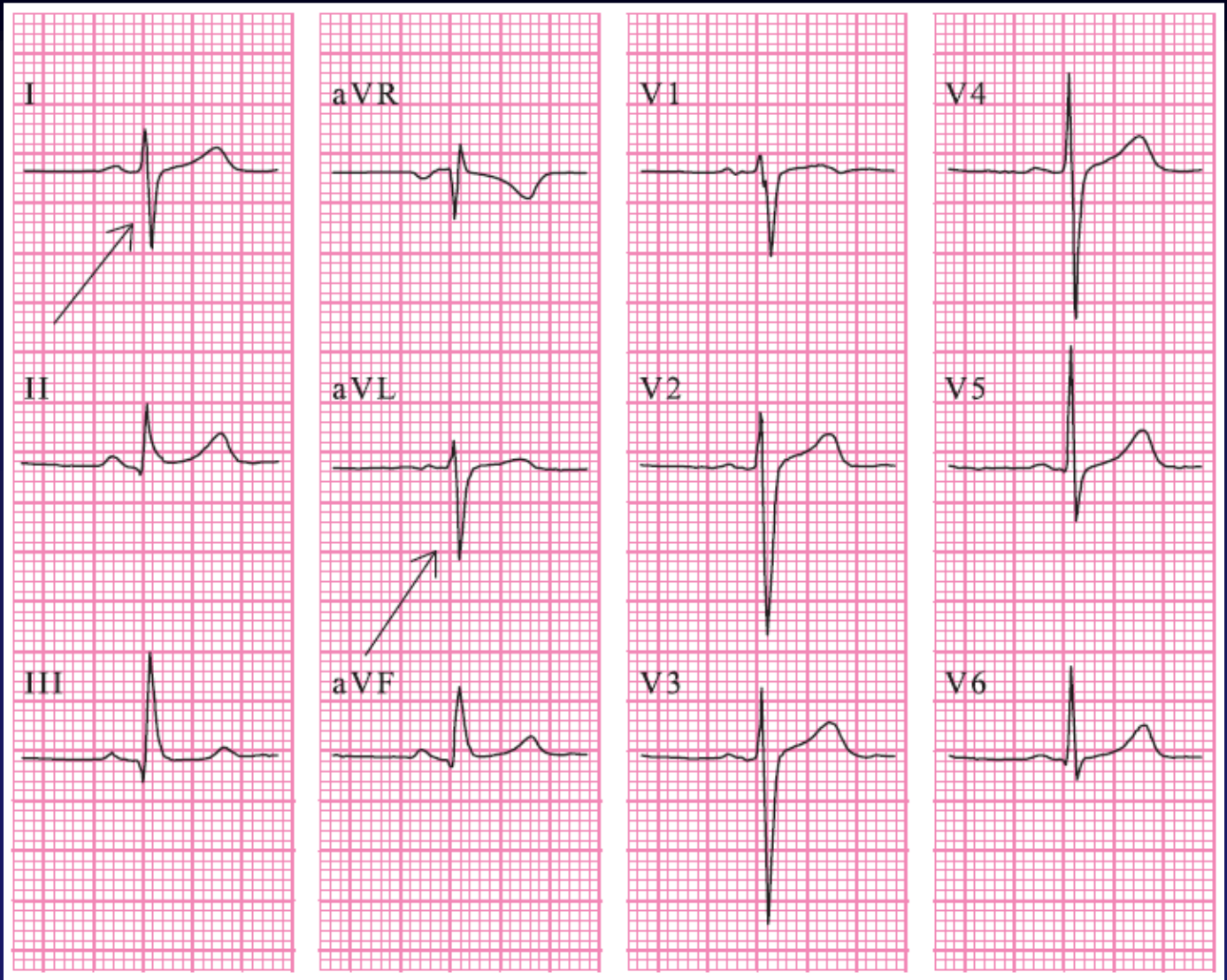

Tehran Arrhythmia Center

Left Posterior Fascicular Block

Left Posterior Hemiblock

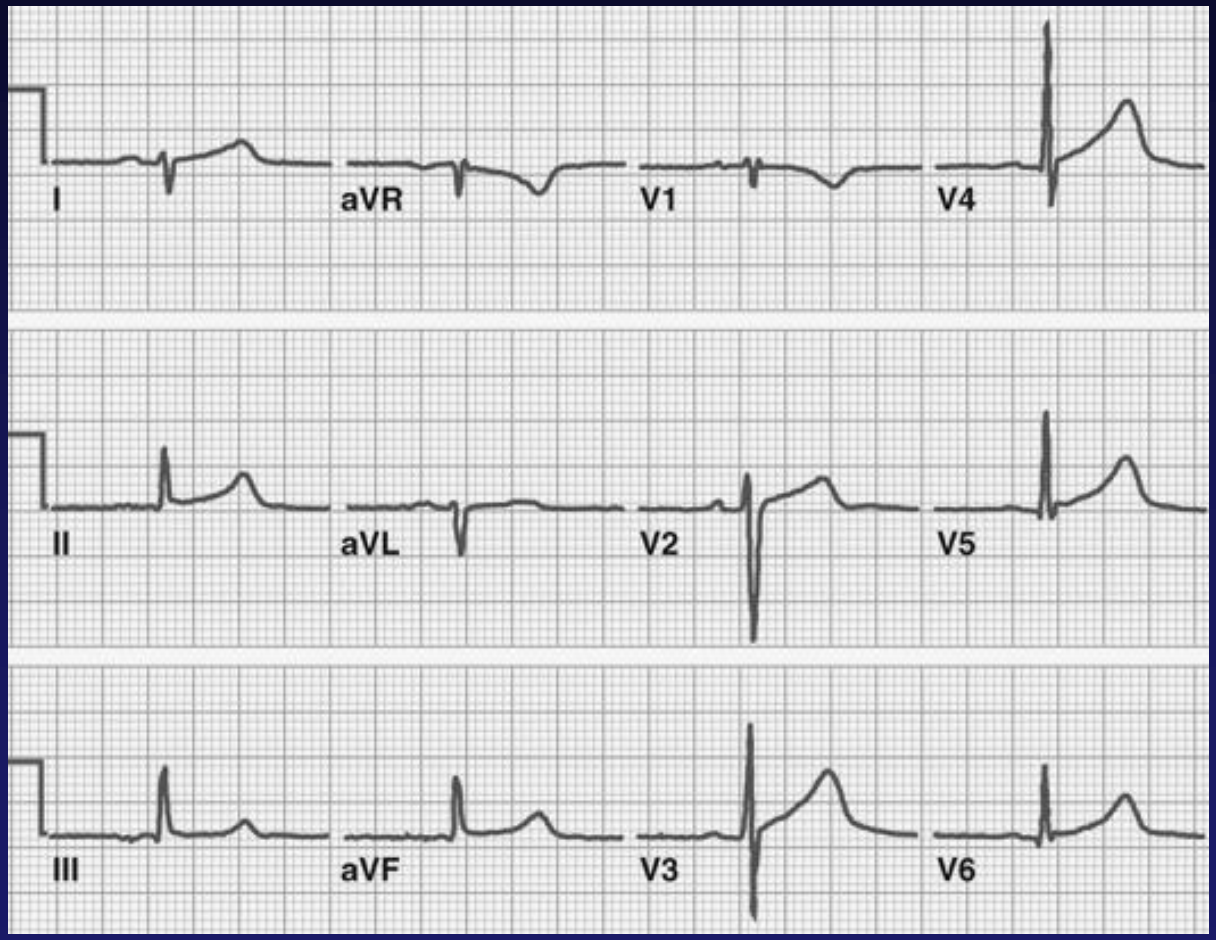

Tehran Arrhythmia Center

Criteria for Fascicular Blocks

Criteria for Left Anterior Fascicular Block

1. Left-axis deviation (usually ≥–60 degrees)
2. Small Q in leads I and aVL; small R in II, III, and aVF
3. Minimal QRS prolongation (0.020 s) from baseline
4. Late intrinsicoid (R wave peak) deflection in aVL (>0.045 s)
5. Increased QRS voltage in limb leads

Criteria for Left Posterior Fascicular Block

1. Right-axis deviation (usually ≥+120 degrees)
2. Small R in leads I and aVL; small Q in II, III, and aVF
3. Usually normal QRS duration
4. Late intrinsicoid deflection in aVF (>0.045 s)
5. Increased QRS voltage in limb leads
6. No evidence of RVH

RBBB, LAH (Bi-fascicular Block)

Tehran Arrhythmia Center

RBBB, LPH (Bi-fascicular Block)

Tehran Arrhythmia Center

RBBB, LPH (Bi-fascicular Block)

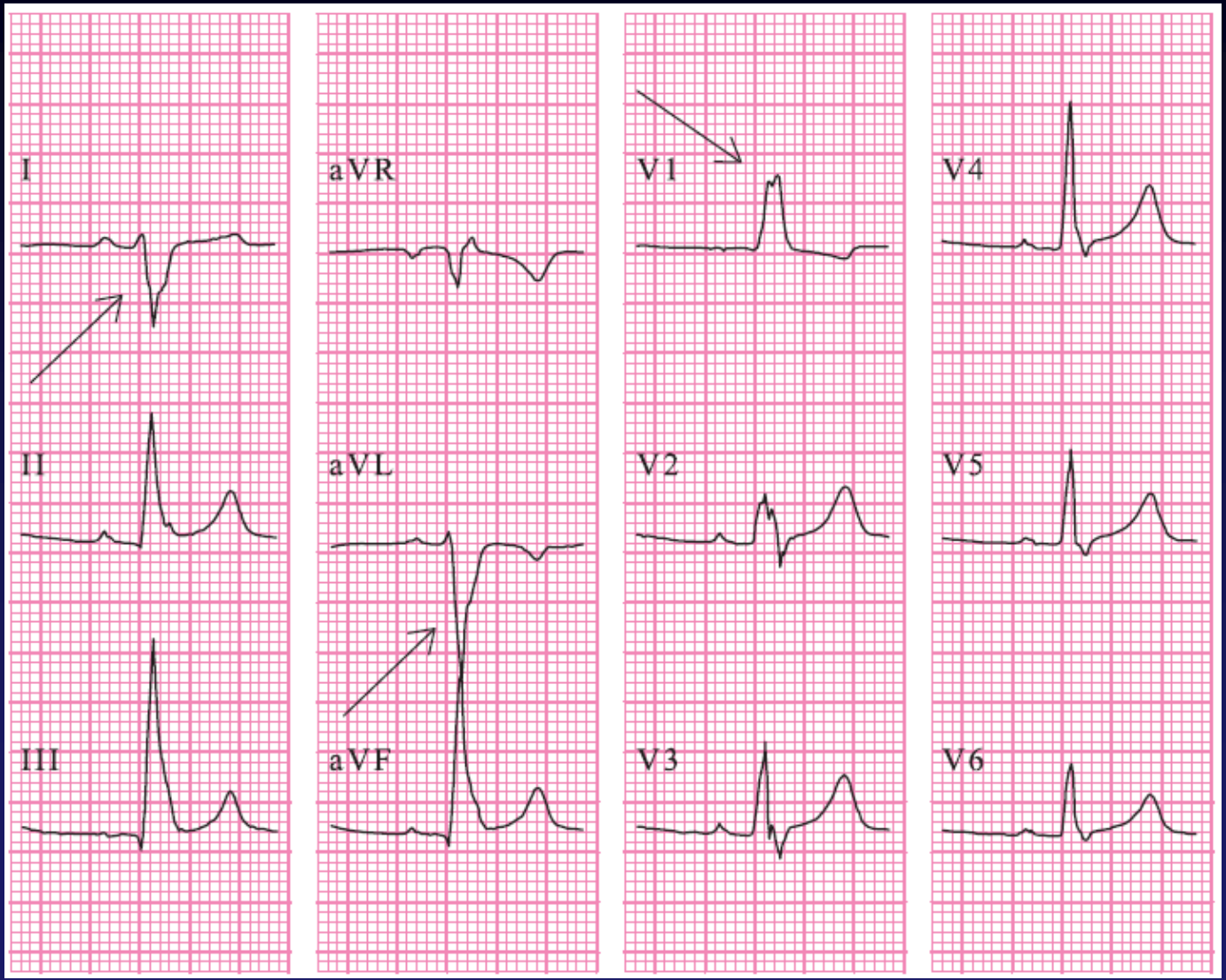

Tehran Arrhythmia Center

Myocardial Ischemia

- ECG is the cornerstone in the diagnosis of myocardial ischemia
- Findings depend on several factors:
  - Nature of the process, reversible vs. irreversible
  - Duration, acute vs. chronic
  - Extent, transmural vs. subendocardial
  - Localization, anterior vs. inferoposterior
  - Other underlying abnormalities

Evolution of a Myocardial Infarction

- When myocardial blood supply is abruptly reduced or cut off to a region of the heart, a sequence of injurious events occur beginning with ischemia (inadequate tissue perfusion), followed by necrosis (infarction), and eventual fibrosis (scarring) if the blood supply isn't restored in an appropriate period of time.

- The ECG changes over time with each of these events…

ST Elevation Infarction

The ECG changes seen with a ST elevation infarction are:

Before injury	**Normal ECG**
↓	
Ischemia	**Peaked T-waves, then T-wave inversion, ST depression,**
↓	
Infarction	**ST elevation & appearance of Q-waves**
↓	
Fibrosis	**ST segments and T-waves return to normal, but Q-waves persist**

Acute Ischemia

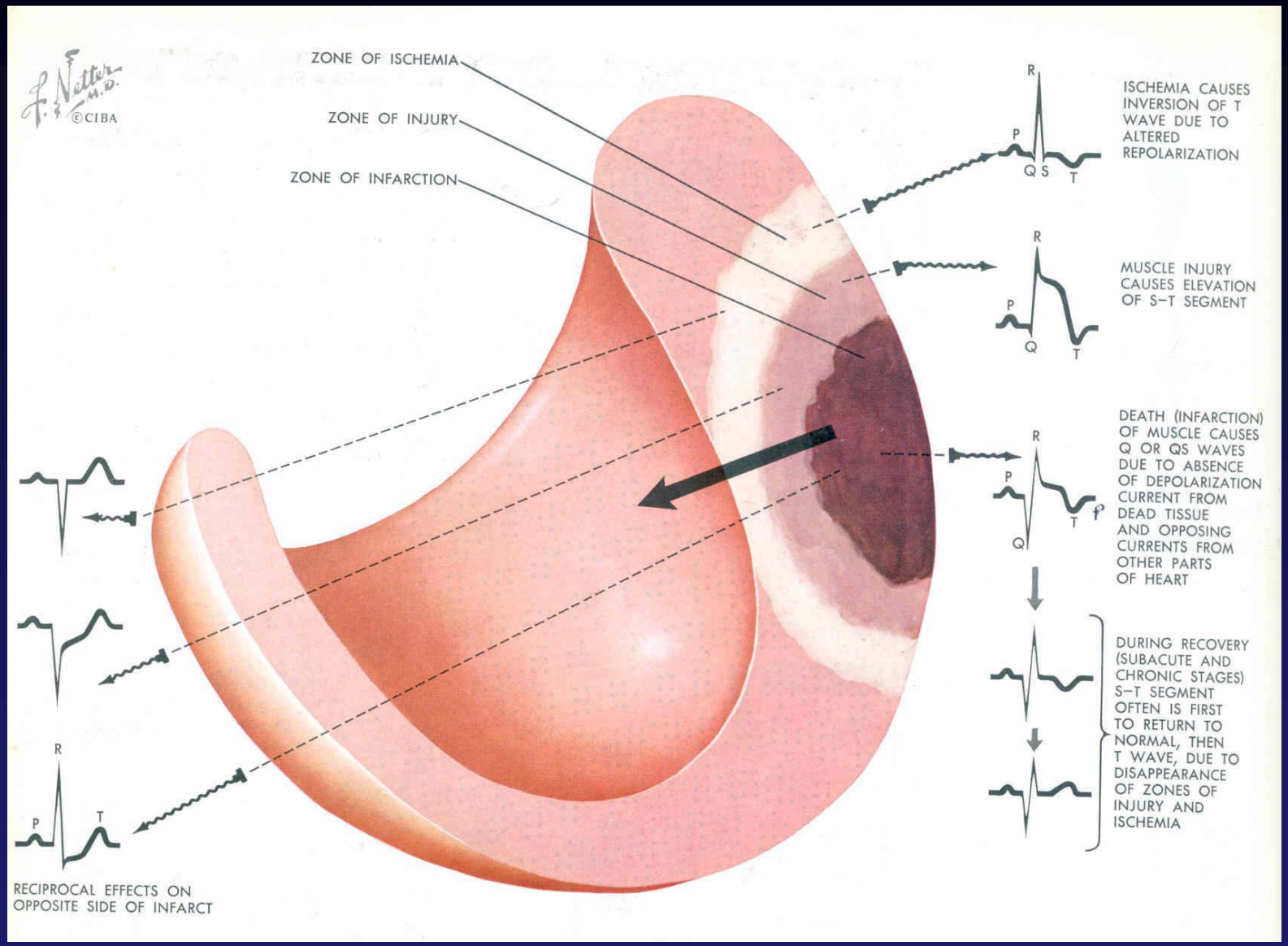

Tehran Arrhythmia Center

ST Elevation

A great way to diagnose an acute MI is to look for elevation of the ST segment.

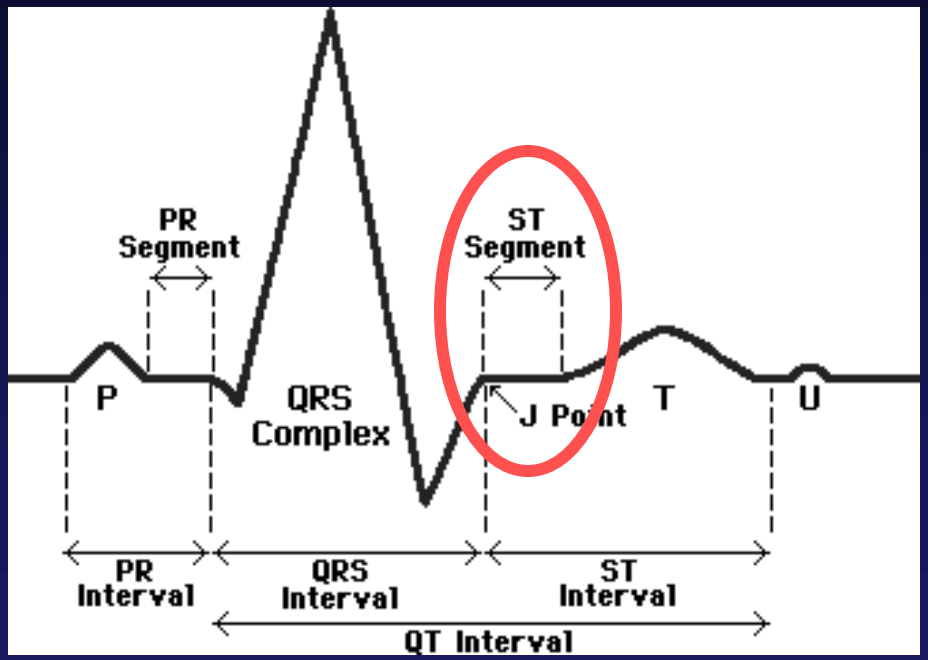

ECG Changes

Ways the ECG can change include:

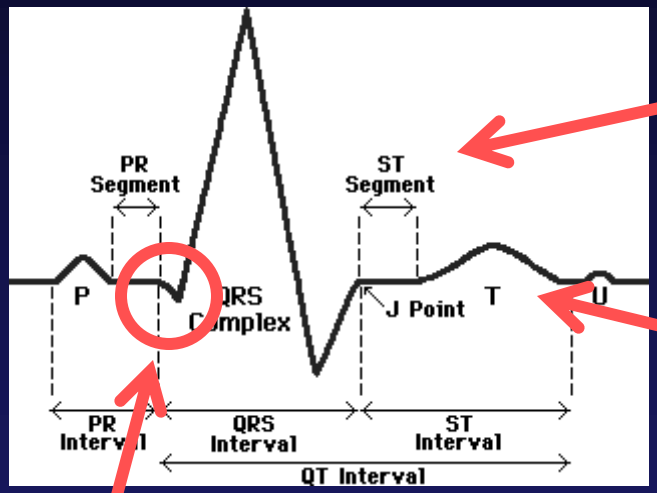

ST elevation & depression

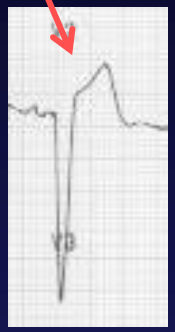

T-waves

peaked

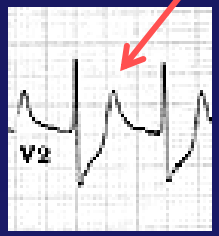

flattened

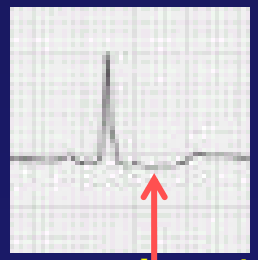

inverted

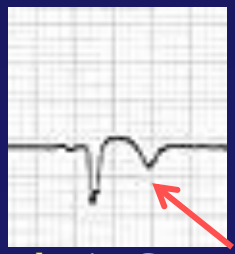

Appearance of pathologic Q-waves



Tehran Arrhythmia Center

ST Elevation

Elevation of the ST segment (greater than 1 small box) in 2 leads is consistent with a myocardial infarction.

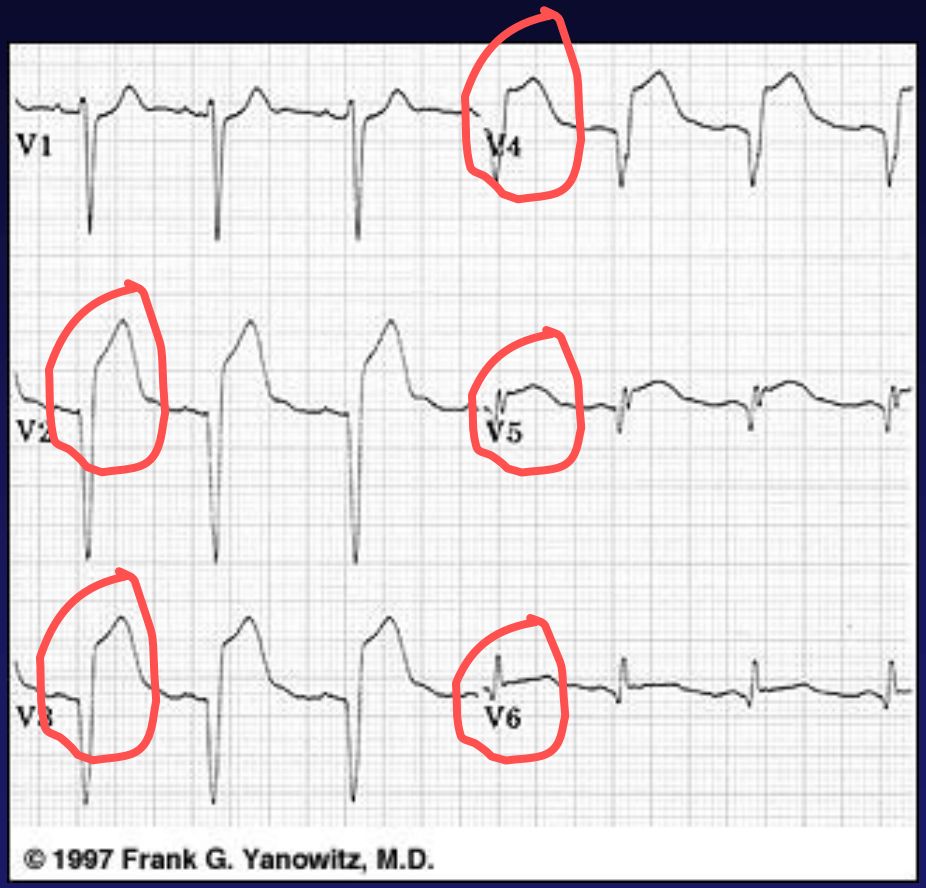

ST Elevation Infarction

Evolving infarction:

A. Normal ECG prior to MI

B. Ischemia from coronary artery occlusion results in ST depression (not shown) and peaked T-waves

C. Infarction from ongoing ischemia results in marked ST elevation

D/E. Ongoing infarction with appearance of pathologic Q-waves and T-wave inversion

F. Fibrosis (months later) with persistent Q- waves, but normal ST segment and T- waves

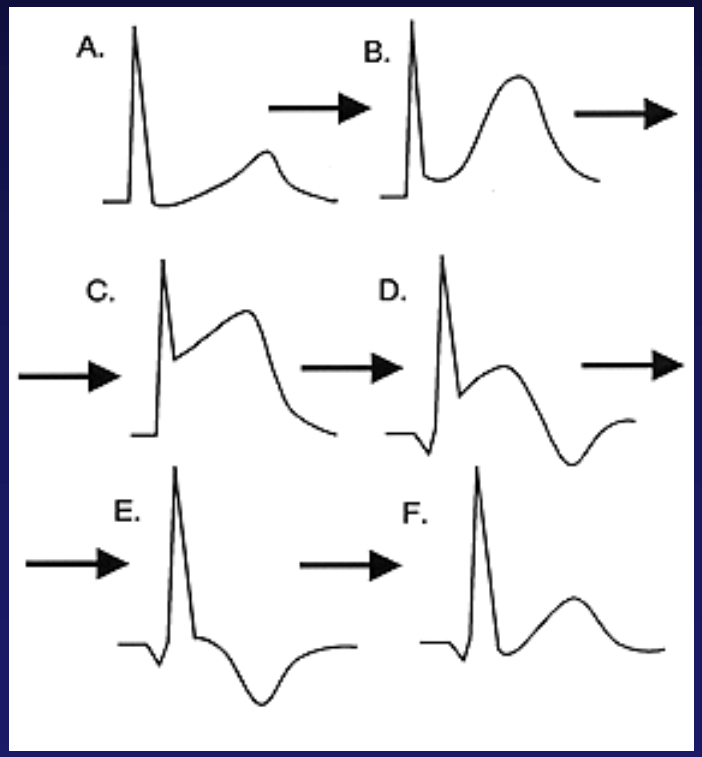

Views of the Heart

Some leads get a good view of the:

Lateral portion of the heart

Anterior portion of the heart

Inferior portion of the heart

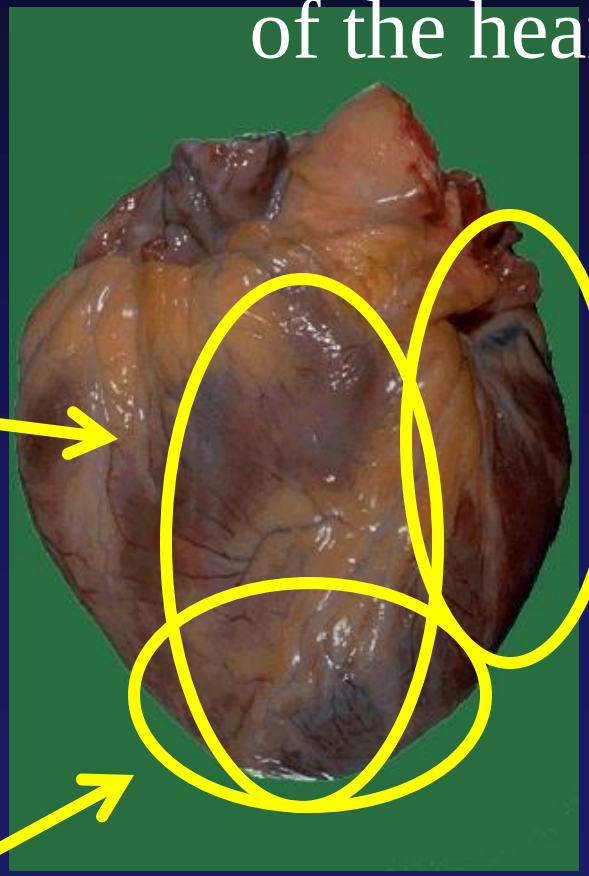

Tehran Arrhythmia Center

Anterior MI

Remember the anterior portion of the heart is best viewed using leads V_1- V_4.

Limb Leads

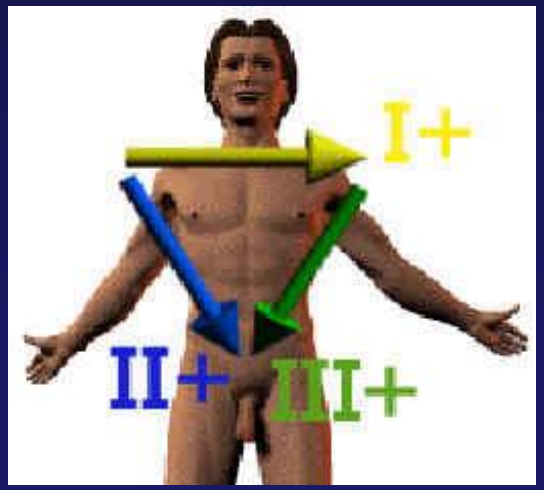

Augmented Leads

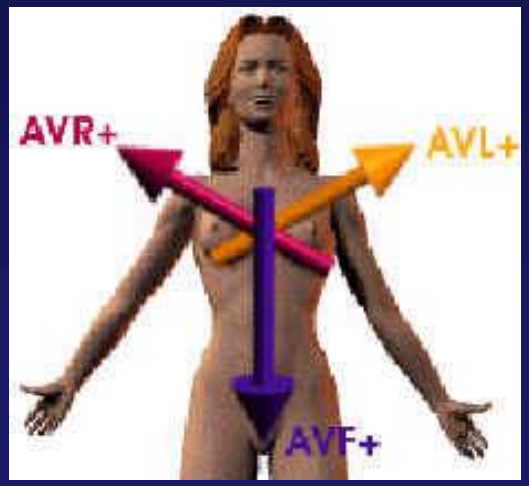

Precordial Leads

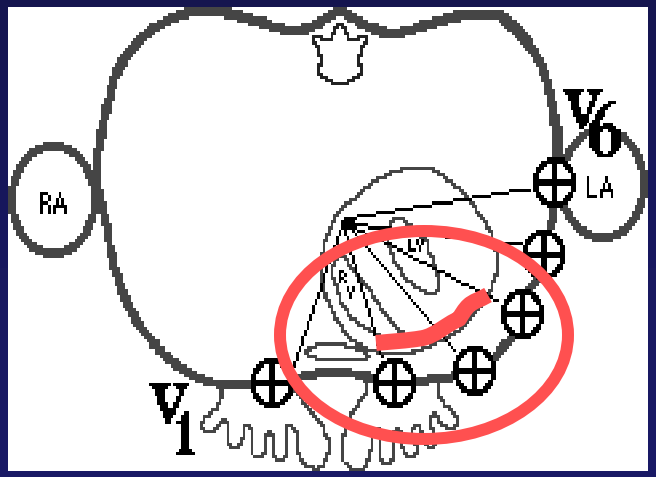

Lateral MI

The lateral portion of the heart is best viewed by:

Leads I, aVL, and V_5- V_6

Limb Leads

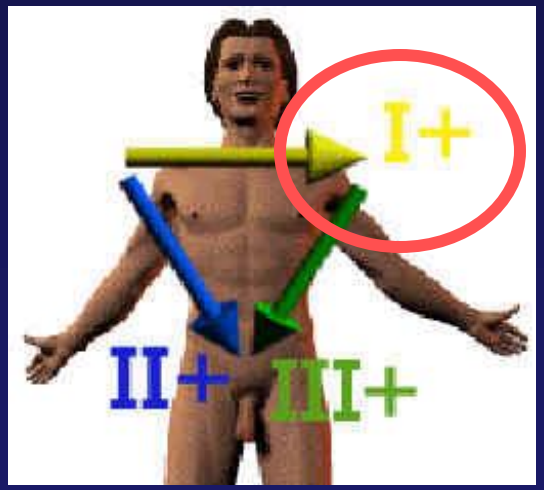

Augmented Leads

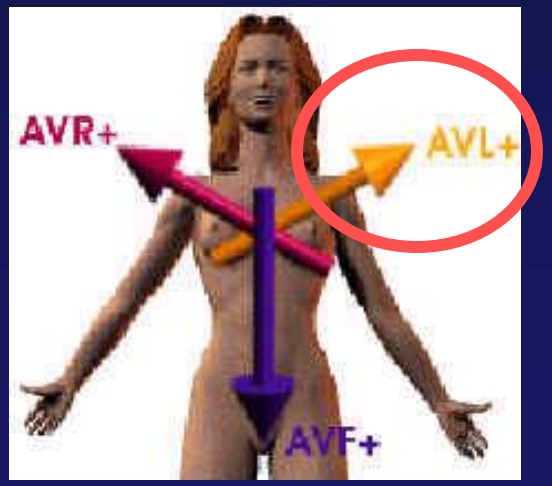

Precordial Leads

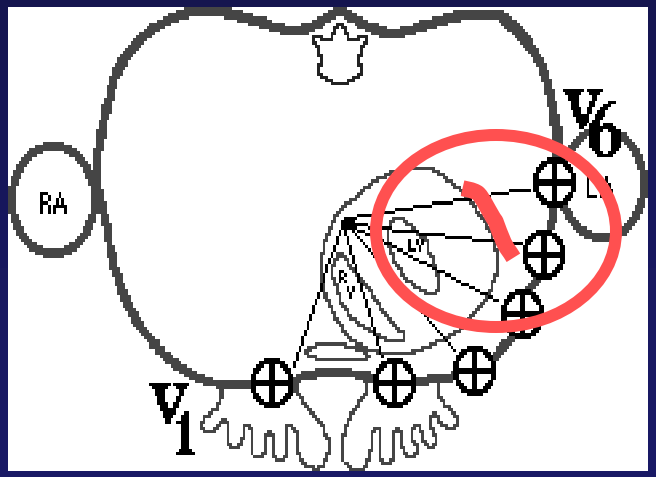

Inferior MI

The inferior portion of the heart by:

Leads II, III and aVF

Limb Leads

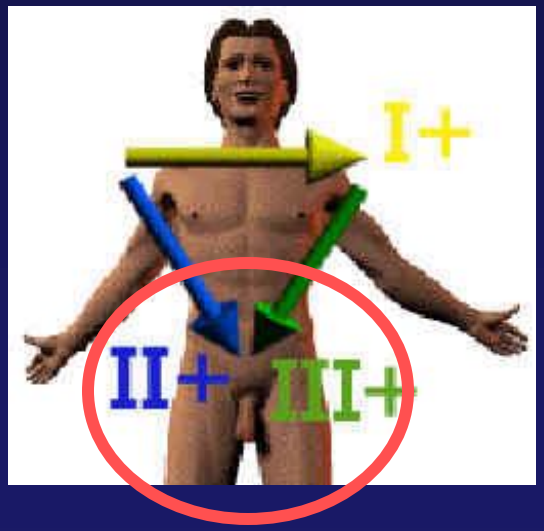

Augmented Leads

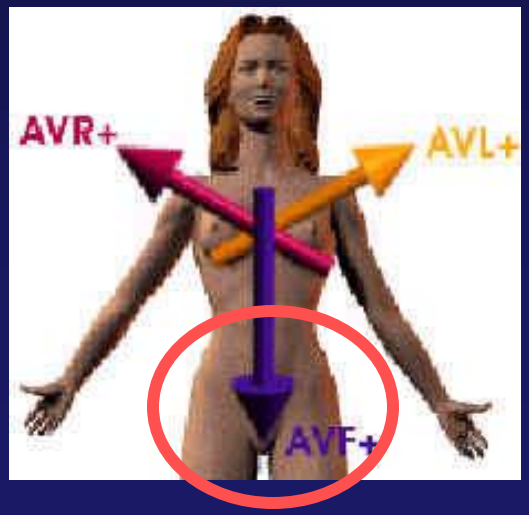

Precordial Leads

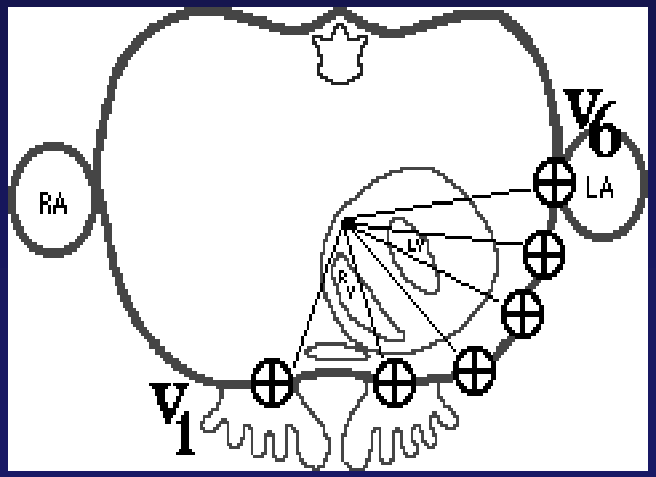

Tehran Arrhythmia Center

Inferior Wall MI

Note the ST elevation in leads II, III and aVF.

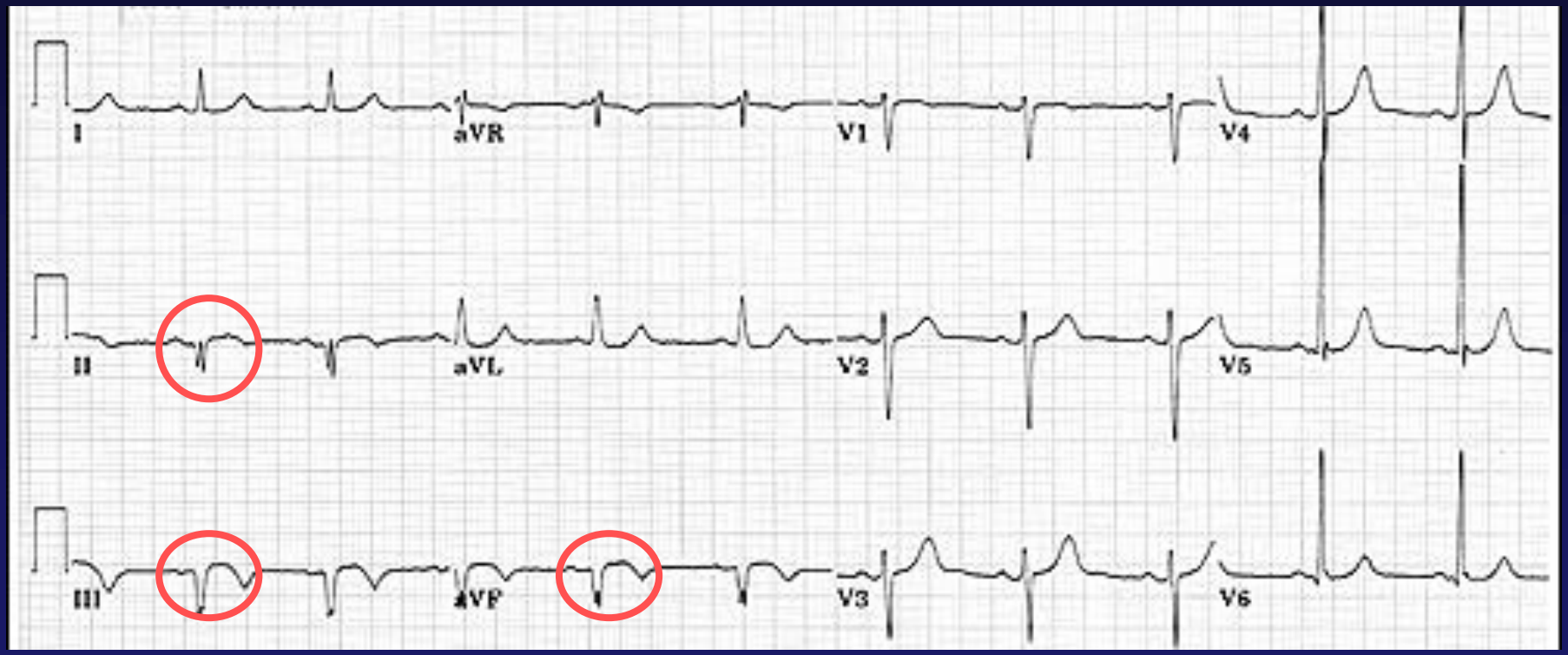

Tehran Arrhythmia Center

Anterolateral MI

This person's MI involves both the anterior wall (V_2-V_4) and the lateral wall (V_5-V_6, I, and aVL)!

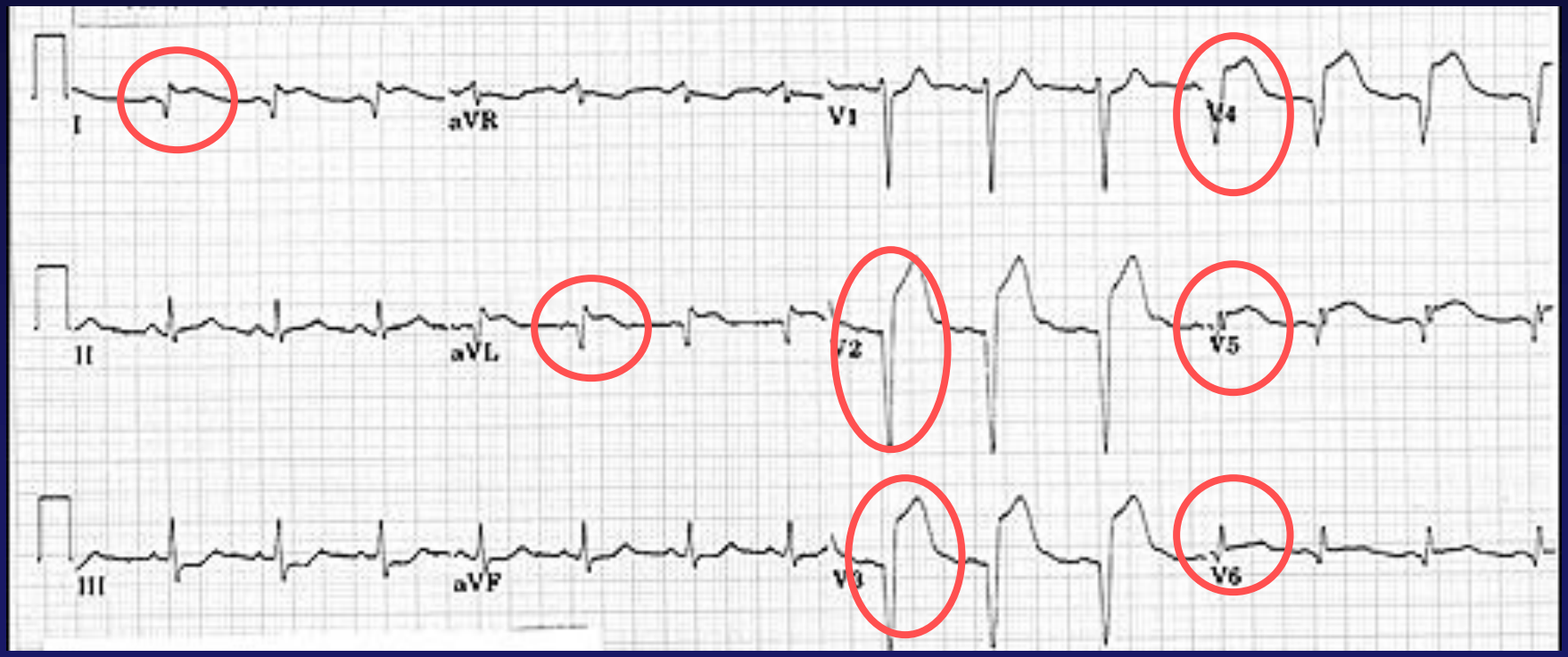

Tehran Arrhythmia Center

Myocardial Infarction

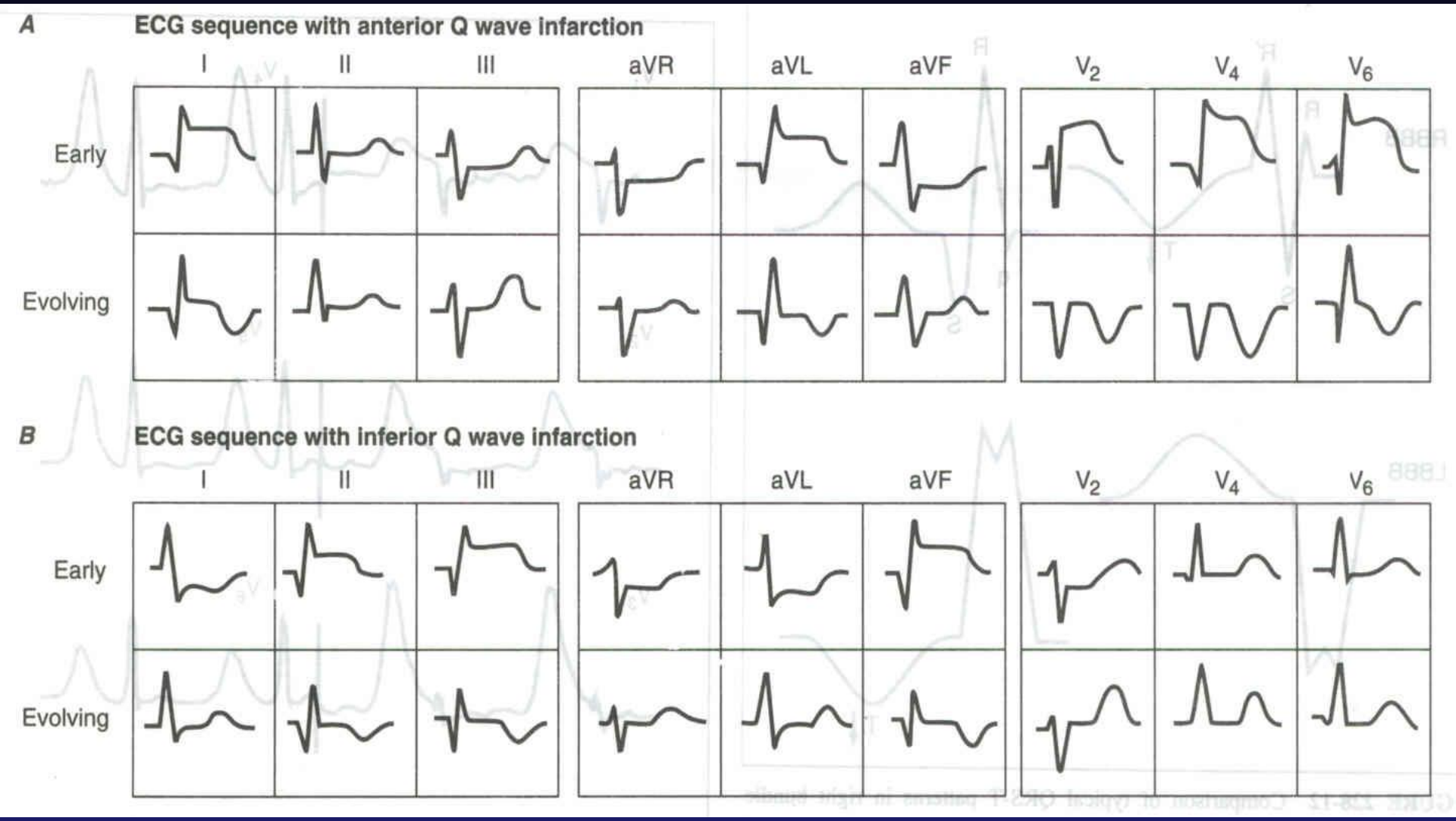

Non-ST Elevation MI

There are two distinct patterns of ECG change depending if the infarction is:

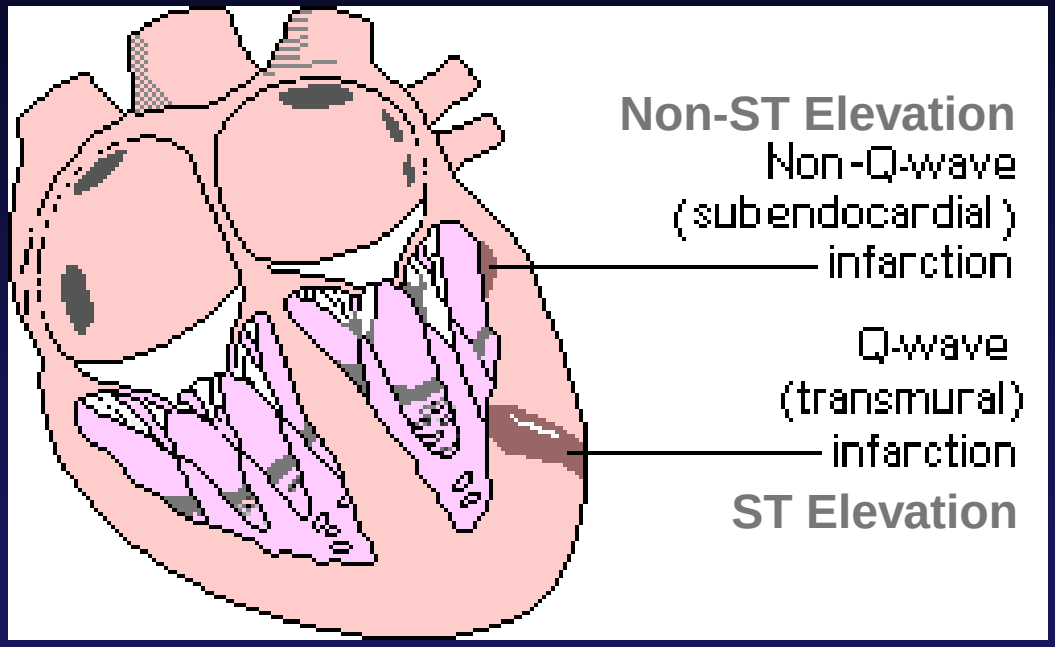

- ST Elevation (Transmural or Q-wave), or
- Non-ST Elevation (Subendocardial or non-Q-wave)

Sub-endocardial vs. Transmural Ischemia

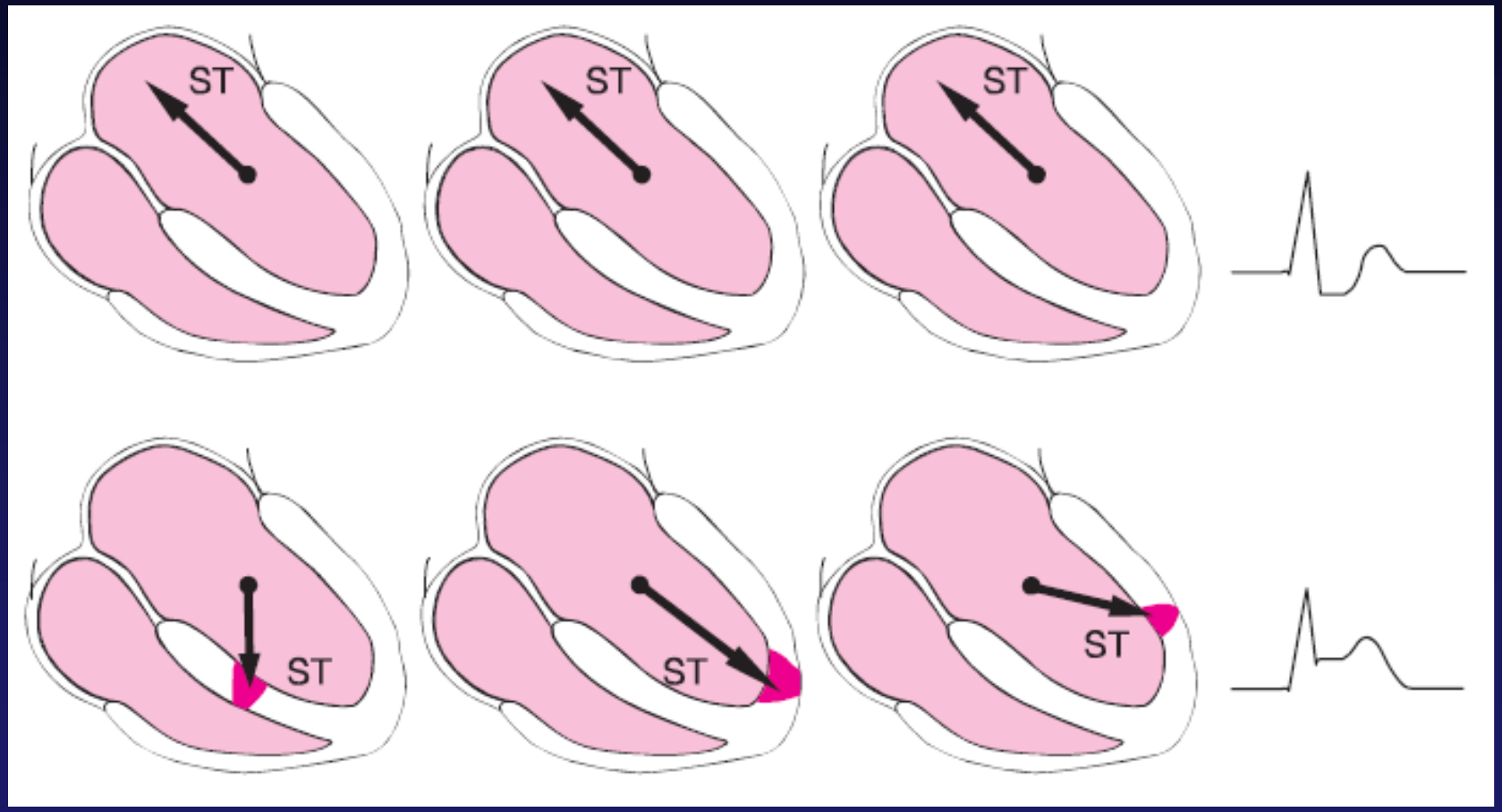

Tehran Arrhythmia Center

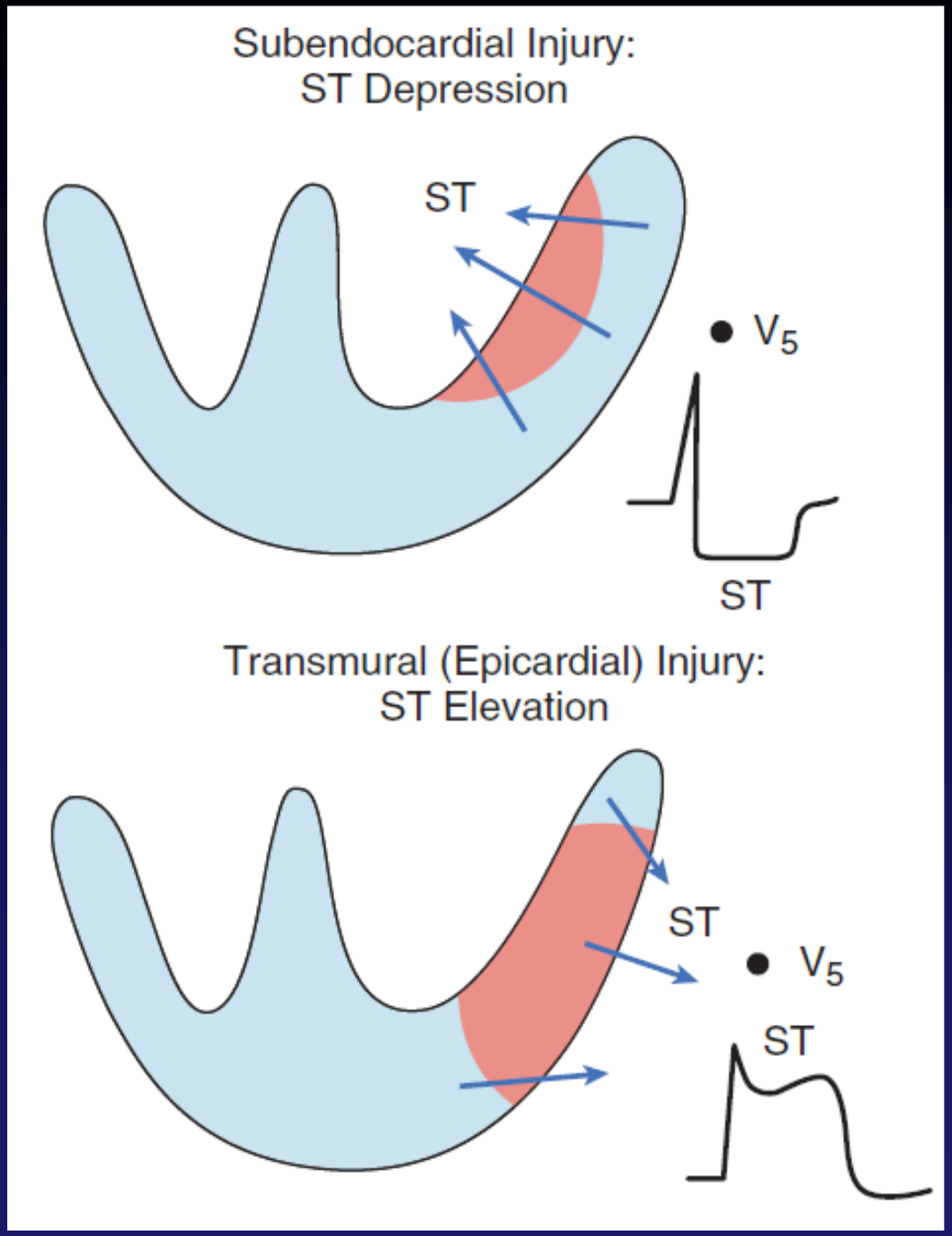

Sub-endocardial vs. Transmural Ischemia

Tehran Arrhythmia Center

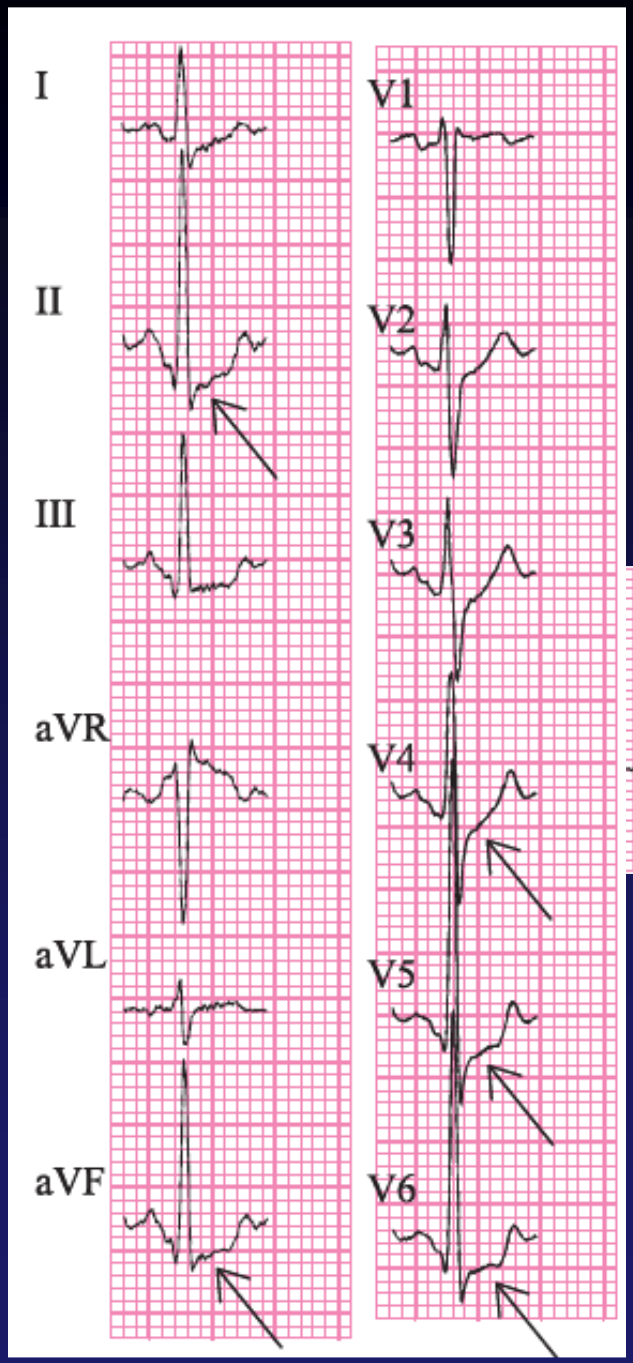

Sub-endocardial Ischemia

Tehran Arrhythmia Center

Non-ST Elevation Infarction

ECG of an evolving non-ST elevation MI:

Note the ST depression and T-wave inversion in leads V_2-V_6.

Question:
What area of the heart is infarcting?

Cannot say!

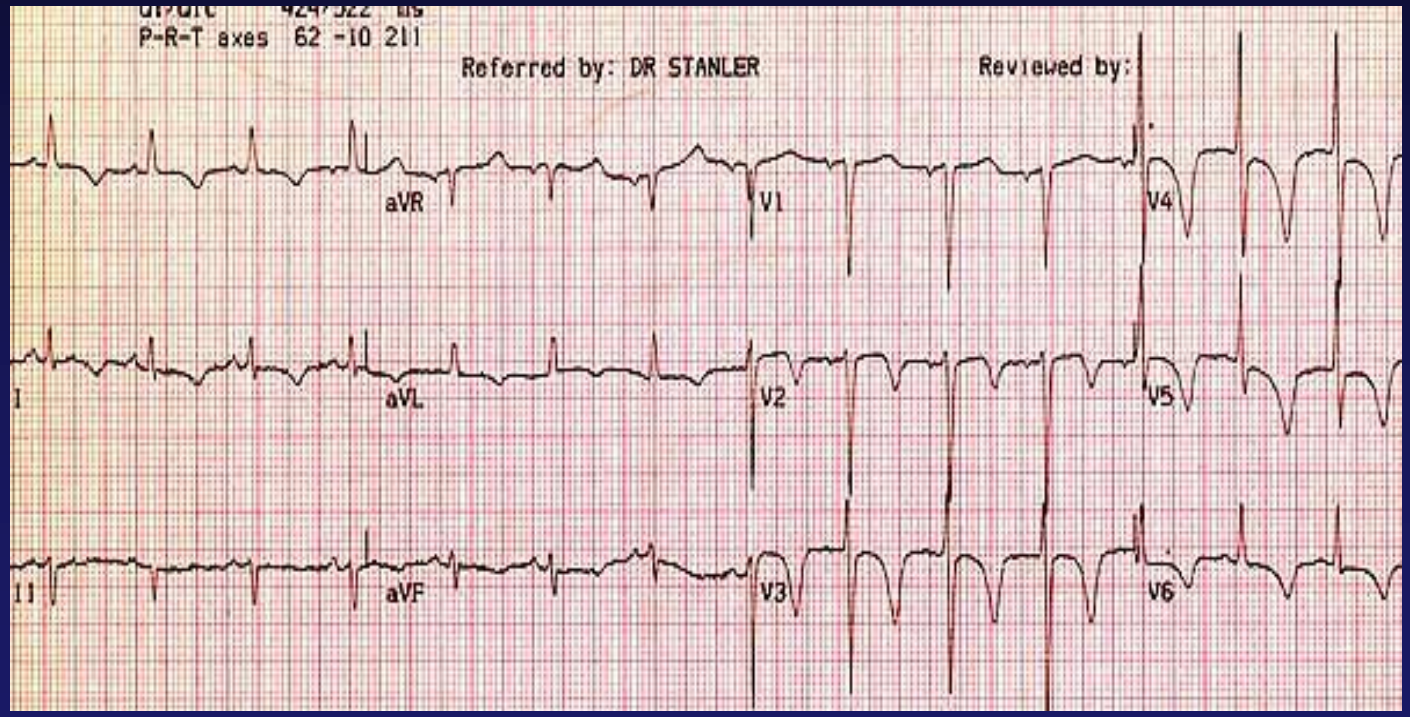

Acute Pericarditis

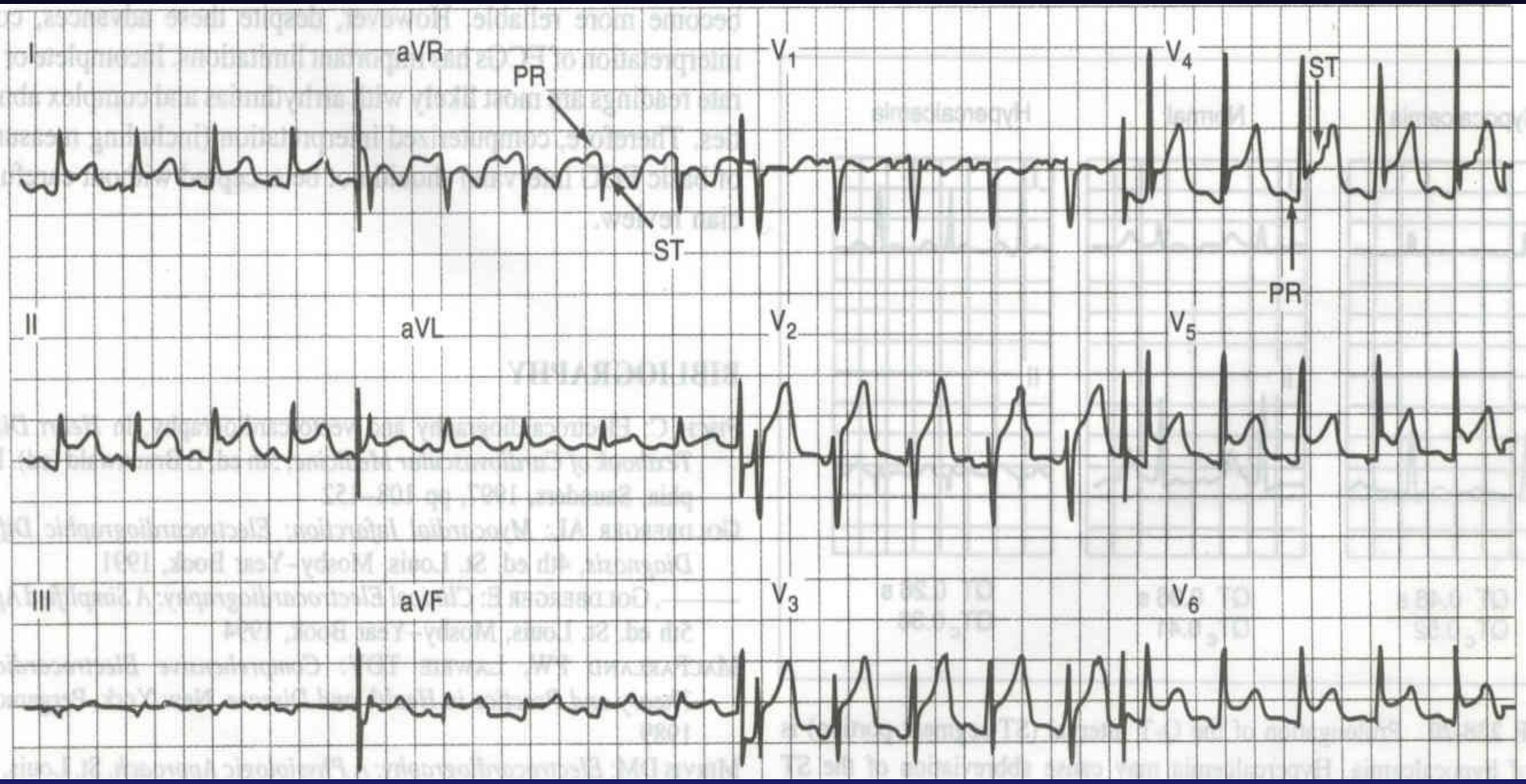

Tehran Arrhythmia Center

Metabolic Abnormalities

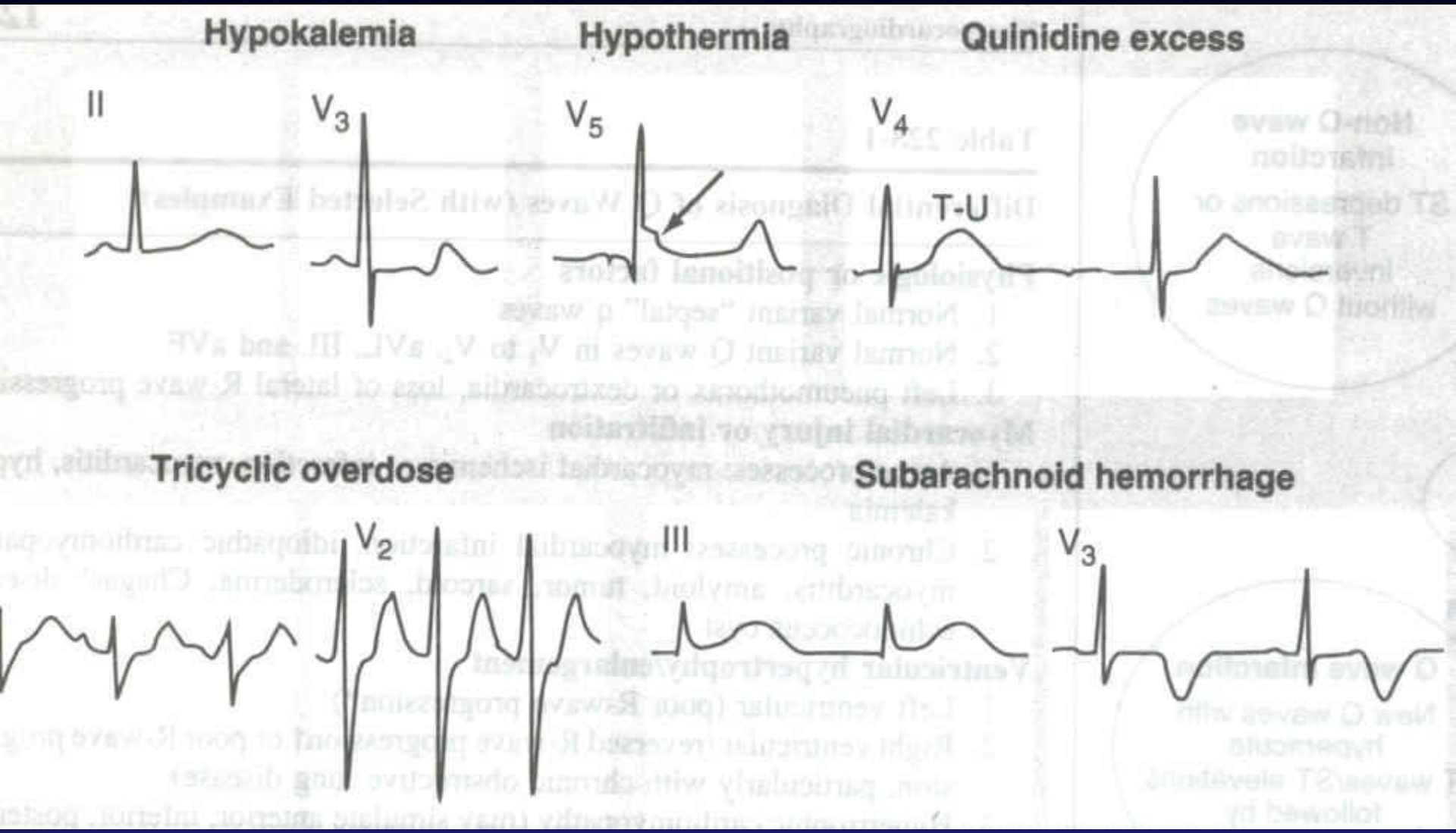

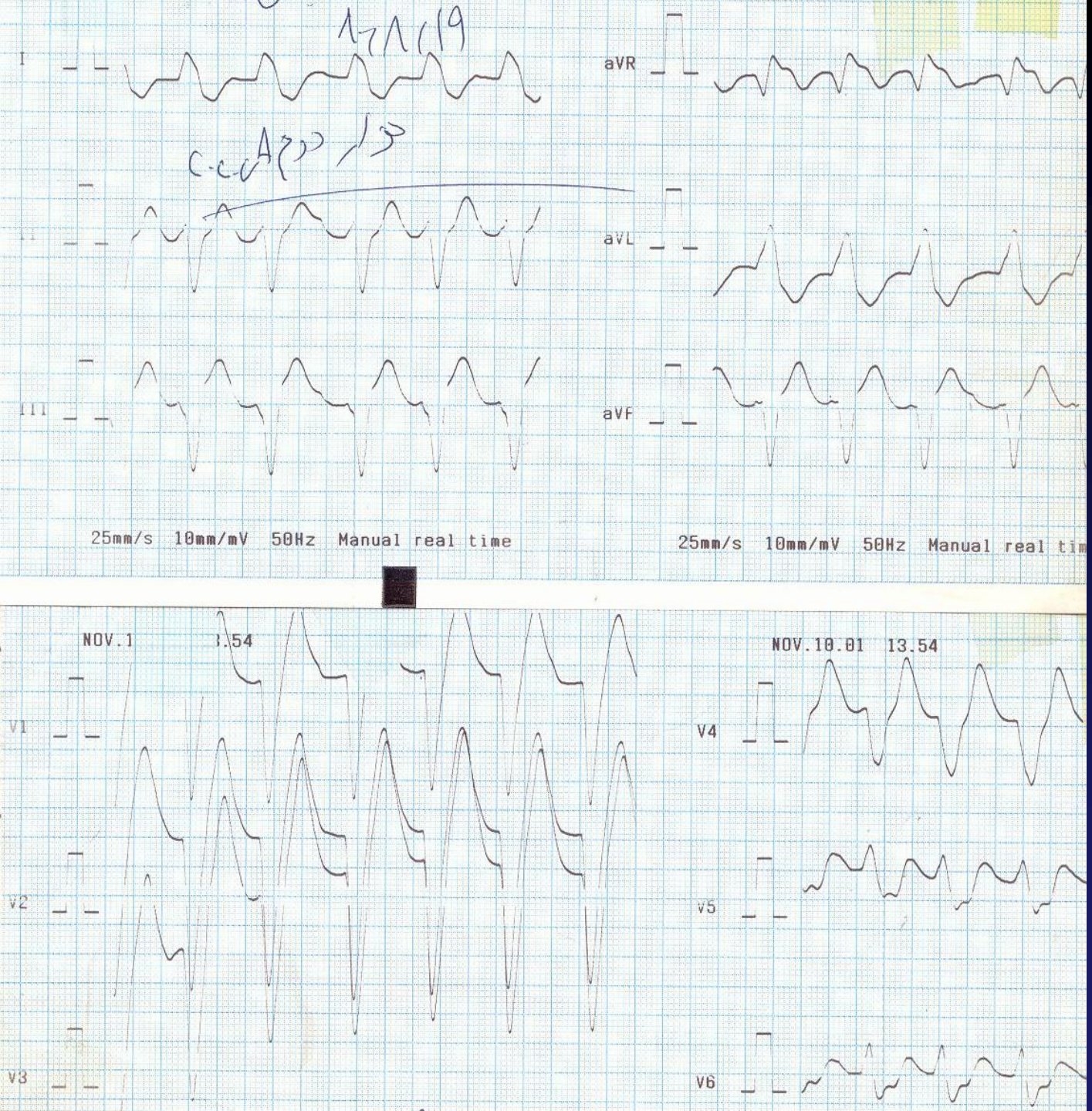

Hyper-kalemia K 6.9

Tehran Arrhythmia Center

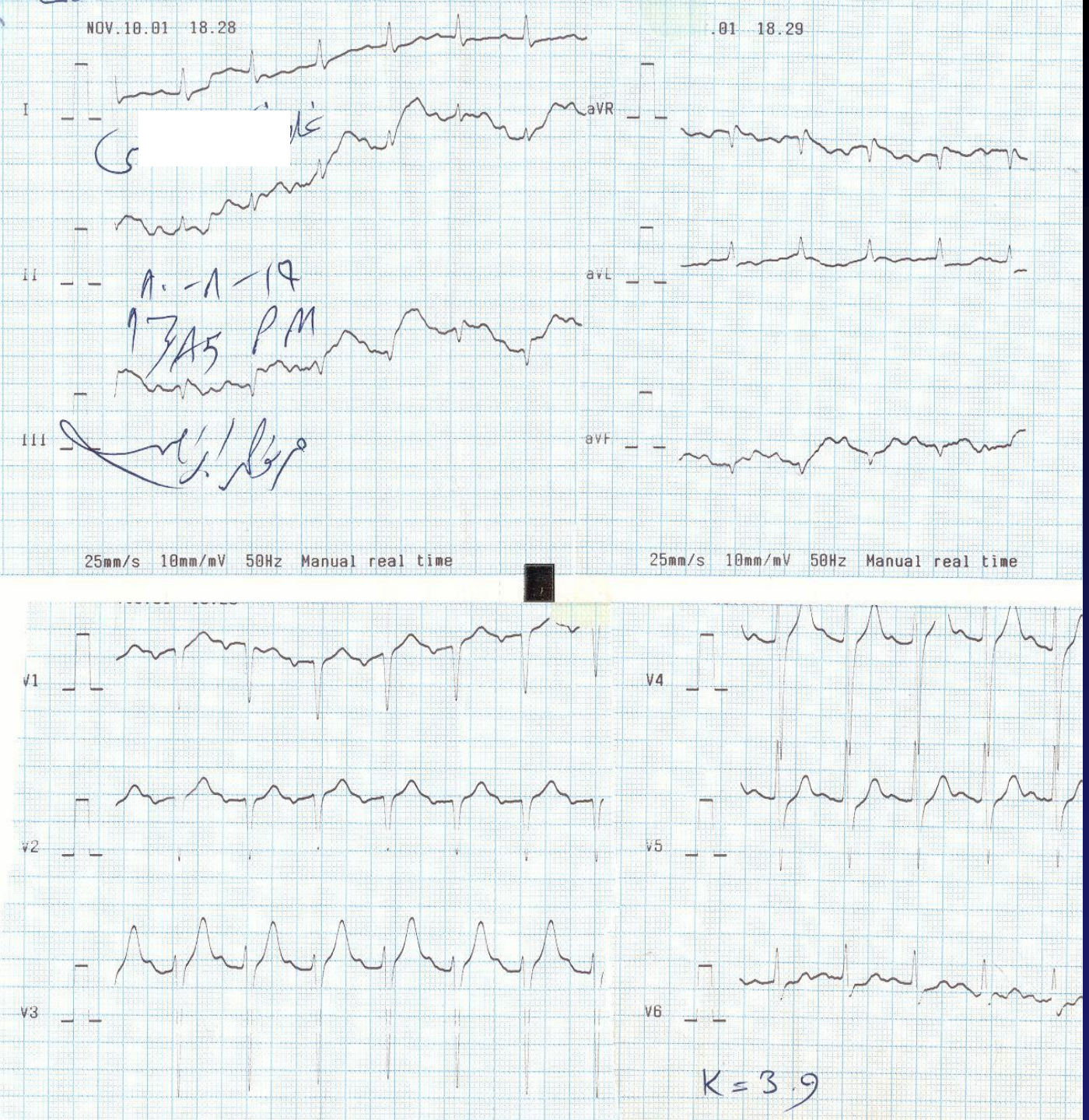

Same patient

K 3.9

Tehran Arrhythmia Center

Hypothermia, Osborn Wave

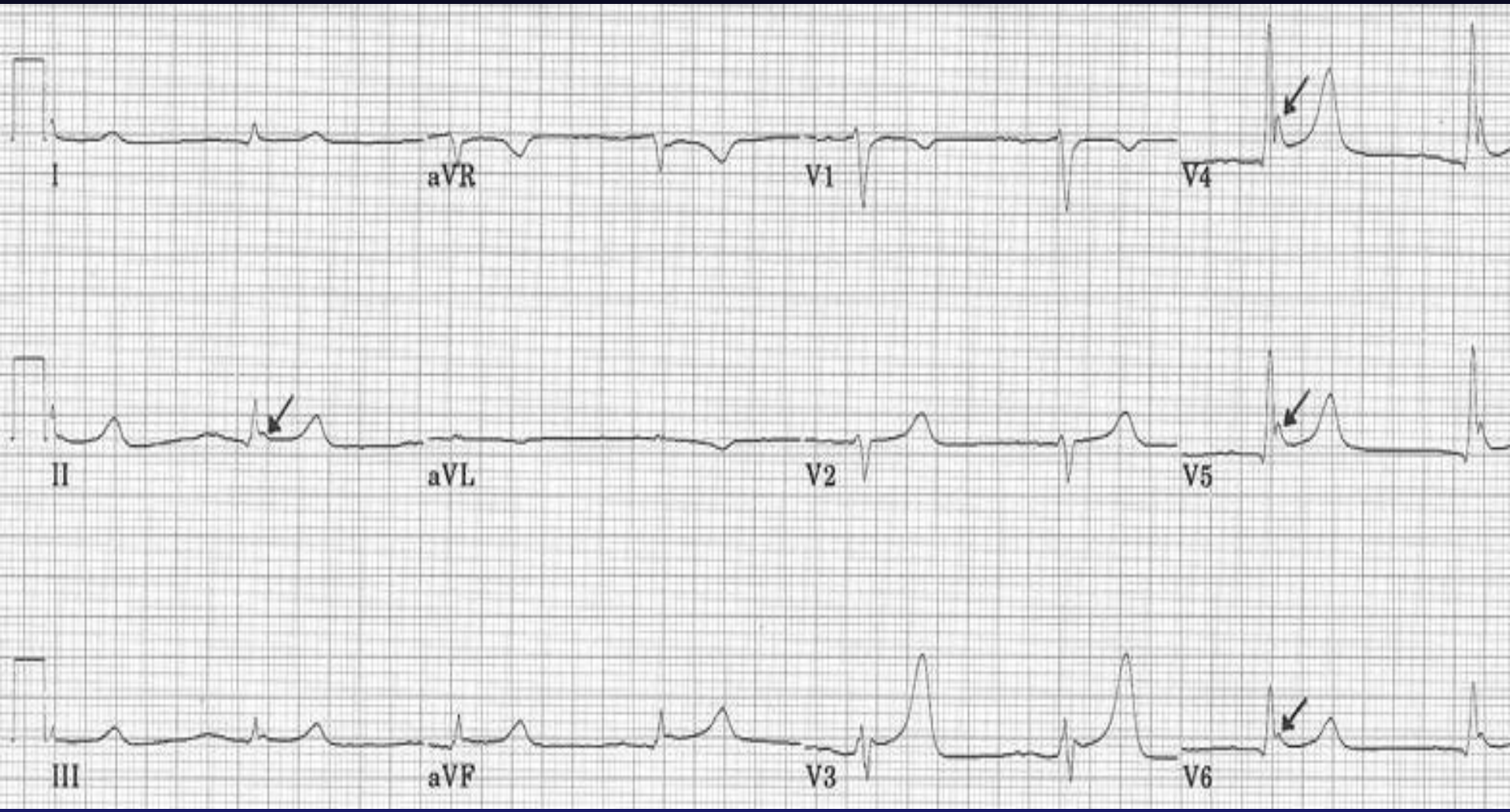

Hypothermia, Corrected

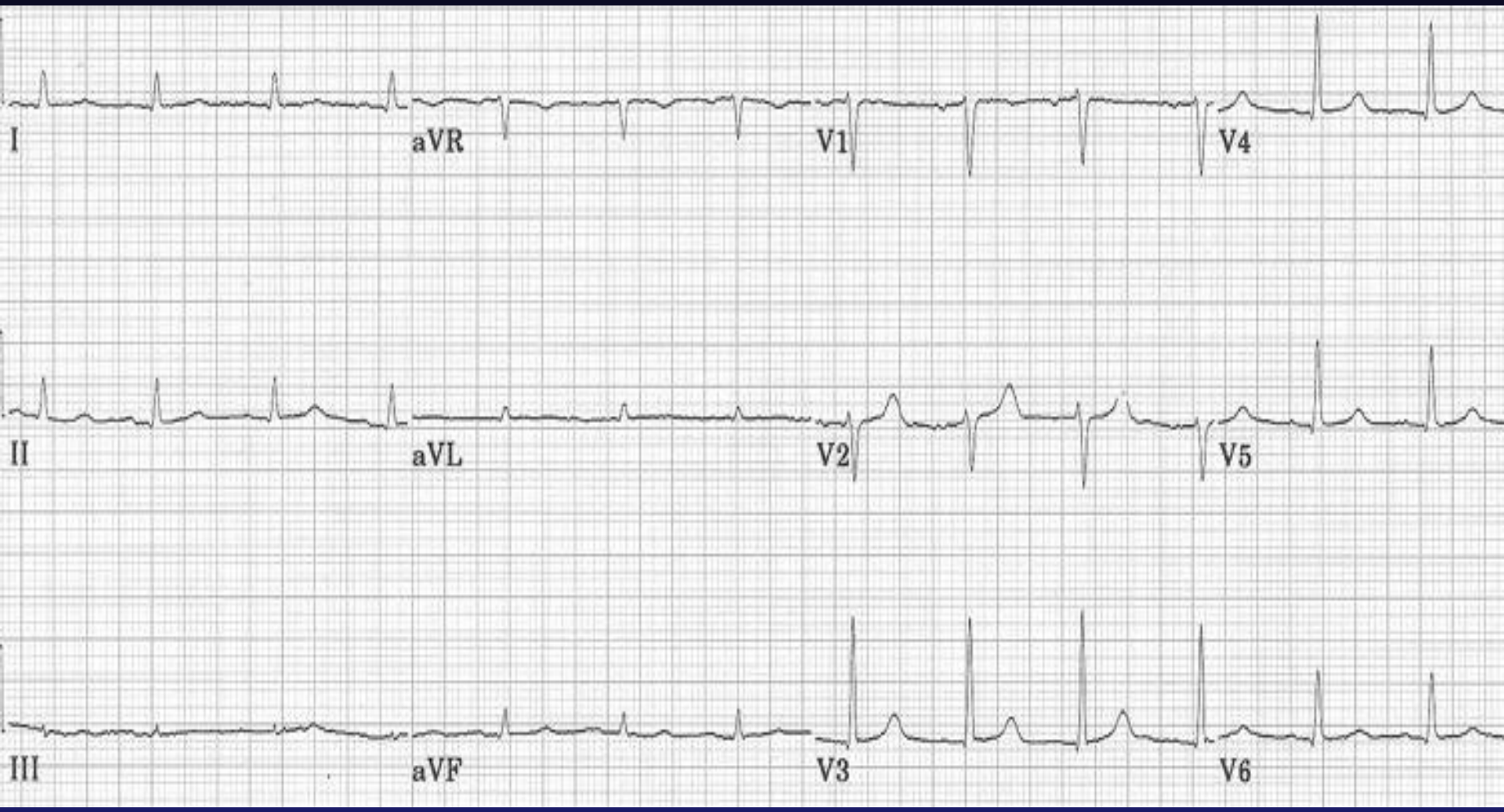


2003 5 29

Right Axis Deviation (Left Posterior Hemiblock)

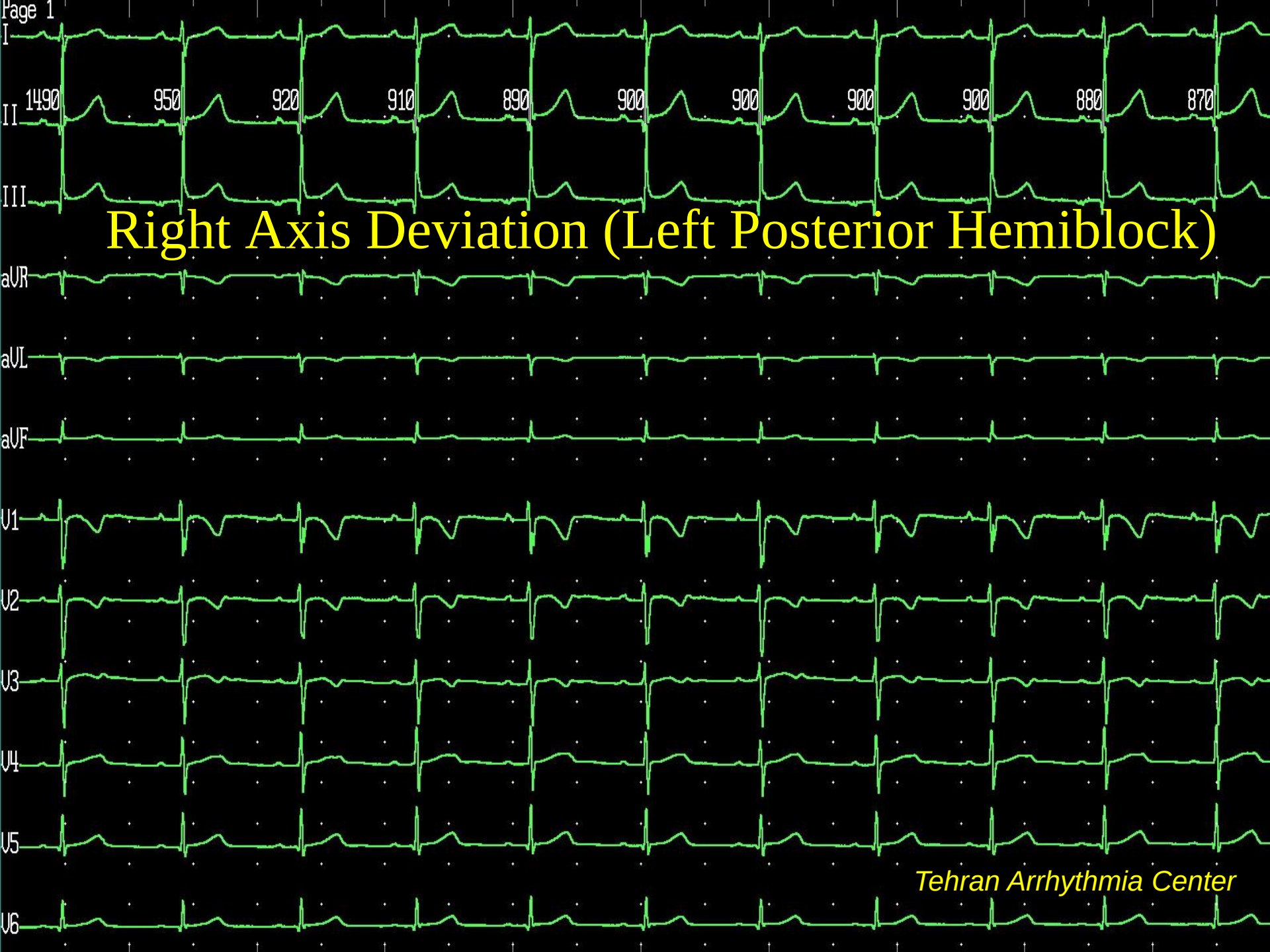

Tehran Arrhythmia Center

Anterior MI

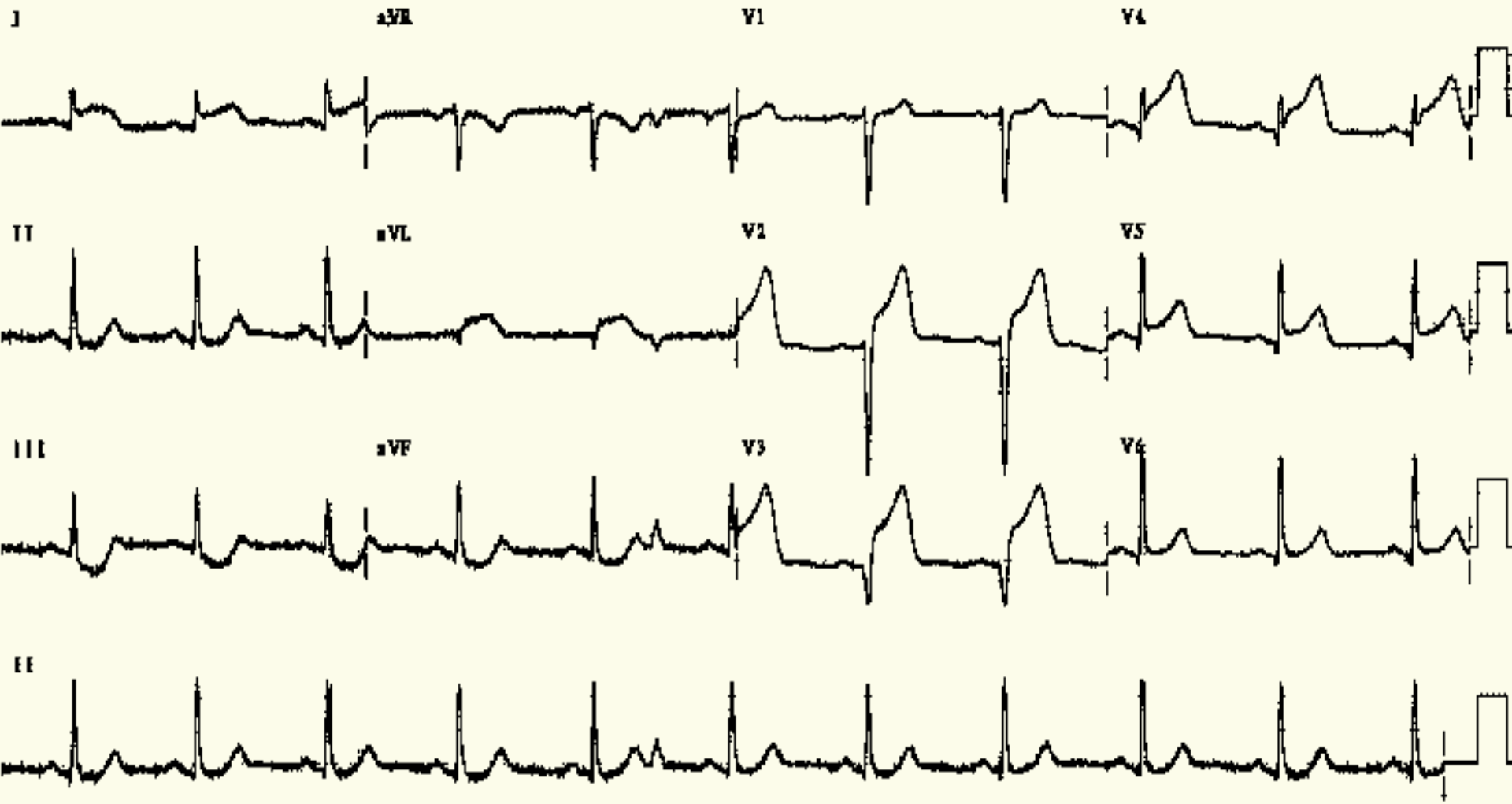

RBBB and Inferior MI

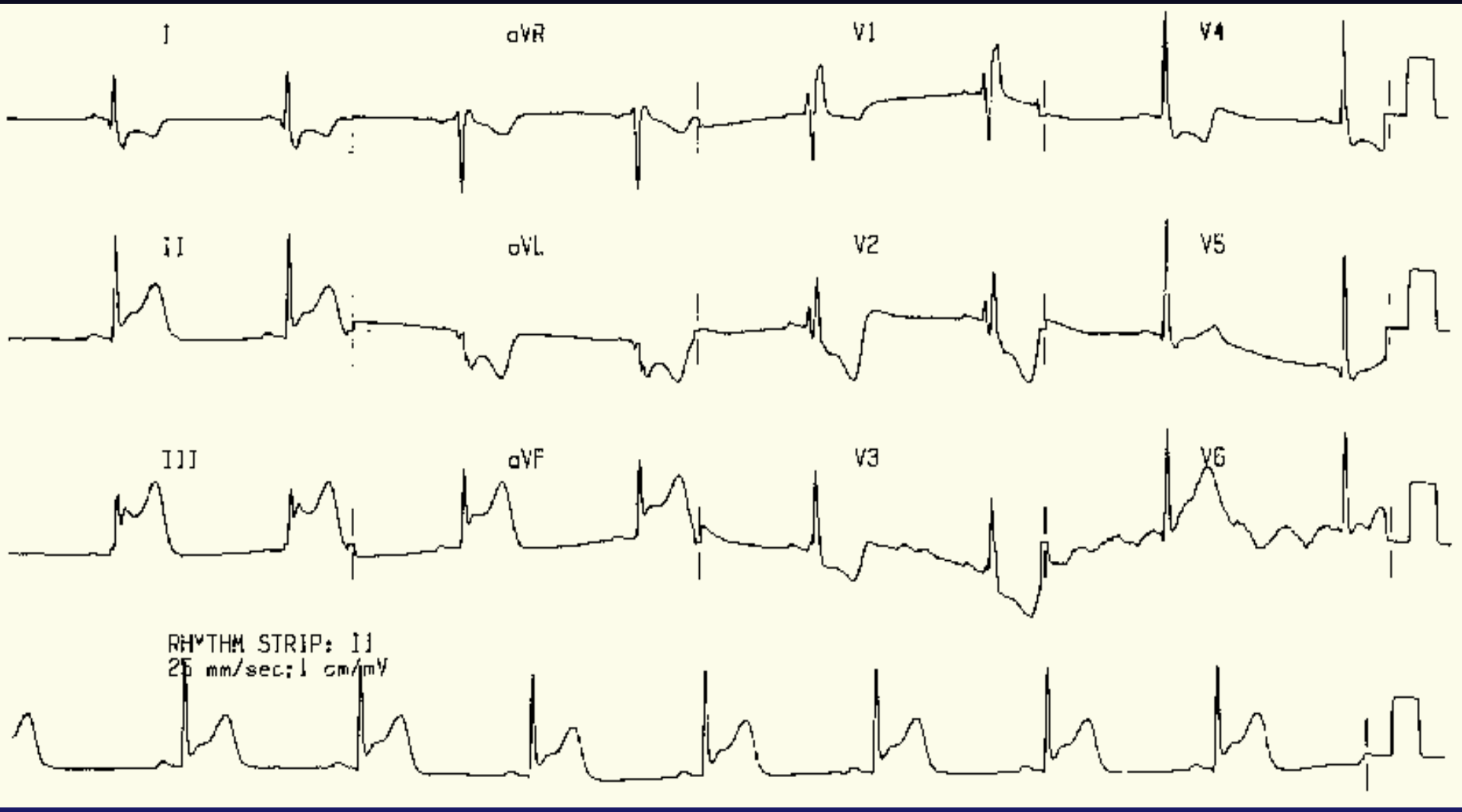

LA Enlargement and Prolonged PR Interval

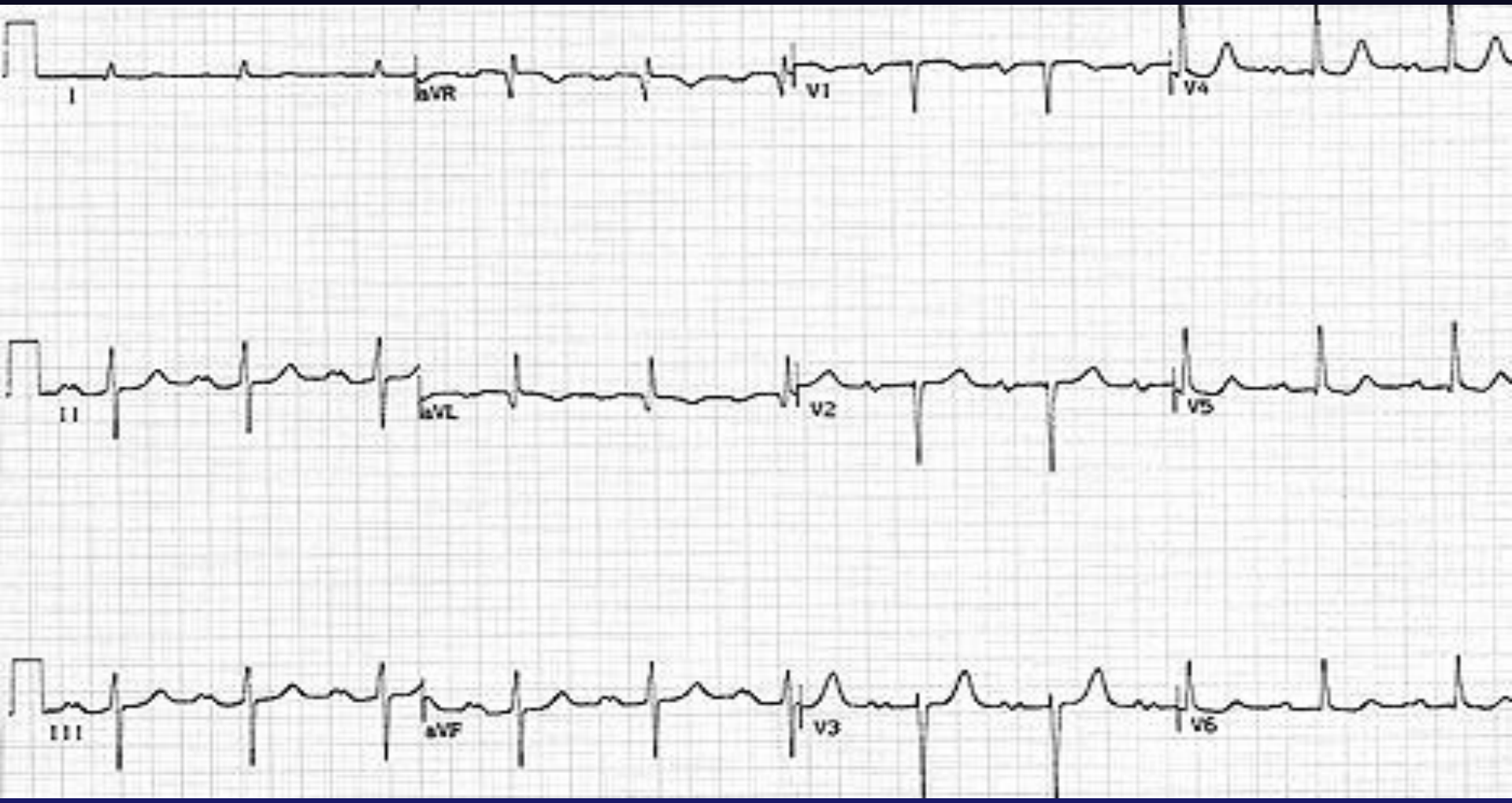

LBBB

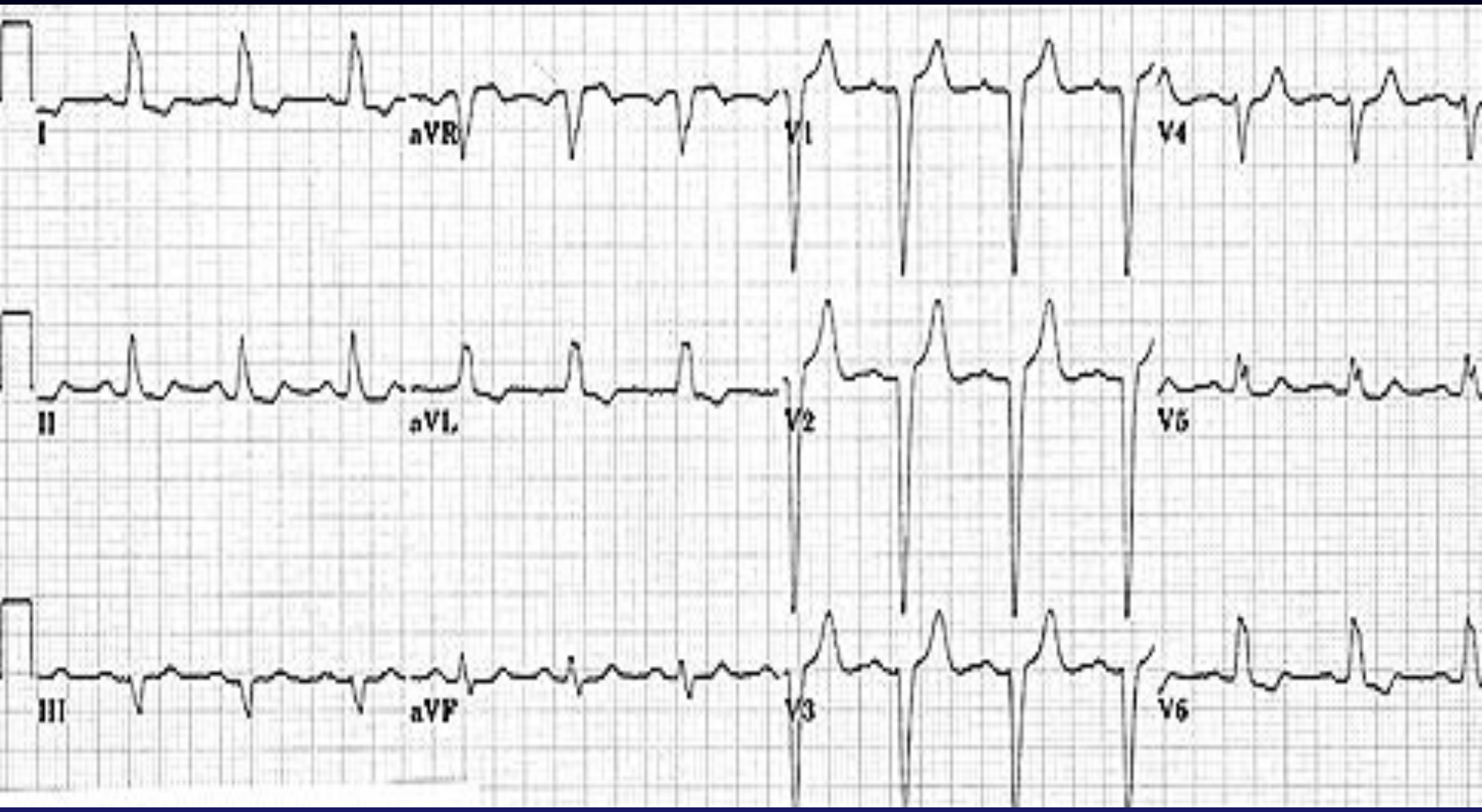

Acute Inferior MI

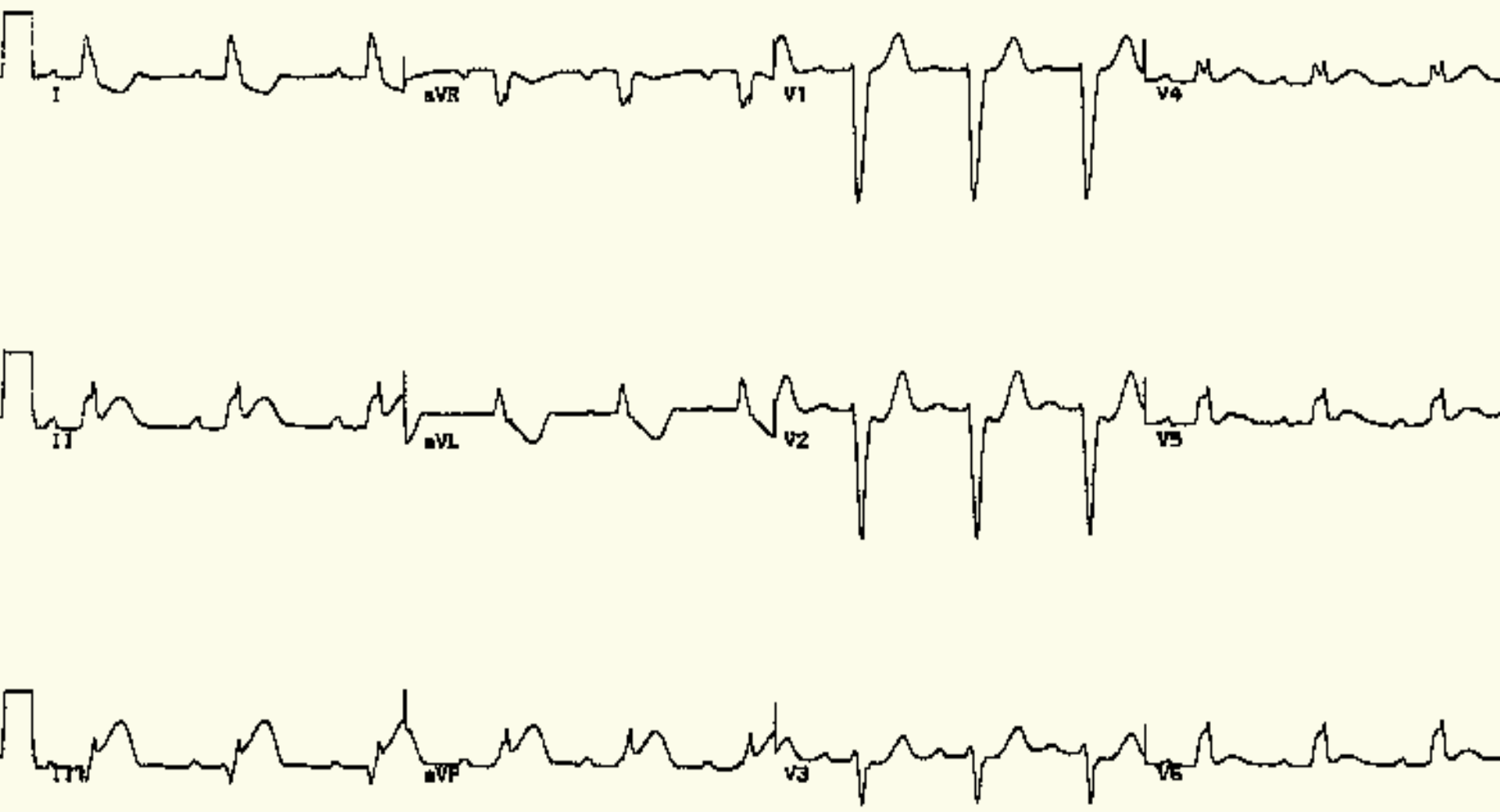

Left Anterior Hemiblock, Prolonged PR interval

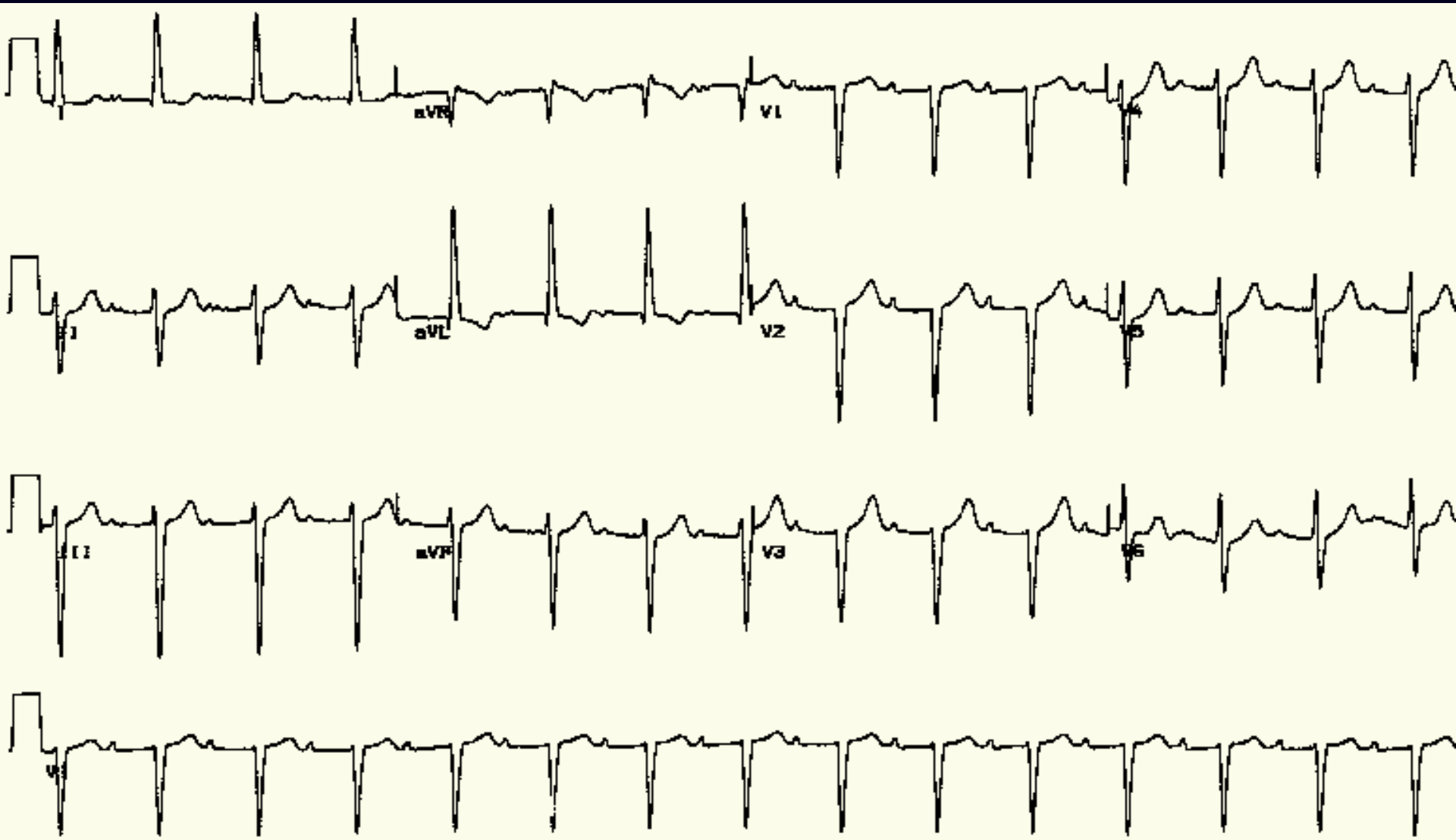

LVH and LA Enlargement

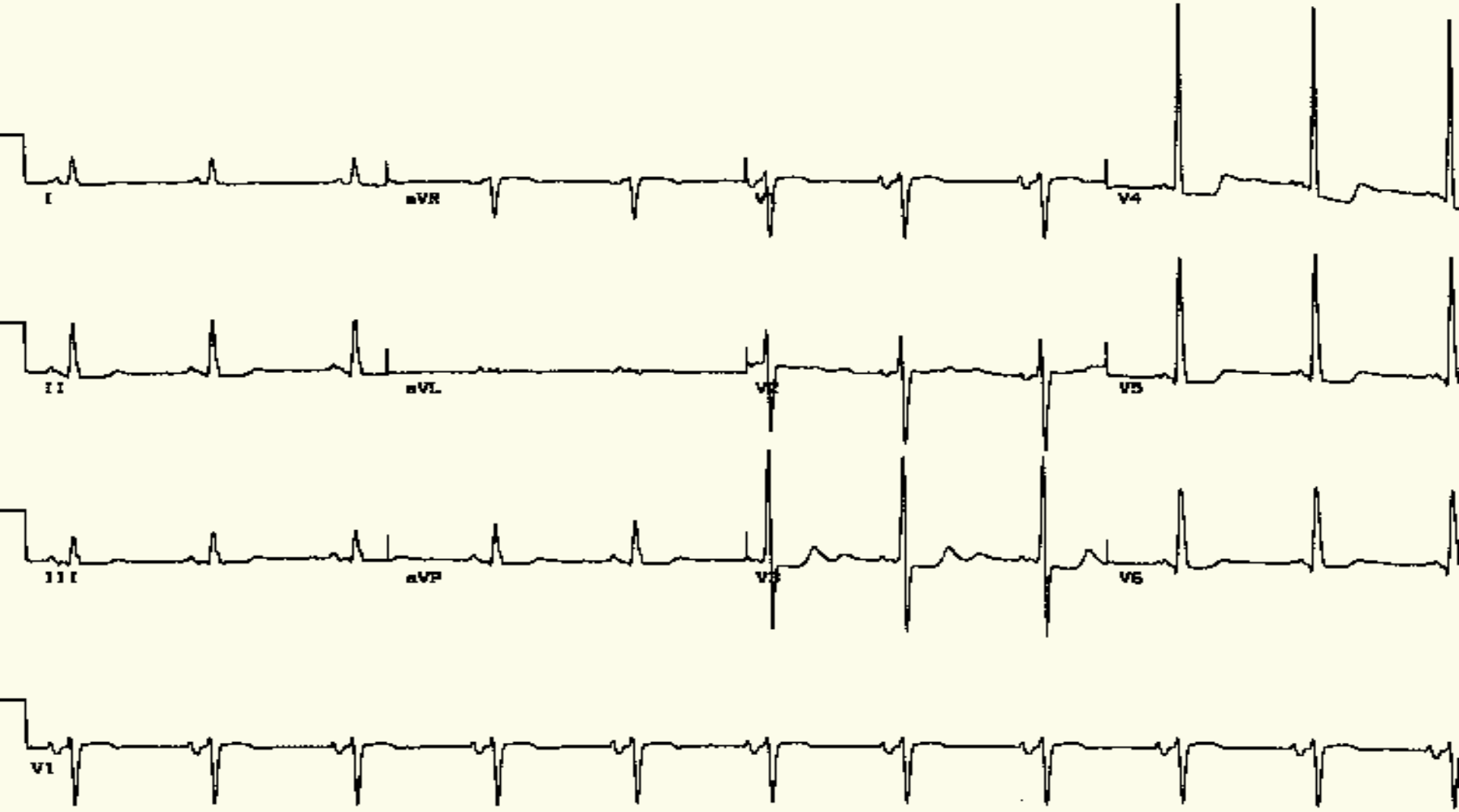

Anterior MI

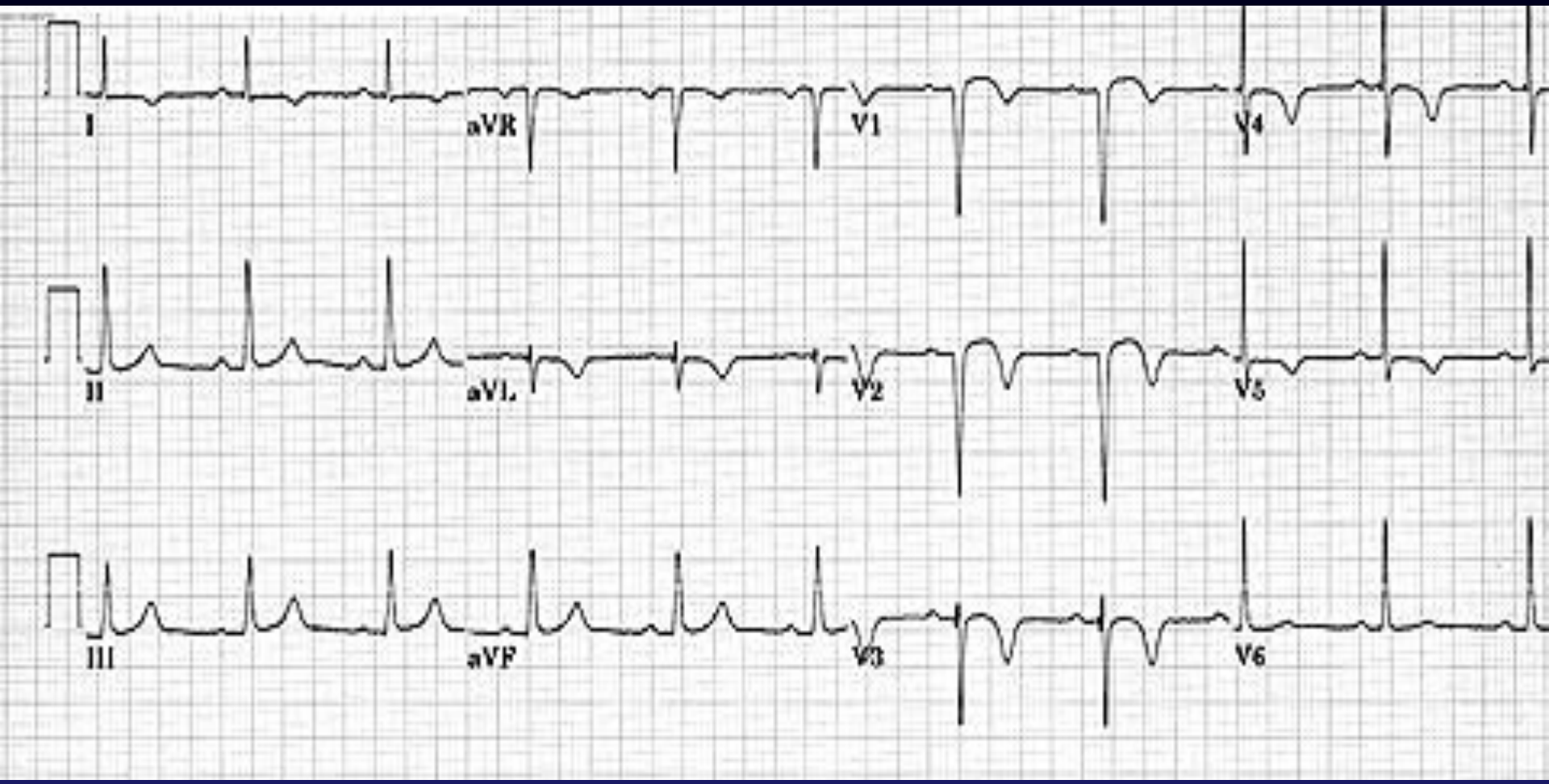

Tehran Arrhythmia Center

Old Inferior MI and Atrial Fibrillation

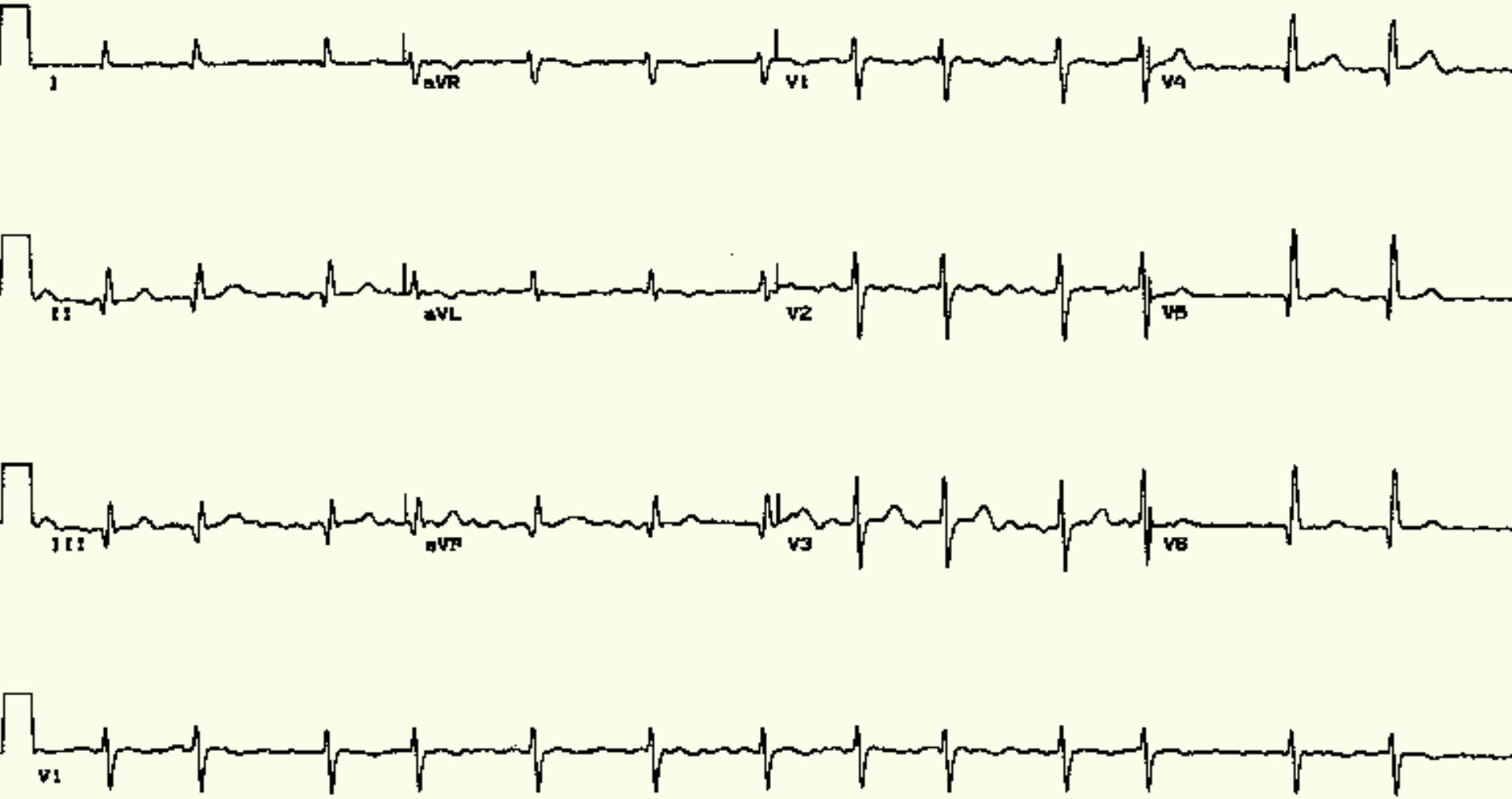

RA Enlargement

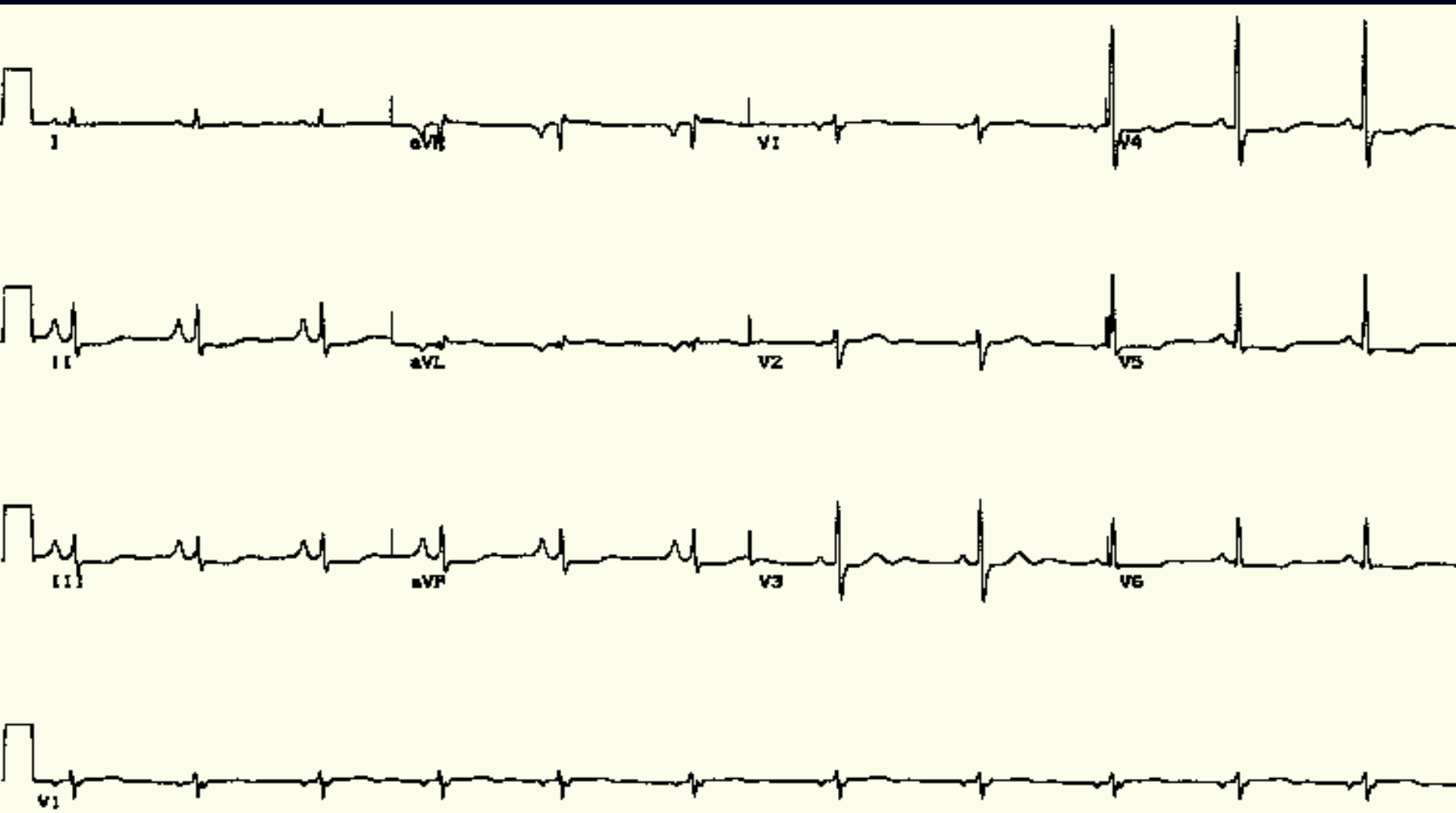

RBBB, LAH, Prolonged PR
(Trifascicular Block)

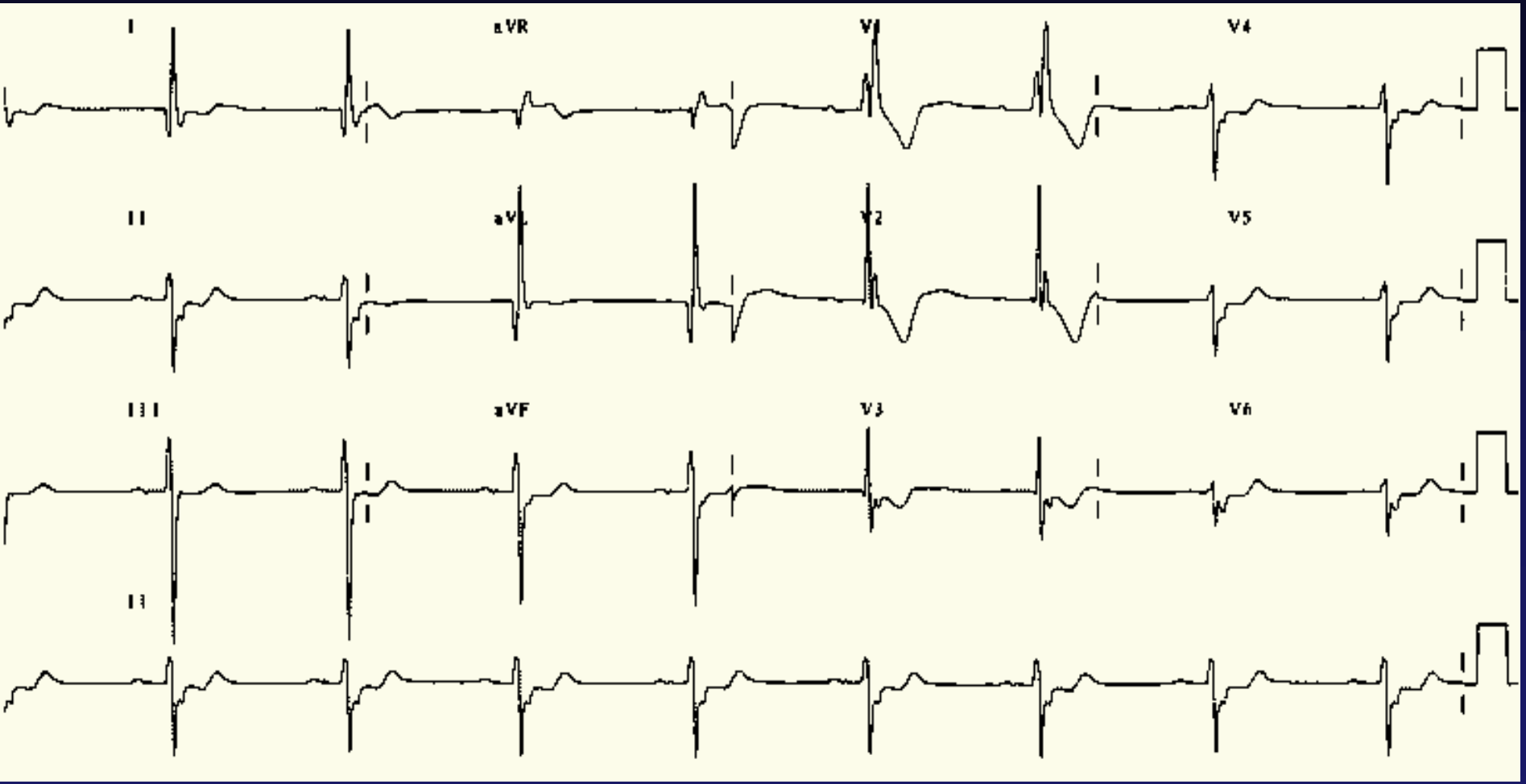

Tehran Arrhythmia Center


Tehran Arrhythmia Center
WWW.TehranEP.Center
info@TehranEP.Center
2005 6 25